

Short Communication

A case report of an imported cutaneous leishmaniasis in Côte d'Ivoire

N'da Angbeletchi David AKA¹, Gonat Serge Pacôme DOU¹, Kalou Dibert ZIKA², Fatoumata COULIBALY³, Mocket Adolphe. EHOUMAN⁴, Ibrahima KONE⁵ and Koffi Daho ADOUBRYN²

¹University Félix Houphouët-Boigny of Abidjan, 01 BP V34 Abidjan, Cocody. ²Université Alassane Ouattara, BP V18 Bouaké. ³Université Pelero Gon Coulibaly, BP 1328, Korhogo. ⁴Olopam Pharma and Research & Development, 10 B.P 1274 Abidjan. ⁵Groupe Médical et de Consulting BOZOUMA, 01 BP 6648 Abidjan. ⁶Université Alassane Ouattara, BP V18 Bouaké.

Abstract

Accepted 27 December, 2020

Cutaneous leishmaniasis (CL), parasitic and zoonotic disease, is very little known to health professionals in Côte d'Ivoire. It is caused by the bite of a female sandfly that harbors the genus of *Leishmania*. The species generally involved in Africa are: *Leishmania Infantum* Nicolle, 1908, *Leishmania major* Yakimoff & Schokhor, 1914, *Leishmania tropica* Wright, 1903 and *Leishmania aethiopica* Bray, Ashford & Bray, 1973. We report here a case of cutaneous leishmaniasis discovered incidentally, presenting involvement of the lower limbs. The patient, a woman, 41-year-old, a housewife, originated from Burkina Faso, who consulted in a private clinic in 2019 for pruriginous skin lesions under a chronic mode. After examination, the disease was diagnosed by positive direct smear, and slide preparations, after scoriations of the skin lesions were carried out and sent to Algeria's reference center for species determination. Treatment with Metronidazole 500 mg (1tab x3/day for four weeks) permitted to obtain clinical and biological cure without significant side effects. Practitioners should suspect Cutaneous leishmaniasis in case of chronic wounds in endemic zones. The strengthening of human resources, the improvement of our regional laboratories' technical platform, the integration of the screening and management of leishmaniasis to the program against Buruli ulcer are urgently needed.

Keywords: Leishmaniasis, Cutaneous leishmaniasis, Leishmania, Côte d'Ivoire, Africa, Phlebotomus, Sandyfly, Neglected Tropical Diseases.

INTRODUCTION

Leishmaniasis is a parasitic disease discovered by William Leishman in 1900 in the spleen smears of a soldier who died of fever in Dum-Dum, India (Dietmar, 2017). This tropical disease is due to genus *Leishmania*. *Leishmania spp* and *Trypanosoma spp* belong to the family Trypanosomatidae (Bruckner *et al.*, 1999).

Leishmaniasis is one of the most important neglected tropical diseases (NTDs) due to the scant attention it receives from health policies at the international level, the limited resources allocated to the prevention and treatment of people living in endemic areas with this zoonosis. Indeed, most of the time, people and communities living in poor conditions, without proper water and sanitation and close to disease-carrying insects and animals are most vulnerable to NTDs (Louise *et al.*, 2019; Hepburn, 2003). Worldwide, 350 million

people are assessed for this condition in 88 countries while 12 million affected by Leishmaniasis daily (Sara *et al.*, 2015). In Africa, most of cases are distributed in mediterranean rim countries namely the Maghreb countries (Algeria, Morocco, Tunisia) and in Egypt while sporadic cases are described in Sub-Saharan Africa. The complexity of transmission of the disease is due to complex life cycle of the parasite which involves sand fly vectors and mammalian reservoirs. It can either be zoonotic and/or anthroponotic through the bite of an infected female sand fly (Alemayehu *et al.*, 2017). Some leishmania species infecting human are zoonotic, having a complex variation in domestic and wild mammal reservoir hosts; while, other species of the parasite are anthroponotic, having human-to-human transmission in the presence of the vector (Alvar *et al.*, 2012). Unlike Visceral leishmaniasis (VL), in which leishmania invade organs such as the liver, spleen, lungs and many other organs, Cutaneous leishmaniasis (CL) present localized leishmania in the skin.

We report here a case of an imported cutaneous leishmaniasis discovered fortuitously in a patient.

RESULTS

This is a consent 41-year- old female, married, mother of 5 children, and housewife originally from Burkina Faso. Resident of Bobodioulasso, she presented in 2004 a cutaneous rash "bouton" in the lower part of the antero-external face of the left leg with leaked sero-hematic fluid. A few weeks later, a sharp sore began to gain momentum in size and appearance. Indeed, from the size of the head of a pin, this wound gradually evolved in size to become like a coin. This wound was painful and the intensity was exacerbated after trauma. Besides, several other places of the two lower limbs experienced more or less the same events of cutaneous lesions. This patient visited several health facilities in the locality where she resided. She received various types of medications ranging from antibiotics to anti-inflammatory drugs and anti-fungal drugs. To face with the unsuccessful nature of the treatments, she then turned to a traditional healer who predicted that she was bewitched by a person closed to her family. She was then treated with some traditional medicines made of decoction which unfortunately did also not cure her illness.

Facing the disease's recrudescence and its economic and social repercussions on their household, this patient was subsequently divorced and had to change residence (Ouagadougou) in 2018 without her children. Three months ago, on her parents' advice pretesting a better quality of care in Côte d'Ivoire, she traveled to Abidjan where she was followed up in the Dermatology Department of the University Teaching Hospital (CHU) of Treichville this year. In her care, the patient carried out

medical consultations and check-ups, as shown in Table 1. Haematologically, the patient is of the AB Positive blood group. However, normochromic microcytic anemia as well as sickle cell anemia were detected from blood smear. Leukocytes were normal, unlike high platelets. Also, an increase in the marker of inflammation was observed. Biochemically, apart from hyperuricemia, all other performed tests viz. lipid, liver, kidney, electrolyte and carbohydrate were normal. With regard to the explorations, the ECG noted some anomalies (wave repolarization disorder and negative wave T). However, the chest x-ray and the cardiac echo-Doppler of the arteries of the lower limbs returned to normal. Following the host family's doctor advice, the patient consulted on October, 2019, at the GMC-Bozouma Medical clinic for dyspnea, palpitations and conjunctiva's pallor and severe asthenia, intending to receive a blood transfusion.

The clinical examination revealed the following information: General examination -Good general condition, normal consciousness, conjunctivae slightly colored, saburral tongue. Temperature - 98.6 F, Pulse: 101 bpm, Weight: 60 kg, Height: 1.62 m, BMI: 23.62. Cardiovascular system -regular tachycardia without any added murmur. The various arterial pulses were perceived. Pleuro-pulmonary system - at auscultation the chests were clear, good air bilateral. Digestive system - the abdomen was soft, not tender and without hepatosplenomegaly. Other systems -No lymphadenopathy of the lymph nodes. However, there was a presence of some skin spots suggestive of post-kala azar lesions on the right lower limb. Also, there were two ulcers of 4 cm and 2 cm of the antero-external and antero-internal face of the lower left leg associated with necrosis of the second left metatarsal, as shown in Figure 1. There was an induration of the ulcer's edges and a crater made up of hematic areas and pus.

In the presence of this clinical picture suggestive of cutaneous leishmaniasis, the patient underwent a series of examinations including a blood smear and a smear of the exudations after scoriations of the lesions. After that, the slides were stained with the May Grünwald Giemsa method and read, which made it possible to highlight suspicious forms of 'amastigotes' suggestive of *Leishmania* spp. The prepared slides were sent the following day to the Parasitology-Mycology Laboratory of the Medical teaching school in Abidjan, where the diagnosis of cutaneous leishmaniasis was confirmed after identifying extracellular amastigote ovoid forms with 2-5 μ in diameter and kinetoplast as shown in Figure 2. Other samples were also prepared and packaged with the patient's agreement and sent to the Institute Pasteur of Alger (Algeria) for biomolecular and genotypic analyzes to identify the responsible species.

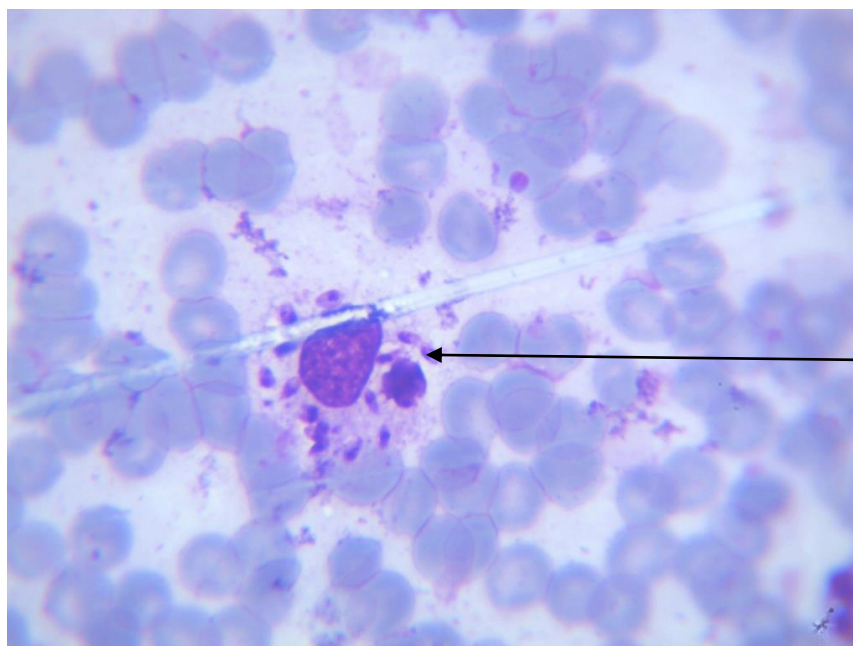
Concerning the treatments, the patient received a transfusion of 500 mL of isogroup-isoRhesus blood with

Table 1. Biological analysis and functional exploration.

Nature of analysis	Assessment on arrival in Côte d'Ivoire		Assessment on admission to the private clinic	
Hematology	Date	Results	Date	Results
	08/27/2019	<ul style="list-style-type: none"> hemogram : <ul style="list-style-type: none"> - Anemia Hb : 7,9 g/d ; VGM 78,7 fl ; CCMH : 34,9 g/100ml ; TCMH : 27,5 pg - Normocytosis : GB : $8 \times 10^3 / \text{mm}^3$ - Hyper platelet : 551 000/mm³ 	12/10/2019	<ul style="list-style-type: none"> hemogram : <ul style="list-style-type: none"> - Anemia Hb : 7,9g/d ; VGM 72,4 fl ; CCMH : 31,8 g/l ; TCMH : 26,2 pg - Hyperleukocytosis : WB : $10,3 \times 10^3 / \text{mm}^3$ - Platelet : 417 000/mm³
	09/02/2019	<ul style="list-style-type: none"> Rate of reticulocytes : 13% ($373100 / \text{mm}^3$) 		
	08/08/2019	<ul style="list-style-type: none"> Blood Group and Rhesus status : AB Positive 		
09/06/2019	<ul style="list-style-type: none"> Electrophoresis of hemoglobin: SC (HbS : 49,97% ; Hb C : 50,03%) 			
Parasitology	10/12/2019			<ul style="list-style-type: none"> Thick Blood smear: positive with 160 trophozoites/mm³ Smear : Presence of forms of amastigotes of Leishmanias
Biochemistry	08/28/2019	<ul style="list-style-type: none"> Glycemia : 1,02 g/l CRP : 39 mg/l Uric Acid : 65 mg/l Cholesterol Total : 1,40 g/l HDL : 0,37 g/l LDL : 0,88 g/l Triglycerides : 1,25 g/l GOT /AST : 9 UII, GPT/ALT : 6 UI/l Urea : 0,22 g/l Craatinin : 7,4 mg/l K⁺ : 4,3 mmol/l Na- : 141 mmol/l Cl- : 101 mmol/l HbA1C : 4% 		<ul style="list-style-type: none"> Glycemia : 1,27 g/l CRP : 96 mg/l
Cardiology	08/28/2019	<ul style="list-style-type: none"> ECG : Sinus tachycardia, a diffuse flat or negative T wave repolarization disorder 		
Radiology	08/27/2019	<ul style="list-style-type: none"> Chest X-ray : Normal 		
Echo-Doppler	09/06/2019	<ul style="list-style-type: none"> Cardiacecho-Doppler: Normal 		
	09/12/2019	<ul style="list-style-type: none"> Echo-Doppler of the lower limbs: Normal 		

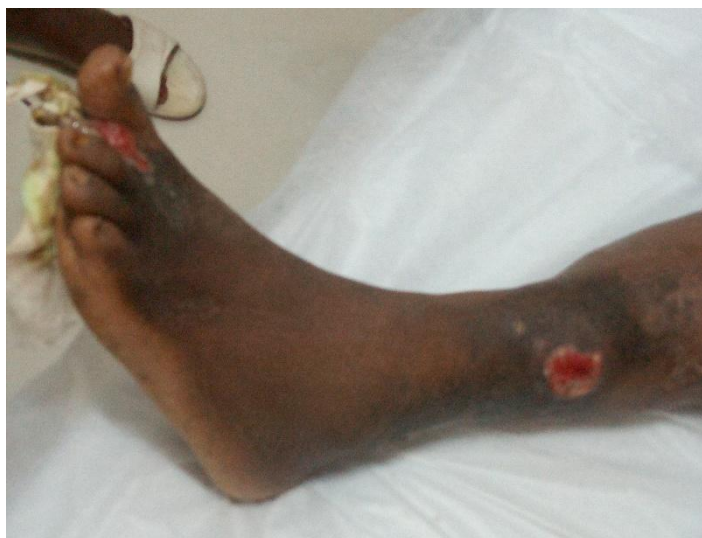

Figure 1. Two ulcers on the left foot and lower leg.



Amastigote form with nucleus and kinetoplast of *Leishmania* sp. (3µm)

Figure 2. A blood smear of *Leishmania* sp. (MGGx1000).

success. In addition, an antimalarial drug (Artemether/Lumefantrin 80/480 mg: 1 tab x2/day for 3 days), an antibiotic coverage (Oxacillin 500 mg: 2 tab x2/day for 2 weeks) to prevent bacteriologic issue and an anti-anemic treatment (Iron fumarate/Acid folic/ vitamin C of 308/4/200 mg (1 tab/day for 3 months) were prescribed. That treatment pending the initiation of the

specific treatment in collaboration with the physicians of the infectious and tropical disease services (maladies infectieuses et tropicales (SMIT)) of the University Teaching Hospital (CHU) of Treichville in Abidjan, because of the unpredicted nature of the serious side effects for the therapy with the antimonial drug. Finally, after discussion a prescription of Metronidazole 500 mg (1 tab x3/day for four weeks was added to the treatment.

Concerning the evolution, the disease's course was marked by a reduction in the size of the wounds followed finally by scarring. However, amputation of the second toe was performed due to the necrosis issue.

DISCUSSION

Leishmaniasis is a zoonosis in three clinical forms in humans: Cutaneous leishmaniasis, Muco-cutaneous leishmaniasis and Visceral leishmaniasis (Marty, 2005). It ranks second among the parasitic diseases in terms of annual mortality after Malaria. Cutaneous leishmaniasis is a parasitic disease caused by the flagellated protistes or *Leishmania* spp., transmitted by an insect named sandfly (Gentilini, 2012). This disease is characterized essentially by the skin damage without spreading to the deep organs or to the mucous membranes (Anofel, 2016). In Africa, the species frequently encountered are *L. Infantum* Nicolle, 1908 around the Mediterranean basin, *L. Major* Yakimoff & Schokhor, 1914 in the Sahelo-Sahelian zone, and *L. Tropica* Wright, 1903/*L. aethiopica* Bray, Ashford & Bray, 1973 in the eastern and southern parts of the continent. The lesions which result from the bite of the sandflies are observed mainly on the naked parts of the body (Richard, 2009).

The country of our patient testifies of her endemic origin. Indeed, Burkina-Faso has been a subject for numerous studies and researches on leishmaniasis and its intermediate hosts. The first case of cutaneous leishmaniasis was reported in 1962 with the discovery of 13 cases originating overwhelmingly from northern Burkina Faso, formerly known as Haute Volta. In this study, *Phlebotomusduboscqi* Neveu-Lemair, 1906 (Diptera: Phlebotominae) was implicated (Oddou, 1962). Twenty-five years later, 20 more cases have been reported in patients with clinical relevant from the North of the country (Menard *et al.*, 1970; Monjour *et al.*, 1987). In 1996, a new case was described in a 48-year-old person who had stayed in Algeria (Harratet *al.*, 1998).

However, this disease exploded from 1999 to 2005, especially in the capital of Burkina Faso, where 7,444 cases of cutaneous leishmaniasis were described (Monjour *et al.*, 987). Recently, a new focus of cutaneous leishmaniasis caused by *L. Major* was discovered last year in the western part with most specifically in Larama, in the Hauts-Bassins region (Konate *et al.*, 2010). Regarding the intermediate hosts, the sandflies' spatial distribution and ecology have been studied in Africa since the colonial times (Abonnencand Larivière, 1959). In addition, a very elaborated work has led to identifying 23 species of sandflies in that country (Abonnenc and Pastre, 1971).

Despite all these advances, our patient could not benefit from adequate care, forcing her to immigrate to Côte d'Ivoire after family advice. This situation could reflect the inadequate integration of leishmaniasis screening and the

management in the country. This state of affairs weakens the hope of the population suffering from this condition and cannot be adequately catered by the health system. Unlike Burkina Faso, Côte d'Ivoire experienced its first case of cutaneous leishmaniasis in the post-colonial period (Herouin and Orio, 1967). Three new cases were subsequently discovered here after 15 years of a resting period. One of the patients is a cooker from Burkina Faso who stayed there for a month, before returning to treat an ulcerative lesion about 2 cm in diameter located in the lower third of the left leg. The other two are natives of the western and eastern region of Côte d'Ivoire. They presented with ulceration of 3-5 cm in diameter at the top of the skull and a dry psoriasis form lesion of approximately 1.5 cm respectively (Ouhon *et al.*, 1982). The last cases of cutaneous leishmaniasis published are those reported in 1986 by Koné *et al.* (1986).

Human cases would have been reported in central Côte d'Ivoire. In fact, in 2018, 20 blood samples were taken from people with lesions suggestive of cutaneous leishmaniasis in the villages of Boblénou, Kouadio-Miankro, and Golikro by technicians from the health district of Bouaké northeast with support researchers from the Pierre Richet Institute in Bouaké. After the study, 9 suspected cases of cutaneous leishmaniasis were confirmed by PCR (Assovie *et al.*, 2019). In this country, a recent study allowed Assovie *et al.* (2019) to capture 135 sandflies. Among them 78 were morphologically identified. The genus *Sergentomyia* constituted 91% of harvests against 9% for the genus *Phlebotomus*. In terms of speciation, all the studies have not reported precisely what kind of species circulate in Côte d'Ivoire for cutaneous leishmaniasis. The information available in Côte d'Ivoire indicates for the first time on the presence of *L. Infantum* found in dogs (Hacène *et al.*, 2020). This case report also reveals the delicate nature of the patients' diagnosis and management of cutaneous leishmaniasis under the tropics. Indeed, this patient has been followed up in a specialized Ivorian center for three months without her illness being attributed to cutaneous leishmaniasis could say a lot about the quality of these patients' management. Several reasons could explain this type of situation, in particular: the scarcity of diagnosed cases, the insufficient time devoted to the Parasitology field in our training schools and the lack of the integration of the cutaneous leishmaniasis screenings into the national control programs against the Buruli ulcer even though this skin disease could easily be confused. Therapeutically, the first drugs for the treatment of leishmaniasis are the pentavalent derivatives of antimony. Unfortunately, the handling of this drug remains delicate. The therapeutic response of drugs can be assessed by considering the type of lesion, the species involved, or even the zymodema (a group of parasitic individuals of a species having particular

isoenzymes, generally the same) (Hellier *et al.*, 2020). Pentamidine is also prescribed and is administered parenterally at a dose of 4 mg base/kg and by injection. However, some side effects are observed (Esther *et al.*, 2002). Amphotericin B, an antifungal drug, used in the treatment of systemic mycosis is a powerful drug but mostly reserved for visceral forms. Miltefosine is the first oral drug available for the treatment of visceral and cutaneous leishmaniasis. It is less toxic than the previous ones if prescribed at a dose of 2.5 mg/kg per day. Aminoglycosides, widely used in diseases caused by bacterial pathogens, are now part of the therapeutic arsenal for cutaneous leishmaniasis (Neal *et al.*, 1995; Sarah *et al.*, 2015). Also, Gentamycin drug is used for CL with good results (Salah *et al.*, 2013).

In 2010, WHO produced a report on leishmaniasis control which indicates the recommendations for endemic countries (Who, 2010). In addition, treatments based on imidazoles have been proposed as an alternative in various settings (Brenner *et al.*, 1985; Mahajan *et al.*, 2007; Sánchez-Moreno *et al.*, 2012). An empiric Treatment based on per os Metronidazole combined with Gentamycin solution for the bandage of skin lesions to our patient made it possible to overcome this disease without major adverse effects, apart from the metallic taste reported.

CONCLUSION

Cutaneous leishmaniasis is endemic in Burkina Faso. The management of patients suffering from dermatological conditions characterized by chronic wounds, or ulcerated should not obscure the differential diagnosis with leishmaniasis. During the patient's interrogation, the clinician should always keep an open mind and seek known NTDs in endemic areas. Furthermore, the systematic leishmanial search reflex in the blood and skin lesions should be the rule in such circumstances under our tropics. The strengthening of human resources through training and the improvement of the technical platform of our reference laboratories in order to identify *Leishmania* species are urgently needed.

REFERENCES

- Abonnenc E, Larivière M (1959). Distribution of West African Phlebotomas (Diptercc-Psychodidae). Bull. De l'ZFAN. I: 209-226
- Abonnenc E, Pastre J (1971). Cah. ~ ORSTOM, ser. Ent. Méd. Parasitol.4:387-416.
- Alemayehu B, Alemayehu M (2017). Leishmaniasis: A Review on Parasite, Vector and Reservoir Host. Health Sci. J. 11: 519-524
- Alvar J, Vélez ID, Bern C, Herrero M, Desjeux P, Cano J, Jannin J, den Boer M (2012). Leishmaniasis worldwide and global estimates of its incidence. PLoS One. 7:e35671
- Anofel (2016). Parasitoses et Mycoses: Des Regions Temperees et Tropicales.3rd edn.Issy-les-Moulineaux, France: Elsevier Masson, pp.1-470
- Assovie KR, Djohan V, Atta AA, Aké DH, Aka TA, Akoliba KP, Djakaridja B, Ta BT, Kaba D, Yapi YG (2020). Diversite Phlebotomienne Dans Trois Villages De La Commune De Bouake (Côte D'ivoire) Durant La Periode De Mars A Juin 2019. Eur. Sci. J. 16: 224-240.
- Brenner S (1985). Topical treatment with imidazole for cutaneous leishmaniasis. Isr. J. Med. Sci. 21:163-164.
- Bruckner DA, Labarca JA (1999). Leishmania and Trypanosoma. In: Murray PR, Baron EJ, Pfaller MA, Tenover FC, Tenover RH, editors. Manual of Clinical Microbiology. New York, US: ASM Press, pp. 1365-1373.
- Dietmar S (2017). The history of leishmaniasis. Parasites & Vectors. 10:1-10
- Esther JS, Martinus AV, Ramon MS, Rudy FM (2002). Pentamidine, the drug of choice for the treatment of cutaneous leishmaniasis in Surinam. Int J Dermatol. 41:796-800.
- HacèneM, Younes L, EricA, Amar B, Sylvestre D, Davoust B, Mediannikov O (2020). Molecular and serological detection of pathogens with animal and human vector transmission in the blood of dogs from Côte d'Ivoire. Comp. Immunol. Microbiol. Infect. Dis. 69:101412.
- Harrat Z, Platrong F, Benikhlef R, Lami P, Belkaid M, Dedet JP (1998). Leishmania major MON-74 as a causative agent of cutaneous leishmaniasis in Burkina. Trans. R. Soc. Trop. Med. Hyg. 92:355.
- Hellier I, Dereure O, Tournillac I, F Pratlong, B Guillot, Dedet JP, GuilhouJJ (2000). Treatment of Old World cutaneous leishmaniasis by pentamidine isethionate. Dermatology200:120-123.
- Hepburn NC (2003). Cutaneous leishmaniasis: an overview. J. Postgrad. Med. 49 :50-54.
- Herouin P, Orio J (1967). Première observation de leishmaniose cutanée en Côte d'Ivoire. Rev. Méd. Côte d'Ivoire. 3:32-37.
- Konate I, Sangare I, Zoungrana J, Meda N, Kafando C, Sawadogo Y, Dabiré R, Meda N, Diallo B, Andonaba JB, Barro-Traoré F, Niamba P, Traoré A (2020). Description of a new epidemic focus of cutaneous Leishmaniasis major in western Burkina Faso. Pan Afr. Med. J. 35: 1-10.
- Koné M, Ouhon J, Assoumou A, Colin M, Ferly-Thérizol M, Assalé G (1986). Cutaneous leishmaniasis in Côte d'Ivoire:Clinical and parasitological study (about six cases). Rev. Méd. Côte d'Ivoire. 75: 128-131.

- Louise CH, Dominic H, Sofia A, Becks H, Ruth D, Heather B, Kimberly J, Susan D, Elena S, Philip D (2019). People are neglected, not diseases: the relationship between disability and neglected tropical diseases. *Trans. R. Soc. Trop. Med. Hyg.* 113: 828–833
- Mahajan VK, Sharma NL (2007). Therapeutic options for cutaneous leishmaniasis. *J. Dermatolog. Treat.* 18: 97–104.
- Marty P (2005). Visceral leishmaniasis: epidemiology and diagnosis. *Med. Mal. Infect.* 35:72-73
- Menard M, Gidel R, Ghipponi P (1970). A case of generalized cutaneous leishmaniasis in an infant in Haute-Volta. *Ann. Soc. Belge Méd. Trop.* 50:281-292
- Monjour L, De Lorenzi G, Volta C, Vouldoukis I, Frommel D (1987). Leishmaniasis in Burkina Faso. *Trans. R. Soc. Trop. Med. Hyg.* 81:746
- Neal RA, Allen S, McCoy N, Olliaro P, Croft SL (1995). The sensitivity of *Leishmania* species to aminosidine. *J. Antimicrob. Chemother.* 35: 577-584.
- Oddou A (1962). Sur treize cas de leishmaniose cutanée en Haute-Volta. *Bull. Soc. Med. Afr. Noire Lang. Fr.* 7: 284-287.
- Ouhon J, koné M, Assoumou A, Bleulaine SC, Piguél M, Aka PA, Ferly-Thérizol M, Assalég (1982). A propos de 3 cas de leishmaniose cutanée humaine diagnostiqués au laboratoire de parasitologie (C.H.U de Cocody-Abidjan). *Rev. Méd. Côte d'Ivoire.* 188(67): 32- 37
- Richard DW (2009). *Service Medical Entomology for students.* 4th edn. Cambridge, UK: Cambridge University Press, pp.93-102
- Salah AB, Messaoud NB, Guedri E, Zaatour A, Alaya NB, Bettaieb J, Gharbi A, Hamida NB, Boukthir A, Chlif S, Abdelhamid K, El Ahmadi Z, Louzir H, Mokni M, Morizot G, Buffet P, Smith PL, Kopydlowski KM, Kreishman-Deitrick M, Smith SK, Nielsen CJ, Ullman DR, Norwood JA, Thorne GD, McCarthy WF, Adams RC, Rice RM, Tang D, Berman J, Ransom J, Magill AJ, Grogl M (2013). Topical paromomycin with or without gentamicin for cutaneous leishmaniasis. *N. Engl. J. Med.* 368:524–532.
- Sanchez-Moreno M, Gomez-Contreras F, Navarro P, Marin C, Ramirez-Macias I, Olmo F, Sanz AM, Campayo L, Cano C, Yunta MJ (2012). In vitro leishmanicidal activity of imidazole- or pyrazole-based benzo[g] phthalazine derivatives against *Leishmania infantum* and *Leishmania braziliensis* species. *J. Antimicrob. Chemother.* 67:387–397.
- Sarah GP, Konstantinos PM, George ND (2015). Leishmaniasis revisited: Current aspects on epidemiology, diagnosis and treatment. *J. Transl. Int. Med.* 3: 43–50
- WHO (2010). Control of the leishmaniasis. *World Health Organ. Tech. Rep. Ser.* 949:1-186.