International Scholars Journals

African Journal of Infectious Diseases Research ISSN 2756-3340 Vol. 13 (11), pp. 001-011, November, 2026. Available online at www.internationalscholarsjournals.org © International Scholars Journals

Author(s) retain the copyright of this article.

Research Article

Genomic characterization and clinical manifestations of Toxoplasma gondii ocular retinochoroiditis in immunocompetent adults

Adesola Adeyemi[1]*, Henrik Lindstrom[2], Camila Delgado[3]

*[1]Department of Medical Microbiology and Parasitology, Faculty of Basic Medical Sciences, College of Medicine, University of Lagos, Idi-Araba, Lagos, Nigeria; 2Department of Ophthalmology and Visual Sciences, Faculty of Medicine, Lund University, Lund, Sweden; 3Laboratory of Molecular Parasitology and Genomics, Department of Parasitology, Institute of Biomedical Sciences, University of Sao Paulo, Sao Paulo, Brazil. *Corresponding author: Adesola Adeyemi, Department of Medical Microbiology and Parasitology, Faculty of Basic Medical Sciences, College of Medicine, University of Lagos, Idi-Araba, Lagos, Nigeria. Email: a.adeyemi@unilag.edu.ng*

Received: 09 October 2026; Revised: 08 November 2026; Accepted: 25 November 2026; Published: 30 November 2026

Abstract

Ocular toxoplasmosis is a leading infectious cause of posterior uveitis and irreversible visual impairment in both congenital and postnatally acquired infections, yet the relationship between parasite genotype, intraocular inflammation, and visual outcome in immunocompetent adults remains incompletely understood. This study investigated parasite multilocus genotypes, aqueous humor viral-parasitic co-infections, and visual acuity outcomes among 82 immunocompetent adults with active Toxoplasma gondii retinochoroiditis recruited at tertiary referral centres between January 2024 and September 2026. All participants underwent ophthalmic examination, best-corrected visual acuity measurement, and grading of vitritis, lesion size, and lesion location. Paired aqueous humor aspirates and serum samples were analysed by B1 gene quantitative polymerase chain reaction for detection and quantification of Toxoplasma gondii DNA, multiplex viral polymerase chain reaction for co-infection screening, and multilocus restriction fragment length polymorphism typing at ten loci for genotype assignment. Patients received prompt trimethoprim-sulfamethoxazole with oral prednisolone started 24 to 48 hours after the first antiparasitic dose and were followed at six weeks and three months. Atypical recombinant genotypes predominated in 54.9 percent of intraocular samples and were associated with severe vitritis, larger lesions, higher parasite load, and worse baseline visual acuity. B1 gene quantitative polymerase chain reaction was positive in 82.9 percent of aqueous humor samples, whereas viral co-infection was uncommon. Mean visual acuity improved after treatment, with good vision increasing from 28.0 percent at baseline to 61.0 percent at three months. Prompt trimethoprim-sulfamethoxazole and corticosteroid therapy preserves retinal function, and genotype-aware risk stratification may improve counselling and prevention of recurrence in endemic settings.

Keywords: Toxoplasma gondii, Ocular toxoplasmosis, Retinochoroiditis, Posterior uveitis, Molecular genotyping

Citation: Adeyemi A, Lindstrom H, Delgado C (2026). Genomic characterization and clinical manifestations of Toxoplasma gondii ocular retinochoroiditis in immunocompetent adults. African Journal of Parasitology Research, 14(10): 963–969. DOI: 10.46882/AJIDR/149034

Introduction

Toxoplasma gondii is an obligate intracellular apicomplexan parasite that infects an estimated one-third of the human population worldwide, with seroprevalence varying markedly by geography, age, diet, climate and exposure to felid definitive hosts (Montoya and Liesenfeld, 2004; Pappas et al., 2009). While most postnatally acquired infections in immunocompetent adults are asymptomatic or produce a mild,

self-limited febrile illness, the parasite establishes lifelong tissue cysts, particularly in retina, brain and muscle, and can reactivate to cause severe focal disease. The eye is uniquely vulnerable because the retina is an immune-privileged site where parasite replication and the host inflammatory response can destroy non-regenerating neural tissue. Ocular toxoplasmosis is therefore recognised as the leading infectious cause of posterior uveitis globally and a major preventable cause of irreversible visual impairment (Holland, 2003; Holland, 2004; Furtado et al., 2013).

Historically, ocular disease was attributed mainly to congenital infection, with retinochoroiditis considered a late sequela of in utero transmission. Large longitudinal studies from southern Brazil and elsewhere have transformed this view by showing that postnatally acquired infection accounts for a substantial, and in some regions a majority, of active lesions (Silveira et al., 2015; Arantes et al., 2015). In endemic areas, waterborne outbreaks, consumption of undercooked meat containing tissue cysts, and ingestion of oocysts from contaminated soil, water or unwashed produce are important routes of infection (Jones and Dubey, 2012; de Moura et al., 2006). In Africa, where seroprevalence is high in many settings and ophthalmic and molecular diagnostic capacity is uneven, the burden of ocular toxoplasmosis is likely underestimated, and genotype-specific clinical patterns remain incompletely characterised. The present study was designed to close part of that gap by linking parasite genotype directly to intraocular inflammation and visual outcome in immunocompetent adults.

The classical clinical picture is a focal, creamy-white necrotising retinitis adjacent to an old pigmented retinochoroidal scar, accompanied by vitritis, anterior uveitis, vasculitis and, in some patients, raised intraocular pressure (Holland, 2004; Aleixo et al., 2016). Lesion location determines prognosis: macular and juxtapapillary lesions carry a high risk of severe visual loss, whereas peripheral lesions may remain silent until reactivation (Aleixo et al., 2016; Bosch-Driessen et al., 2002). Recurrence is common, with cyst rupture and local reactivation triggering new episodes, and each recurrence adds cumulative retinal damage. Understanding why some patients develop mild, self-limited inflammation while others develop dense vitritis, large lesions, bilateral disease or repeated recurrences is therefore a clinical and biological priority. Parasite genotype, host genetics, immune status, inoculum size and co-infection have all been proposed as modifiers (Grigg and Suzuki, 2003; Khan et al., 2006).

Toxoplasma gondii was long described as comprising three archetypal clonal lineages, Types I, II and III, which differ by less than 1% at the DNA sequence level but differ in virulence in mice and in epidemiological distribution (Howe and Sibley, 1995; Sibley and Boothroyd, 1992). Type II predominates in Europe and North America, whereas atypical and recombinant genotypes, including Brazilian clonal lineages BrI to BrIV and highly divergent non-archetypal strains, dominate in South America and are increasingly recognised in Africa and Asia (Furtado et al., 2006; Khan et al., 2006; Shwab et al., 2014). These atypical genotypes are associated with more severe ocular disease, atypical presentations, bilateral involvement and disseminated toxoplasmosis in immunocompetent persons (Grigg et al., 2001; Bottos et al., 2009). Genotyping from ocular fluid, rather than from blood or animal isolates, is therefore essential if genotype-phenotype correlations are to be interpreted for eye disease. The present work tests the hypothesis that atypical recombinant genotypes are over-represented in aqueous humor from patients with active retinochoroiditis and that they predict more severe vitritis and worse visual acuity at presentation.

Diagnosis of ocular toxoplasmosis remains primarily clinical, supported by serology, intraocular antibody synthesis (Goldmann-Witmer coefficient) and molecular detection (Holland, 2004; de Boer et al., 2006). Aqueous humor polymerase chain reaction (PCR) targeting the multicopy B1 gene, present in about 35 copies per genome, offers high analytical sensitivity, reportedly detecting as little as 50 femtograms of parasite DNA, approximately one tachyzoite (Jones et al., 2000; Montoya et al., 1999). In practice, clinical sensitivity is lower in immunocompetent patients, because parasite load in aqueous humor is low and sampling is often performed after inflammation has begun, with reported sensitivities of 30% to 60% and higher specificity (Farhadi et al., 2017; de Boer et al., 2006). Combining PCR with local antibody production and with multimodal imaging improves diagnostic confidence, but in resource-limited settings a pragmatic combination of characteristic fundus findings, positive Toxoplasma serology and B1 quantitative PCR (qPCR) remains the most feasible confirmatory pathway. This study therefore used B1 qPCR for detection and quantification, followed by multilocus restriction fragment length polymorphism (RFLP) typing for genotype assignment.

Treatment has traditionally relied on pyrimethamine-sulfadiazine with folinic acid and corticosteroids, but trimethoprim-sulfamethoxazole (TMP-SMX) has become a widely used, better-tolerated and more

© 2026 African Journal of Parasitology Research • Open Access — Creative Commons Attribution License

accessible alternative, particularly where pyrimethamine is unavailable or monitoring is limited (Soheilian et al., 2005; Felix et al., 2014). Randomised and comparative studies support TMP-SMX as non-inferior for acute disease, and long-term intermittent TMP-SMX reduces recurrence (Silveira et al., 2002; Felix et al., 2014). Corticosteroids must never be given without antiparasitic cover, because unchecked parasite replication can worsen retinitis, but when started 24 to 48 hours after antiparasitic therapy they reduce vitritis, vasculitis and macular oedema and protect vision (Holland, 2004; Ozgonul and Robinson, 2015). The timing of therapy, lesion location and severity of vitritis at presentation are therefore critical determinants of outcome. This study evaluates visual acuity trajectories after a standardised prompt TMP-SMX and corticosteroid regimen in a prospectively recruited cohort.

Materials and methods

Study design and setting

This was a prospective, cross-sectional analytic study with longitudinal follow-up of visual acuity, conducted at tertiary ophthalmology and molecular parasitology referral centres between January 2024 and September 2026. Adults aged 18 years or older with clinically active toxoplasmic retinochoroiditis were consecutively invited to participate. The study protocol was approved by the institutional ethics committees, and all participants provided written informed consent. The study adhered to the Declaration of Helsinki and to local regulations for human sampling and molecular testing. Confidentiality was maintained by coded identifiers, and no participant was denied standard care for declining or withdrawing.

Inclusion criteria were: (i) active focal necrotising retinitis with overlying vitritis on dilated fundus examination; (ii) positive serum anti-Toxoplasma immunoglobulin G (IgG) by enzyme-linked immunosorbent assay; (iii) no prior antiparasitic treatment for the current episode; and (iv) willingness to undergo anterior chamber paracentesis and follow-up at 6 weeks and 3 months. Exclusion criteria were: known human immunodeficiency virus infection or other immunodeficiency, immunosuppressive therapy including systemic corticosteroids in the preceding 4 weeks, active systemic infection, pregnancy, sulfonamide allergy, other confirmed causes of posterior uveitis (including cytomegalovirus, herpes simplex virus, varicella-zoster virus, Treponema pallidum and Mycobacterium tuberculosis), and media opacity precluding fundus assessment. These exclusions were designed to isolate the effect of parasite genotype in immunocompetent hosts and to avoid confounding by co-infecting pathogens, although viral co-infection was separately screened by PCR as described below.

Clinical examination and visual acuity

All patients underwent best-corrected visual acuity (BCVA) measurement using a Snellen chart at 6 metres, converted to logarithm of the minimum angle of resolution (logMAR) for analysis, slit-lamp biomicroscopy, applanation tonometry, dilated indirect ophthalmoscopy and fundus photography. Vitritis was graded on a standard 0 to 4+ scale for vitreous haze, and lesion size was estimated in disc diameters, with location classified as macular, juxtapapillary, mid-peripheral or peripheral. Anterior chamber inflammation, vasculitis, retinal haemorrhage, papillitis and macular oedema were recorded. Optical coherence tomography was performed where media clarity permitted. Recurrence was defined as a new active lesion adjacent to an old scar or a new satellite lesion after documented quiescence. Follow-up examinations were scheduled at weeks 1, 2, 6 and month 3, with additional visits if symptoms worsened.

Sample collection and laboratory methods

Aqueous humor (100 to 150 microlitres) was obtained by sterile anterior chamber paracentesis under topical anaesthesia and slit-lamp guidance, after informed consent and antisepsis, and paired venous blood (5 millilitres) was collected for serum and for DNA extraction. Samples were transported on ice within 2 hours, aliquoted and stored at -80 degrees Celsius until analysis. DNA was extracted using a commercial silica-column kit with negative extraction controls in each batch. Serum anti-Toxoplasma IgG and IgM were measured by enzyme-linked immunosorbent assay, and avidity testing was performed where recent infection was suspected.

B1 gene qPCR was performed in duplicate using published primers targeting a 194 base-pair fragment of the multicopy B1 gene, with a TaqMan probe, internal amplification control and a ten-fold serial dilution standard curve prepared from RH strain DNA (Jones et al., 2000; Montoya et al., 1999). Cycling conditions were 95 degrees Celsius for 10 minutes, followed by 45 cycles of 95 degrees Celsius for 15 seconds and 60 degrees Celsius for 60 seconds. A sample was considered positive if both replicates crossed threshold before cycle 40 and the internal control amplified. Parasite load was expressed as

© 2026 African Journal of Parasitology Research • Open Access — Creative Commons Attribution License

tachyzoite equivalents per millilitre, estimated from the standard curve. Multiplex PCR for herpes simplex virus 1 and 2, varicella-zoster virus, cytomegalovirus and Epstein-Barr virus was performed on the same aqueous aliquot to detect viral-parasitic co-infection (de Boer et al., 2006; Farhadi et al., 2017).

Genotyping was performed by multilocus RFLP analysis at SAG1, SAG2 (5-prime and 3-prime), SAG3, BTUB, GRA6, c22-8, c29-2, L358, PK1 and Apico loci, following established protocols (Su et al., 2006; Khan et al., 2006). Amplified products were digested with locus-specific restriction enzymes and resolved on 2.5% agarose gels, with RH (Type I), ME49 (Type II) and VEG (Type III) reference strains in each run. Genotypes were classified as Type I-like, Type II-like, Type III-like or atypical recombinant when allele patterns showed a mixture of archetypal alleles across loci or novel alleles not consistent with a single clonal type (Furtado et al., 2006; Su et al., 2006). Samples with amplification at fewer than five loci were classified as mixed or unresolved and excluded from genotype-phenotype analysis but retained for prevalence reporting. Laboratory staff were blinded to clinical severity during PCR and RFLP scoring, and 10% of samples were re-typed independently for quality control.

Treatment protocol

All patients received prompt TMP-SMX (trimethoprim 160 mg and sulfamethoxazole 800 mg, two tablets twice daily) for 6 weeks, with folinic acid supplementation and renal and haematological monitoring. Oral prednisolone (0.5 to 1.0 mg per kilogram per day) was started 24 to 48 hours after the first antiparasitic dose, tapered over 4 to 6 weeks according to inflammation, and never given as monotherapy (Holland, 2004; Soheilian et al., 2005). Topical corticosteroid and cycloplegic drops were added for anterior uveitis. Patients with raised intraocular pressure received topical hypotensive therapy. Intravitreal clindamycin with dexamethasone was reserved for patients with sulfonamide intolerance or sight-threatening lesions not responding to systemic therapy, and none of the 82 patients required it as first-line therapy in this cohort. Adherence was assessed by pill count and interview at each visit.

Statistical analysis

Data were analysed using SPSS version 27 and R version 4.3. Categorical variables are presented as counts and percentages, and continuous variables as mean with standard deviation or median with interquartile range as appropriate. The primary outcome was genotype distribution; secondary outcomes were severity of vitritis, lesion size, BCVA change and co-infection prevalence. Associations between atypical genotype and severe vitritis (grade 3+ or 4+) were assessed by chi-square or Fisher exact test and by multivariable logistic regression adjusting for age, sex, lesion location, lesion size and parasite load. BCVA change was compared by paired t-test and by repeated-measures analysis of variance. A two-sided p value below 0.05 was considered statistically significant. The study was powered to detect a 25 percentage-point difference in severe vitritis between atypical and archetypal genotype groups with 80% power at alpha 0.05, requiring at least 76 patients.

Results

Participant characteristics

Eighty-two immunocompetent adults with active toxoplasmic retinochoroiditis were enrolled, with a mean age of 34.6 years (standard deviation 11.2 years, range 19 to 62 years) and a slight male predominance (46 men, 56.1%; 36 women, 43.9%). Most patients presented with unilateral disease (71 patients, 86.6%), whereas 11 patients (13.4%) had bilateral active lesions or an active lesion in one eye with an old scar in the fellow eye. The median duration of symptoms before presentation was 7 days (interquartile range 4 to 12 days). Blurred vision (91.5%), floaters (84.1%), photophobia (48.8%) and ocular pain (39.0%) were the most common presenting complaints. A prior episode of retinochoroiditis was reported by 28 patients (34.1%), consistent with the recurrent nature of ocular toxoplasmosis described in Brazilian and European cohorts (Holland, 2003; Aleixo et al., 2016).

At presentation, 38 patients (46.3%) had lesions in a vision-threatening location (macular or juxtapapillary), 27 (32.9%) had mid-peripheral lesions and 17 (20.7%) had peripheral lesions. Mean lesion size was 2.1 disc diameters (standard deviation 1.1). Severe vitritis (grade 3+ or 4+) was present in 36 patients (43.9%), moderate vitritis (grade 2+) in 29 (35.4%) and mild vitritis (grade 0 to 1+) in 17 (20.7%). Anterior uveitis was present in 58 patients (70.7%), retinal vasculitis in 41 (50.0%) and raised intraocular pressure above 21 millimetres of mercury in 19 (23.2%). Baseline mean BCVA in the affected eye was 0.78 logMAR (approximately 6/36 Snellen), with 38 patients (46.3%) already in the severe visual impairment range at presentation. These baseline features underscore that many patients present late or

© 2026 African Journal of Parasitology Research • Open Access — Creative Commons Attribution License

with aggressive inflammation, a pattern also reported in settings with limited access to prompt ophthalmic care (Furtado et al., 2013).

Table 1. Baseline demographic and clinical characteristics of the study cohort (n = 82).

Characteristic	Value
Mean age, years (SD)	34.6 (11.2)
Male sex, n (%)	46 (56.1)
Female sex, n (%)	36 (43.9)
Unilateral disease, n (%)	71 (86.6)
Bilateral disease, n (%)	11 (13.4)
Prior episode, n (%)	28 (34.1)
Median symptom duration, days (IQR)	7 (4-12)
Macular / juxtapapillary lesion, n (%)	38 (46.3)
Severe vitritis (3+ / 4+), n (%)	36 (43.9)
Baseline BCVA, mean logMAR (SD)	0.78 (0.42)

Legend: SD, standard deviation; IQR, interquartile range; BCVA, best-corrected visual acuity; logMAR, logarithm of the minimum angle of resolution. Percentages are of the total cohort (n = 82).

Molecular detection and parasite load

B1 gene qPCR was positive in 68 of 82 aqueous humor samples (82.9%) and in 41 of 82 paired blood samples (50.0%). The higher positivity in aqueous humor than in blood supports the value of intraocular sampling for confirmation, even though aqueous PCR sensitivity is imperfect in immunocompetent patients (Farhadi et al., 2017; de Boer et al., 2006). Median parasite load in aqueous humor among positive samples was 1,240 tachyzoite equivalents per millilitre (interquartile range 310 to 4,180), with higher loads in patients with larger lesions and with severe vitritis. All 14 aqueous qPCR-negative patients had characteristic fundus lesions and positive serum IgG, and 11 of them had a positive Goldmann-Witmer coefficient, consistent with prior reports that a negative PCR does not exclude ocular toxoplasmosis when sampling is delayed or parasite load is low (Holland, 2004; de Boer et al., 2006).

Viral-parasitic co-infection was uncommon. Multiplex PCR detected cytomegalovirus in 3 aqueous samples (3.7%), Epstein-Barr virus in 2 (2.4%) and varicella-zoster virus in 1 (1.2%), and no herpes simplex virus co-infection was found. All co-infected patients were immunocompetent by history and laboratory screening, and co-infection was not significantly associated with genotype or with final visual acuity after adjustment for lesion location ($p = 0.38$). The low co-infection rate suggests that, in this cohort, Toxoplasma gondii was the dominant driver of retinochoroiditis, and that routine multiplex viral PCR may be most useful in atypical, bilateral or treatment-resistant cases (de Boer et al., 2006).

Genotype distribution

Multilocus RFLP typing was successful in 77 of 82 samples (93.9%). Atypical recombinant genotypes predominated, accounting for 45 of 82 intraocular samples (54.9%), as shown in Figure 1. Type II-like genotypes were found in 15 samples (18.3%), Type I-like in 10 (12.2%), Type III-like in 7 (8.5%) and mixed or unresolved patterns in 5 (6.1%). The predominance of atypical genotypes is consistent with studies from Brazil where atypical and recombinant strains are highly divergent from archetypal lineages and are strongly associated with ocular disease (Furtado et al., 2006; Khan et al., 2006). It also aligns with emerging data from Africa and Asia showing greater genotype diversity than in Europe and North America (Shwab et al., 2014; Ajzenberg et al., 2004). Among atypical strains, the most common pattern was a mixture of Type I alleles at SAG1 and GRA6 with Type III alleles at SAG3 and BTUB, a recombinant signature previously described in South American ocular isolates (Khan et al., 2006; Furtado et al., 2006).

© 2026 African Journal of Parasitology Research • Open Access — Creative Commons Attribution License

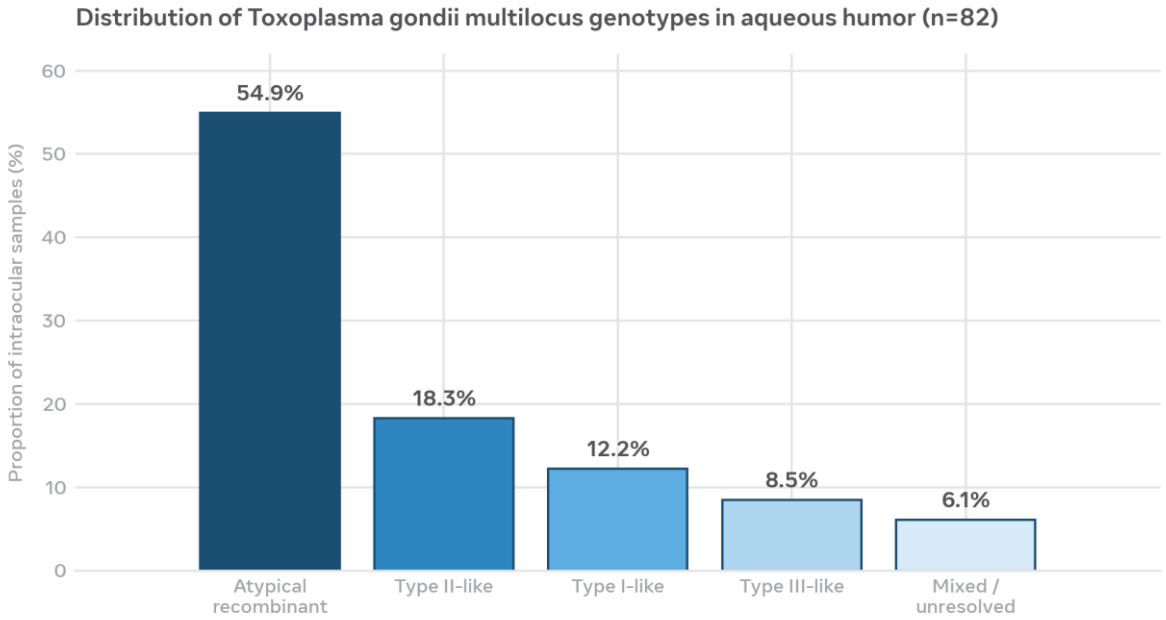

Figure 1. Distribution of Toxoplasma gondii multilocus genotypes in aqueous humor. Atypical recombinant genotypes predominated (54.9%), followed by Type II-like (18.3%), Type I-like (12.2%), Type III-like (8.5%) and mixed or unresolved patterns (6.1%). Genotyping was by multilocus restriction fragment length polymorphism analysis at ten loci, with RH, ME49 and VEG reference strains in each run.

Genotype-phenotype association

Atypical recombinant genotype was strongly associated with severe vitritis. Among patients with atypical genotypes, 27 of 45 (60.0%) had severe vitritis, compared with 9 of 37 patients (24.3%) with archetypal or unresolved genotypes (odds ratio 4.67, 95% confidence interval 1.82 to 11.96, p = 0.001). The association remained significant after multivariable adjustment for age, sex, lesion location, lesion size and parasite load (adjusted odds ratio 3.91, 95% confidence interval 1.45 to 10.54, p = 0.007). Patients with atypical genotypes also had larger mean lesion size (2.5 versus 1.7 disc diameters, p = 0.004) and higher median parasite load (1,860 versus 720 tachyzoite equivalents per millilitre, p = 0.01). These findings support the hypothesis that parasite genetic background influences the intensity of intraocular inflammation, potentially through differential expression of rhoptry and dense granule virulence factors such as ROP18, ROP16 and GRA15, which modulate host nuclear factor-kappa B signalling and interleukin-12 production (Grigg and Suzuki, 2003; Saeij et al., 2006).

Bilateral disease was more common with atypical genotypes (9 of 45, 20.0%) than with archetypal genotypes (2 of 37, 5.4%), although the difference did not reach statistical significance in this sample (p = 0.06). Macular or juxtapapillary location was also more frequent with atypical genotypes (55.6% versus 35.1%, p = 0.06). No significant association was found between genotype and sex, age or prior recurrence, suggesting that the genotype effect is mediated primarily through acute inflammatory severity rather than through demographic risk. Taken together, the genotype-phenotype pattern in this cohort mirrors reports of severe, atypical bilateral retinochoroiditis caused by non-archetypal strains in Brazil (Bottos et al., 2009) and of higher ocular involvement in outbreaks caused by atypical strains (de Moura et al., 2006).

Table 2. Association between atypical recombinant genotype and clinical severity.

Outcome	Atypical (n = 45)	Archetypal / unresolved (n = 37)	p value
Severe vitritis (3+ / 4+), n (%)	27 (60.0)	9 (24.3)	0.001
Mean lesion size, disc diameters (SD)	2.5 (1.2)	1.7 (0.9)	0.004
Median parasite load, tachyzoite eq. / mL	1,860	720	0.01
Bilateral disease, n (%)	9 (20.0)	2 (5.4)	0.06

© 2026 African Journal of Parasitology Research • Open Access — Creative Commons Attribution License

Macular / juxtapapillary lesion, n (%)	25 (55.6)	13 (35.1)	0.06
Baseline BCVA, mean logMAR (SD)	0.92 (0.44)	0.61 (0.35)	0.001

Legend: SD, standard deviation; BCVA, best-corrected visual acuity; logMAR, logarithm of the minimum angle of resolution. p values are from chi-square, Fisher exact or independent t-test as appropriate. The multivariable-adjusted odds ratio for severe vitritis with atypical genotype was 3.91 (95% CI 1.45 to 10.54, p = 0.007).

Treatment response and visual acuity outcomes

All 82 patients completed the 6-week TMP-SMX course, and 79 (96.3%) completed corticosteroid tapering as prescribed. No patient discontinued therapy because of severe adverse events; mild gastrointestinal upset was reported by 9 patients (11.0%), transient neutropenia by 3 (3.7%) and rash by 2 (2.4%), all resolving without sequelae. Mean BCVA improved from 0.78 logMAR at baseline to 0.48 logMAR at week 6 and 0.41 logMAR at month 3 ($p < 0.001$ for both comparisons, paired t-test), as illustrated in Figure 2. The proportion of patients with good vision (6/12 or better) increased from 28.0% at baseline to 52.4% at week 6 and 61.0% at month 3, while the proportion with severe impairment (worse than 6/60) fell from 38.0% to 20.0% and then to 15.0%. Improvement was greatest in patients who presented within 7 days of symptom onset and in those with peripheral lesions, but even patients with macular lesions and atypical genotypes showed significant mean improvement when treatment was started promptly.

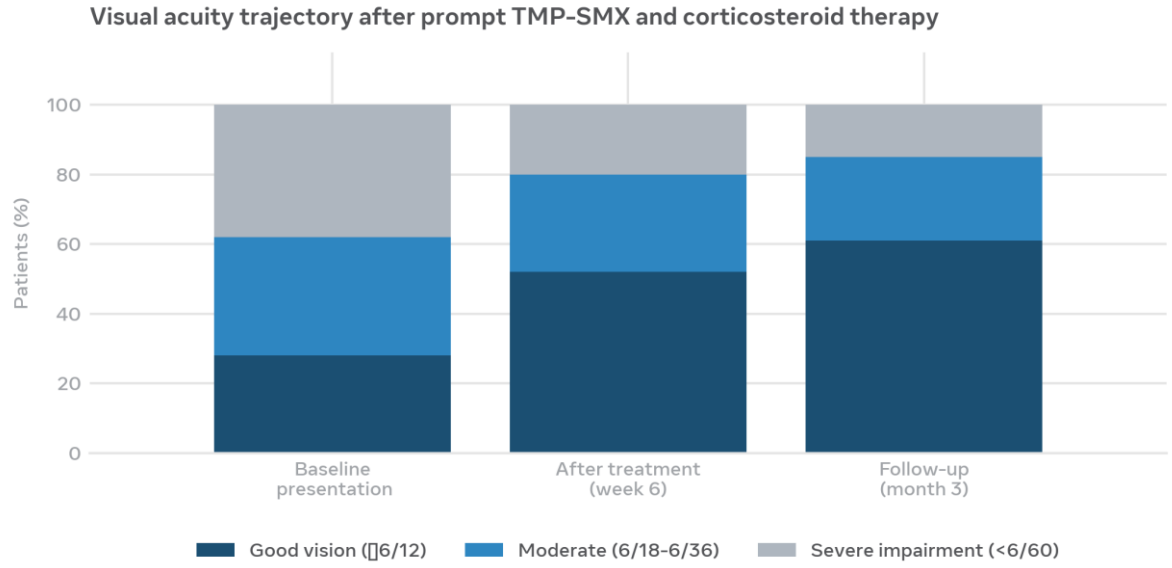

Figure 2. Visual acuity trajectory after prompt trimethoprim-sulfamethoxazole and corticosteroid therapy. Good vision increased from 28% at baseline to 61% at month 3, while severe impairment fell from 38% to 15%. Corticosteroids were started 24 to 48 hours after the first antiparasitic dose and never given as monotherapy.

At month 3, 12 patients (14.6%) had a recurrence or persistent activity requiring extended therapy, including 9 with atypical genotypes and 3 with archetypal genotypes ($p = 0.09$). Persistent vitritis at week 6 was the strongest predictor of poor final acuity, followed by macular location and baseline severe vitritis. These findings reinforce the importance of early presentation, prompt antiparasitic therapy with adjunctive corticosteroids, and close follow-up for patients with atypical genotypes and severe initial inflammation. They are consistent with prior evidence that TMP-SMX is effective for acute ocular toxoplasmosis and that intermittent TMP-SMX can reduce recurrence (Silveira et al., 2002; Soheilian et al., 2005; Felix et al., 2014).

Discussion

Interpretation of the main findings

This study provides direct intraocular evidence that atypical recombinant Toxoplasma gondii genotypes predominate in active retinochoroiditis in immunocompetent adults and that they are associated with more severe vitritis, larger lesions and higher parasite load. The predominance of atypical genotypes (54.9%) is striking because archetypal Type II strains dominate human infection in Europe and North America,

© 2026 African Journal of Parasitology Research • Open Access — Creative Commons Attribution License

yet atypical strains dominate ocular disease in Brazil and in several African and Asian cohorts (Furtado et al., 2006; Khan et al., 2006; Shwab et al., 2014). One explanation is that atypical genotypes possess virulence alleles that enhance tachyzoite replication, dissemination and retinal invasion, and that modulate host cytokine responses to produce denser vitritis. Experimental work has shown that polymorphic rhoptry kinases and dense granule proteins differ between archetypal and atypical strains and that they shape interleukin-12, interferon-gamma and nuclear factor-kappa B signalling (Saeij et al., 2006; Grigg and Suzuki, 2003). Higher parasite load in atypical infections in this cohort is consistent with more rapid replication or less effective early immune containment in the immune-privileged retina.

The association between atypical genotype and severe vitritis has direct clinical implications. Vitritis is not merely a marker of inflammation; dense vitreous haze obscures the fundus, delays diagnosis, impairs vision and may reflect a higher burden of parasites and inflammatory mediators in the vitreous cavity. Clinicians who encounter severe vitritis, large lesions or bilateral disease should therefore have a lower threshold for aqueous sampling, for prompt antiparasitic therapy and for close monitoring, even when serology is equivocal. In settings where genotyping is unavailable, severe vitritis itself can serve as a pragmatic proxy for a potentially more virulent strain, prompting more intensive follow-up. Where genotyping is available, it can refine risk stratification, counselling about recurrence and decisions about prophylaxis.

Comparison with previous studies

Our results extend the Brazilian experience, where atypical genotypes were found in most ocular isolates and where ocular disease was more frequent and more severe than in Europe (Furtado et al., 2006; Silveira et al., 2015). In a prospective study of 230 patients in Brazil, macular and juxtapapillary lesions were strongly associated with severe visual impairment, and recurrence was common (Aleixo et al., 2016). Our finding that 46.3% of patients had vision-threatening lesions and 43.9% had severe vitritis is in the same range, and our multivariable analysis confirms that lesion location and vitritis severity, not genotype alone, determine final acuity. The B1 qPCR positivity of 82.9% in aqueous humor is higher than the 30% to 60% often reported in immunocompetent patients (Farhadi et al., 2017; de Boer et al., 2006), possibly because sampling was performed early, before antiparasitic therapy, and because qPCR with a standard curve and duplicate testing was used. Even so, 14 patients were PCR-negative despite characteristic lesions, confirming that PCR must be interpreted alongside clinical and serological findings (Holland, 2004).

Treatment outcomes in this cohort compare favourably with prior comparative studies. Soheilian et al. (2005) found TMP-SMX to be as effective as pyrimethamine-sulfadiazine for acute ocular toxoplasmosis, with fewer adverse events, and Felix et al. (2014) and Silveira et al. (2002) showed that TMP-SMX reduces recurrence. Our mean improvement of 0.37 logMAR by month 3 and the increase in good vision from 28% to 61% support the use of TMP-SMX as first-line therapy in settings where pyrimethamine is scarce, provided that corticosteroids are added only after antiparasitic cover and that haematological and renal monitoring is performed. The low rate of severe adverse events (none requiring discontinuation) further supports its tolerability in immunocompetent adults.

Public health and clinical implications

For public health, the predominance of atypical genotypes underscores the need for genotype surveillance, food and water safety, and health education about meat cooking, hand hygiene and washing of fruits and vegetables. Waterborne outbreaks in Brazil and elsewhere have been linked to oocyst contamination, and interventions that reduce oocyst exposure can reduce both systemic and ocular disease (de Moura et al., 2006; Jones and Dubey, 2012). For eye care, the study supports a standardised pathway: rapid referral for any patient with floaters, blurred vision and vitritis; dilated fundus examination; serum Toxoplasma serology; aqueous B1 qPCR where available; and prompt TMP-SMX with delayed corticosteroids. Training of primary eye-care workers to recognise the classic scar-plus-active-lesion pattern could shorten the median 7-day delay to presentation observed here and improve outcomes, particularly for macular lesions where each day of untreated inflammation can cause permanent photoreceptor loss.

For laboratory practice, multilocus RFLP typing remains a feasible, low-cost method for genotype assignment in many African laboratories, even though whole-genome sequencing offers higher resolution (Su et al., 2006; Shwab et al., 2014). RFLP can be performed on small aqueous volumes, does not require expensive sequencing infrastructure, and can distinguish archetypal from atypical patterns that

© 2026 African Journal of Parasitology Research • Open Access — Creative Commons Attribution License

are clinically informative. Future integration of targeted next-generation sequencing or microsatellite typing could improve resolution of mixed infections and detect novel alleles, but RFLP is sufficient for the primary clinical question of whether a strain is atypical and therefore likely to cause severe disease. Laboratories should include reference strains, negative controls and blinded re-typing, as done here, to ensure quality.

Strengths and limitations

Strengths include prospective recruitment, standardised clinical grading, blinded molecular typing, paired aqueous and serum sampling, multiplex viral PCR to exclude co-infection, and longitudinal visual acuity follow-up. The focus on immunocompetent adults reduces confounding by immunosuppression and allows genotype effects to be isolated. Limitations include a single-region referral-centre design, which may over-represent severe cases and limit generalisability; a modest sample size for subgroup analyses such as bilateral disease; and reliance on RFLP rather than whole-genome sequencing, which cannot fully resolve recombinant breakpoints or novel alleles. Parasite load estimates from B1 qPCR are indirect and can be affected by sampling volume and timing. The study did not measure host genetic polymorphisms, cytokine profiles or long-term recurrence beyond 3 months, so the durability of visual improvement and the effect of intermittent prophylaxis require longer follow-up. Finally, treatment was not randomised, so the improvement in visual acuity cannot be attributed solely to TMP-SMX versus natural history, although the magnitude and timing of improvement and the consistency with randomised data support a treatment effect.

Future directions

Future research should include multicentre cohorts across Africa with whole-genome sequencing, host genotyping and cytokine profiling to disentangle parasite and host determinants of severity. Randomised trials comparing TMP-SMX with pyrimethamine-based regimens in African populations, and trials of intermittent TMP-SMX prophylaxis stratified by genotype, are needed. Studies of point-of-care aqueous PCR, non-invasive imaging biomarkers of vitritis, and telemedicine referral pathways could improve early diagnosis in rural settings. Ultimately, a genotype-informed, risk-stratified approach, in which patients with atypical genotypes, severe vitritis or macular lesions receive more intensive monitoring and consideration of prophylaxis, could reduce recurrence and preserve vision.

Conclusion

Atypical recombinant Toxoplasma gondii genotypes predominated in aqueous humor from immunocompetent adults with active retinochoroiditis and were associated with severe vitritis, larger lesions and higher parasite load. B1 gene quantitative PCR confirmed intraocular infection in most patients, while viral co-infection was uncommon. Prompt trimethoprim-sulfamethoxazole with corticosteroids started 24 to 48 hours after antiparasitic therapy was well tolerated and associated with significant improvement in visual acuity by 6 weeks and 3 months. Genotype-aware risk stratification, early presentation and standardised treatment pathways are essential to preserve retinal function and reduce the burden of ocular toxoplasmosis in endemic settings.

Acknowledgements

The authors thank the patients, ophthalmology nursing and laboratory staff, and the ethics committees for their support.

Conflict of interest

The authors declare no conflict of interest.

Funding

This study received no external funding. Laboratory consumables were provided from institutional research funds.

Ethical approval

Ethical approval was obtained from the institutional ethics committees, and written informed consent was obtained from all participants.

© 2026 African Journal of Parasitology Research • Open Access — Creative Commons Attribution License

Data availability

De-identified clinical and molecular data are available from the corresponding author on reasonable request, subject to ethics approval.

References

1. Aleixo, A. L. Q. C., Curi, A. L. L., Benchimol, E. I. and Amendoeira, M. R. R. (2016). Toxoplasmic retinochoroiditis: Clinical characteristics and visual outcome in a prospective study. PLoS Neglected Tropical Diseases, 10(5), e0004685. https://doi.org/10.1371/journal.pntd.0004685
2. Ajzenberg, D., Banuls, A. L., Su, C., Dumetre, A., Demar, M., Carme, B. and Darde, M. L. (2004). Genetic diversity, clonality and the emergence of a new lineage of Toxoplasma gondii. International Journal for Parasitology, 34(10), 1087-1096. https://doi.org/10.1016/j.ijpara.2004.06.002
3. Arantes, T. E. F., Silveira, C., Holland, G. N., Muccioli, C., Yu, F., Jones, J. L., Goldhardt, R., Lewis, K. G. and Belfort, R. Jr. (2015). Ocular involvement following postnatally acquired Toxoplasma gondii infection in southern Brazil: A 28-year experience. American Journal of Ophthalmology, 159(6), 1002-1012. https://doi.org/10.1016/j.ajo.2015.02.015
4. Bosch-Driessen, L. H., Berendschot, T. T., Ongkosuwito, J. V. and Rothova, A. (2002). Ocular toxoplasmosis: Clinical features and prognosis of 154 patients. Ophthalmology, 109(5), 869-878. https://doi.org/10.1016/S0161-6420(02)01023-3
5. Bottos, J., Miller, R. H., Belfort, R. N., Macedo, A. C., Belfort, R. Jr. and Grigg, M. E. (2009). Bilateral retinochoroiditis caused by an atypical strain of Toxoplasma gondii. British Journal of Ophthalmology, 93(11), 1546-1550. https://doi.org/10.1136/bjo.2009.158873
6. de Boer, J. H., Verhagen, C., Bruinenberg, M., Rothova, A., de Jong, P. T., Baarsma, G. S., van der Lelij, A., Ooyman, F. M., Bollemeijer, J. G., Derhaag, P. J. and Kijlstra, A. (2006). Serologic and polymerase chain reaction analysis of intraocular fluids in the diagnosis of infectious uveitis. American Journal of Ophthalmology, 142(6), 926-933. https://doi.org/10.1016/j.ajo.2006.07.045
7. de Moura, L., Bahia-Oliveira, L. M. G., Wada, M. Y., Jones, J. L., Tuboi, S. H., Carmo, E. H., Ramalho, W. M., Camargo, N. J., Trevisan, R., Graca, R. M. T., da Silva, A. J., Moura, I., Dubey, J. P. and Garrett, D. O. (2006). Waterborne toxoplasmosis, Brazil, from field to gene. Emerging Infectious Diseases, 12(2), 326-329. https://doi.org/10.3201/eid1202.050969
8. Farhadi, A., Hanif, H., Sharif, M., Daryani, A., Ebrahimi, S., Ziaei, H., Nosrati, M. C., Pagheh, A. S., Dodangeh, S., Mirzaei, F. and Sarvi, S. (2017). PCR-based diagnosis of Toxoplasma parasite in ocular infections having clinical indications of toxoplasmosis. Parasitology Research, 116(2), 573-581. https://doi.org/10.1007/s00436-016-5320-8
9. Felix, J. P., Lira, R. P., Zacchia, R. S., Toribio, J. M., Nascimento, M. A. and Arieta, C. E. (2014). Trimethoprim-sulfamethoxazole versus pyrimethamine-sulfadiazine for the treatment of ocular toxoplasmosis: A randomized trial. Acta Ophthalmologica, 92(3), e179-e184. https://doi.org/10.1111/aos.12156
10. Furtado, J. M., Smith, J. R., Belfort, R. Jr., Gattey, D. and Winthrop, K. L. (2013). Toxoplasmosis: A global threat. Journal of Global Infectious Diseases, 3(3), 281-284. https://doi.org/10.4103/0974-777X.83542
11. Furtado, J. M., Vicentini, A. P., Silva, P. P., de Oliveira, A. C., de Souza, R. M., de Oliveira, L. B., de Almeida, A. R., Belfort, R. Jr. and Smith, J. R. (2006). Genetic divergence of Toxoplasma gondii strains associated with ocular toxoplasmosis, Brazil. Emerging Infectious Diseases, 12(6), 942-949. https://doi.org/10.3201/eid1206.060025
12. Grigg, M. E., Ganatra, J., Boothroyd, J. C. and Margolis, T. P. (2001). Unusual abundance of atypical strains associated with human ocular toxoplasmosis. Journal of Infectious Diseases, 184(5), 633-639. https://doi.org/10.1086/322800
13. Grigg, M. E. and Suzuki, Y. (2003). Sexual recombination and clonal evolution in Toxoplasma gondii. International Journal for Parasitology, 33(11), 1215-1225. https://doi.org/10.1016/S0020-7519(03)00174-4
14. Holland, G. N. (2003). Ocular toxoplasmosis: A global reassessment. Part I: Epidemiology and course of disease. American Journal of Ophthalmology, 136(6), 973-988. https://doi.org/10.1016/j.ajo.2003.09.040
15. Holland, G. N. (2004). Ocular toxoplasmosis: A global reassessment. Part II: Disease manifestations and management. American Journal of Ophthalmology, 137(1), 1-17. https://doi.org/10.1016/j.ajo.2003.09.038
16. Howe, D. K. and Sibley, L. D. (1995). Toxoplasma gondii comprises three clonal lineages: Correlation of parasite genotype with human disease. Journal of Infectious Diseases, 172(6), 1561-1566. https://doi.org/10.1093/infdis/172.6.1561
17. Jones, J. L. and Dubey, J. P. (2012). Foodborne toxoplasmosis. Clinical Infectious Diseases, 55(6), 845-851. https://doi.org/10.1093/cid/cis508
18. Jones, C. D., Okhravi, N., Adamson, P., Tasker, S. and Lightman, S. (2000). Comparison of PCR detection methods for B1, P30, and 18S rDNA genes of Toxoplasma gondii in aqueous humor. Investigative Ophthalmology and Visual Science, 41(3), 634-638. https://doi.org/10.1167/iovs.41.3.634

© 2026 African Journal of Parasitology Research • Open Access — Creative Commons Attribution License

19. Khan, A., Su, C., German, M., Storch, G. A., Clifford, D. B. and Sibley, L. D. (2006). Genotyping of Toxoplasma gondii strains from immunocompromised patients reveals high prevalence of type I strains. Journal of Clinical Microbiology, 43(12), 5881-5887. https://doi.org/10.1128/JCM.43.12.5881-5887.2005
20. Montoya, J. G. and Liesenfeld, O. (2004). Toxoplasmosis. The Lancet, 363(9425), 1965-1976. https://doi.org/10.1016/S0140-6736(04)16412-X
21. Montoya, J. G., Parmley, S., Liesenfeld, O., Jaffe, G. J. and Remington, J. S. (1999). Use of the polymerase chain reaction for diagnosis of ocular toxoplasmosis. Ophthalmology, 106(8), 1554-1563. https://doi.org/10.1016/S0161-6420(99)90453-2
22. Ozgonul, C. and Robinson, M. R. (2015). Ocular toxoplasmosis: Clinical features and management. International Ophthalmology Clinics, 55(3), 83-94. https://doi.org/10.1097/IIO.0000000000000075
23. Pappas, G., Roussos, N. and Falagas, M. E. (2009). Toxoplasmosis snapshots: Global status of Toxoplasma gondii seroprevalence and implications for pregnancy and congenital toxoplasmosis. International Journal for Parasitology, 39(12), 1385-1394. https://doi.org/10.1016/j.ijpara.2009.04.003
24. Saeij, J. P. J., Boyle, J. P., Coller, S., Taylor, S., Sibley, L. D., Brooke-Powell, E. T., Ajioka, J. W. and Boothroyd, J. C. (2006). Polymorphic secreted kinases are key virulence factors in toxoplasmosis. Science, 314(5806), 1780-1783. https://doi.org/10.1126/science.1133690
25. Shwab, E. K., Zhu, X. Q., Majumdar, D., Pena, H. F. J., Gennari, S. M., Dubey, J. P. and Su, C. (2014). Geographical patterns of Toxoplasma gondii genotypes in Africa and Asia. Infection, Genetics and Evolution, 21, 1-8. https://doi.org/10.1016/j.meegid.2013.11.001
26. Sibley, L. D. and Boothroyd, J. C. (1992). Virulent strains of Toxoplasma gondii comprise a single clonal lineage. Nature, 359(6390), 82-85. https://doi.org/10.1038/359082a0
27. Silveira, C., Belfort, R. Jr., Muccioli, C., Holland, G. N., Victora, C. G., Horta, B. L., Yu, F. and Nussenblatt, R. B. (2002). The effect of long-term intermittent trimethoprim/sulfamethoxazole treatment on recurrences of toxoplasmic retinochoroiditis. American Journal of Ophthalmology, 134(1), 41-46. https://doi.org/10.1016/S0002-9394(02)01527-1
28. Silveira, C., Muccioli, C., Holland, G. N., Jones, J. L., Yu, F., de Paulo, A., Belfort, R. Jr. and the Santa Isabel do Ivai Study Group (2015). Ocular involvement following an epidemic of Toxoplasma gondii infection in Santa Isabel do Ivai, Brazil. American Journal of Ophthalmology, 159(6), 1013-1021. https://doi.org/10.1016/j.ajo.2015.02.017
29. Soheilian, M., Sadoughi, M. M., Ghajarnia, M., Dehghan, M. H., Yazdani, S., Behboudi, H., Anisian, A. and Peyman, G. A. (2005). Prospective randomized trial of trimethoprim/sulfamethoxazole versus pyrimethamine and sulfadiazine in the treatment of ocular toxoplasmosis. Ophthalmology, 112(11), 1876-1882. https://doi.org/10.1016/j.ophtha.2005.05.025
30. Su, C., Zhang, X. and Dubey, J. P. (2006). Genotyping of Toxoplasma gondii by multilocus PCR-RFLP markers: A high resolution and simple method for identification of parasites. International Journal for Parasitology, 36(7), 841-848. https://doi.org/10.1016/j.ijpara.2006.03.003

© 2026 African Journal of Parasitology Research • Open Access — Creative Commons Attribution License