

Full Length Research Paper

Amelioration of chronic cyclosporine A-induced nephrotoxicity by telmisartan in rats

Fadhil G. Al-Amran*, Najah R. Hadi, Talib H. Kamoona and Zahraa J. Kadhum

Department of Surgery, Box C-320, 12700 E 19th Avenue, Aurora, CO80045, Iraq.

Accepted 21 September, 2017

Nephrotoxicity is a major problem of Cyclosporine A (CsA) treatment, despite its beneficial role in organ transplantation and in a variety of immunologic disorders. This study was undertaken to investigate the potential renoprotective role of telmisartan in amelioration of chronic CsA induced nephrotoxicity. The rats were randomized into 4 equal groups. Group 1 received normal saline (control), group 2 received Cremophor EL and ethanol (CsA vehicle), group 3 received CsA 25 mg/kg/day s.c and group 4 received telmisartan 3 mg/kg/day orally in addition to CsA. The rats were pair fed with a standard chow diet throughout the experiment period (8 weeks). CsA nephrotoxicity was assessed in terms of increased S.Cr (from 0.52 ± 0.16 to 1.29 ± 0.20 mg/ml), blood urea (from 24.69 ± 1.89 to 75.88 ± 2.33 mg/ml) and serum K (from 3.43 ± 0.18 to 5.23 ± 0.43 meq/l). CsA also caused significant increase ($p < 0.01$) in MDA (from 0.74 ± 0.13 to 2.96 ± 0.43 nmol/mg protein) and significant decrease ($p < 0.01$) in GSH and catalase in renal tissue. Telmisartan failed to restore the altered renal functions. On the other hand, it causes a significant improvement in the histological changes including the tubulointerstitial fibrosis and arteriolopathy ($p < 0.01$). It also caused significant reduction ($p < 0.01$) in CsA-induced oxidative stress. These findings suggested that telmisartan has a promising renoprotective effect against chronic CsA induced nephrotoxicity.

Key words: Cyclosporine A, nephrotoxicity, oxidative stress, telmisartan.

INTRODUCTION

Cyclosporine A (CsA), an immunosuppressant drug, binds to cyclophilin to inhibit phosphatase calcineurin, and thereby prevents the dephosphorylation of nuclear factor of activated T-cells that is essential for synthesis of many lymphokine mediators, particularly IL-2. It is widely used to prevent rejection of organ transplants. Also it is used to treat autoimmune diseases like rheumatoid arthritis, psoriasis, atopic dermatitis, and nephrotic syndrome. One of the most important adverse effects that restrict the use of CsA is renal toxicity (Sweetman, 2007). The term CsA nephrotoxicity (CsAN) comprises two particular and very distinct forms of renal injury. CsA-induced acute nephrotoxicity is a hemodynamically mediated phenomenon, characterized by the absence of permanent structural changes and by the reversibility with decrease or discontinuation of the drug. Conversely, chronic CsAN is an insidious lesion associated with an

irreversible and progressive renal interstitial fibrosis, followed by important decrease in renal function (Cattaneo et al., 2004). Underlying renal insufficiency, intravascular volume depletion; age older than 60 years, excessive dose, and concomitant use with other nephrotoxic drugs or drugs that inhibit CsA metabolism by inhibiting CYP3A system are considered as risk factors for CsAN (Naughton, 2008).

Telmisartan is a nonpeptide antagonist of the AT₁ receptors. Signalling through the AT₁ receptor results in vasoconstriction and sodium reabsorption, and also promotes cellular growth, hypertrophy, activation of fibroblasts, and extracellular matrix deposition in the kidney (Sugiyama et al., 2005). Telmisartan exerts a variety of pleiotropic effects, including antioxidative, antiapoptotic, and anti-inflammatory effects (Sugiyama et al., 2005; Duan et al., 2009; Takahashi et al., 2007). It acts as a partial agonist of PPAR- (Benson et al., 2004). There is growing evidence that activators of PPAR- exert anti-inflammatory, anti-oxidative and anti-proliferative effects on vascular wall cells (Takano et al., 2004). Also by

*Corresponding author. E-mail: fadhil.al-amran@ucdenver.edu.

blocking the effects of angiotensin II (AngII), telmisartan will block AngII-mediated ROS generation (Sugiyama et al., 2005). ROS are involved in many of the AngII signalling pathways (Griendling and Ushio-Fukai, 2000). Telmisartan had protective effect in many animals model of renal injury (Sugiyama et al., 2005; Duan et al., 2009; Takahashi et al., 2007). Therefore, it may be a convenient renal- protective drug. This study was conducted to investigate the renoprotective role of telmisartan on amelioration of chronic CsAN.

MATERIALS AND METHODS

Animals

A total of 30 adult male albino Swiss rats aged 8 to 10 weeks with weight of 140 to 155 g, were obtained from Animal Resource Center, the Institute of Embryo Research and Treatment of Infertility, Al-Nahrain University. The animals were apparently healthy and they were housed in individual cages, at temperature controlled environment ($25 \pm 2^\circ\text{C}$) with ambient humidity. Lights were maintained on a 12 h light/dark cycle. The rats received standard chow diet with water. Rats in the study were maintained in accordance with the guidelines established by the Committee on the Care and Use of Laboratory Animals of the Institute of Laboratory Animal Resources, National Research Council.

Preparation of the drugs

CsA (Novartis pharma, Austria) was diluted with 0.9% saline in a ratio of (1:5). Telmisartan (Boehringer Ingelheim Pharma.) was suspended in (distilled water) D.W containing 0.5% carboxymethyl cellulose (CMC). CsA vehicle was prepared by mixing 2 part cremophor[®] EL with 1 part ethanol and diluted with 0.9% saline in the same ratio of CsA (González-Correa et al., 1996). The doses were prepared freshly every day.

Experimental groups

After one week acclimatization period, the rats were randomized into 4 groups each contain 6 rats and all types of treatments were continued for 8 weeks. Group 1 received normal saline s.c daily, group 2 received Cremophor EL and ethanol (CsA vehicle) s.c daily, group 3 received CsA 25 mg/kg/day s.c once daily (Lee et al., 1999; del Moral et al., 1997) and group 4 received telmisartan 3 mg/kg/day orally in addition to CsA (Takahashi et al., 2007).

The rats were allowed free access to standard rodent chow and water until the onset of injections. After that, the rats were allowed free access to water but with restricted access to food, except for the CsA only group which had free access to diet and water. The average daily food consumed by CsA only rats was used to pair-feed all other rats (Schwedler et al., 1999) in the following day (Shihab et al., 1996). This was done because food consumption reduced in CsA-treated animals and this might affect renal function measurement (Wang and Salahudeen, 1997). Body weight and the average daily food consumed by CsA-treated rats were recorded daily.

Collection and preparation of samples

After 24 h from the last injection, the rats were anesthetized with

phenobarbital 50 mg/kg s.c and blood was obtained by cardiac puncture. Each blood sample was divided into 2 parts. The first part was placed in a tube containing disodium EDTA (22 mg/ml) and used for determination of Hct percent and Hb by an automatic analyzer. The remaining blood was placed in a tube without anticoagulant and left for 30 min in room temperature and used to obtain serum through centrifugation at 3000 rpm for 10 min and then used for determination of blood urea, serum creatinine (S.Cr) and total serum protein (TSP) by Randox assay kits, while serum Na and K were determined by an electrolyte analyzer. Kidneys were quickly removed and the right kidney was rinsed with ice cold 0.9% saline to remove any RBCs or clots. It was decapsulated and dissected from the medulla. Then transported to the deep freezer and stored at -80°C to be used in oxidative stress measurement and in determination of tissue protein. The left kidney was fixed in 10% formalin for histopathological evaluation.

Measurement of oxidative stress parameters in renal cortex

10% tissues homogenates were prepared by homogenizing with 0.1 M phosphate buffered saline (PBS) (pH=7.4) for malondialdehyde (MDA) and tissue protein determination or with 50 mM potassium phosphate buffer (pH=7.0) for Glutathione (GSH) and catalase determination. MDA, GSH and catalase were measured by using commercial assay kits (BioAssay Systems, Hayward, CA, USA). Tissue protein was determined by modified Lowry method.

Histopathological evaluation of the kidney

The scoring system for histological findings was subdivided into three categories: tubular injury, interstitial inflammation and scarring, and arteriopathy (Shihab et al., 1996). Findings ascribed to tubular injury included vacuolization, tubular collapse. Features of interstitial inflammation were mononuclear infiltrates. The findings of scarring were matrix-rich expansion of the interstitium with distortion of the tubules. Renal arteriopathy in chronic CsAN was characterized by hyalinization and destruction of the afferent arterioles. A minimum of 20 fields at 40X magnification were assessed in each biopsy and graded semiquantitatively by a pathologist blinded to treatment groups. For tubular injury: 0 no tubular injury; 0.5 = <5% of tubules injured; 1 = 5 to 20%; 1.5 = 21 to 35%; 2 = 36 to 50%; 2.5 = 51 to 65% and 3 = > 65% of tubules injured.

Tubulointerstitial fibrosis (TIF) was estimated by counting the percentage of injured areas per field of cortex and medulla: 0 = normal interstitium; 0.5 = < 5% of areas injured; 1 = 5 to 20%; 1.5 = 21 to 35%; 2 = 36 to 50%; 2.5 = 51 to 65% and 3 = > 65% of areas injured. Hyalinosis was determined by counting the percentage of juxtaglomerular afferent arterioles with a minimum of 100 glomeruli per biopsy assessed: 0 = no arterioles injured; 0.5 = < 15% of arterioles injured; 1 = 15 to 30%; 1.5 = 31 to 45%; 2 = 46 to 60%; 2.5 = 61 to 75% and 3 = > 75% of arterioles injured.

Statistical analysis

Statistical analyses were performed using SPSS 10.0 for windows.Inc. Data were expressed as mean \pm SEM. Analysis of Variance (ANOVA) was used for the multiple comparisons among all groups followed by post- hoc tests using LSD method. The histopathological grading of lung changes is a non-normally distributed variable measured on an ordinal level of measurement; therefore non-parametric tests were used to assess the statistical significance involving this variable. The statistical significance of difference in total score between more than 2 groups was assessed by Kruskal-Wallis test, while Mann-Whitney U test was used for the

difference between 2 groups. In all tests, $p < 0.05$ was considered to be statistically significant.

RESULTS

Effect of telmisartan on body weight, hematological parameters and renal function

At the end of experiment, rats treated with CsA only showed a significant decrease in (body weight) B.W ($p < 0.01$), as compared to pair-fed vehicle group. Furthermore, subchronic CsA treatment resulted in significant increase ($p < 0.01$) in blood urea and S.Cr, as compared to vehicle group. Also, it resulted in significant increase ($p < 0.05$) in serum K, while, it led to insignificant changes in serum Na, TSP, Hb and Hct percent, as compared to vehicle group ($p > 0.05$). Significant differences ($p > 0.05$) between vehicle and normal saline (N.S)-treated groups were not observed in all parameters that have been studied. The addition of telmisartan to CsA treatment regimen did not improve ($p > 0.05$) body weight changes in CsA treated rats. Moreover, it failed to restore ($p > 0.05$) the altered renal function parameters in these rats (Table 1).

Effect of telmisartan on oxidative stress parameters

In comparison with vehicle group, CsA treatment resulted in significant increase in lipid peroxidation marker; the MDA by means of elevated TBARS levels in renal tissue ($p < 0.01$). Also it resulted in significant decrease ($p < 0.01$) in the antioxidant enzyme; catalase and in renal GSH content. Telmisartan combination treatment with CsA was found to be significantly ($p < 0.01$) reduced renal tissue MDA, and significantly ($p < 0.01$) increased GSH content and the catalase enzyme activity in CsA treated rats (Table 2).

Effect of telmisartan on renal histology

CsA treatment was associated with increase ($p < 0.01$) in histopathological scores including tubular injury, arteriopathy and TIF. Adding telmisartan to CsA treatment resulted in insignificant difference in tubular injury score as compared to CsA *per se* group ($p > 0.05$). While, it caused significant reduction in arteriopathy and TIF scores ($p < 0.01$) (Figure 1).

DISCUSSION

Nephrotoxicity is a major clinical problem of CsA treatment, despite its beneficial role in organ transplantation and in a variety of immunologic disorders. Although a number of mediators have been proposed to

account for CsAN, the precise mechanism remains unknown. The cumulative data suggest a role for ROS as one of the postulated mechanisms in the pathogenesis of CsAN. Furthermore, the effects of scavengers of ROS and antioxidants in amelioration of CsAN provide additional support for a role of ROS in CsAN (Wang and Salahudeen, 1995). As previously mentioned, telmisartan has pleiotropic effects, including antioxidative, antiapoptotic, and anti-inflammatory effects. Therefore, this study was designed to investigate the potential renoprotective role of telmisartan in amelioration of chronic CsAN.

At the end of the study we demonstrated that suchronic treatment with CsA resulted in significant decrease in body weight as compared to the pair-fed vehicle treated rats despite of using pair-feeding method between CsA treated rats and other rats. Pair-feeding is used in this study to exclude the effect of CsA on food intake. Where, CsA was reported to reduce food intake in rats (Wongmekiat and Thamprasert, 2005) and reduction in protein intake is known to exert a marked suppressive effect on glomerular filtration rate (GFR). CsA significantly impaired renal functions including S.Cr, blood urea and serum K, while, it caused insignificant changes in hematological parameters and TSP level. The hyperkalemia associated with CsAN has a multifactorial origin. It might be due to kidney failure, direct tubular toxicity, and inhibition of the synthesis of aldosterone by the adrenal gland (Mason, 1990; Ling and Eaton, 1993; Tumlin and Sands, 1993).

Concerning the effect of CsA on lipid peroxidation, it caused significant increase in renal tissue MDA. On the other hand, it caused significant decrease in the antioxidant status that is GSH and catalase enzyme activity. The molecular mechanisms responsible for enhancement of oxidative stress in renal tissue exposed to CsA are poorly understood. However, some authors have suggested a possible involvement of the metabolism of CsA by CYP450 (Burke and Whiting, 1986), glomerular synthesis of free radicals (Parra et al., 1998) and CsA-induced vasoconstriction, which leads to hypoxia-reoxygenation injury that leads to generation of free radicals (Zhong et al., 1998).

The effect of CsA on renal histology was demonstrated by the increments in histopathological parameters scores including tubular injury, arteriopathy and TIF. Chronic treatment with CsA vehicle; cremophor EL (CrEL) resulted in insignificant changes in all the studied parameters as compared to N.S-treated group. There is a controversy about the effect of this vehicle on the kidney. Most authors studying its effect suggested that it might play a role in the acute nephrotoxicity that seen during CsA infusion (Tibell et al., 1993). This may be explained by the well known anaphylactic reaction to CrEL when given intravenously (Sweetman, 2007). Indeed, in this study CrEL was given to the vehicle group subcutaneously and the acute effects of CsA or its vehicle on

Table 1. Body weights, renal function parameters and hematological parameters in different study groups at the end of the experiment.

Parameter	Study group			
	N.S	Vehicle	CsA	CsA+Telmisartan
Body weight (g)	167.3±3.0	169.6±4.1	151.6±2.5*	154.8±3.9 ^{ns}
S.Cr mg/ml	0.52± 0.16	0.57± 0.18	1.29 ± 0.20*	0.97 ± 0.17 ^{ns}
B.U. mg/ml	24.69 ± 1.89	29.02 ± 1.5	75.88± 2.33*	78.20 ± 4.7 ^{ns}
Hct%	43.15 ± 1.35	39.49 ± 1.83	41.24 ± 2.51	41.93 ± 1.29 ^{ns}
Hb g/ml	13.58 ± 0.60	11.75 ± 0.73	12.25 ± 0.87	12.91 ± 1.15 ^{ns}
Serum Na meq/l	135.83 ± 5.2	138.33 ± 4.1	138.16 ± 7.1	141.66 ± 3.6 ^{ns}
Serum K meq/l	3.43 ± 0.18	3.61 ± 0.33	5.23 ± 0.43**	4.86 ± 0.79 ^{ns}
TSP g/ml	5.41 ± 0.26	4.9 ± 0.25	5.16 ± 0.27	5.5 ± 0.44 ^{ns}

*p<0.01 vs vehicle group. **p<0.05 vs vehicle group. ns: not significant vs CsA group at 0.05 level.

Table 2. Oxidative stress parameters in renal tissue for different study groups at the end of the experiment.

Parameter	Study group			
	N.S	Vehicle	CsA	CsA + Telmisartan
MDA nmol/mg protein	0.74 ± 0.13	0.92 ± 0.17	2.96 ± 0.43*	1.31 ± 0.255 [#]
Catalase activity U/mg protein	237.8 ± 14.1	226.1 ± 12.7	101.3 ± 6.34*	184.67±17.61 [#]
GSH mol/mg protein	17.72 ± 1.42	17.05 ± 1.57	5.13 ± 1.44*	15.90 ± 2.29 [#]

*p<0.01 vs vehicle group. [#]p<0.01 vs CsA group.

Table 3. Mean scores of histopathological parameters for different study groups at the end of the experiment.

Histopathological parameter	Study groups			
	N.S	Vehicle	CsA	CsA+Telmisartan
Tubular injury score	0.08 ± 0.02	0.166 ± 0.1	1.58 ± 0.12*	1.25 ± 0.21 ^{ns}
Tubulointerstitial fibrosis score	0.0 ± 0.0	0.0 ± 0.0	1.75 ± 0.11*	0.75 ± 0.11 [#]
Arteriopathy score	0.0 ± 0.0	0.08± 0.02	1.833 ± 0.16*	0.667 ± 0.1 [#]

*p<0.01 vs vehicle group. [#]p<0.01 vs CsA group. ns: not significant vs CsA group at 0.05 level.

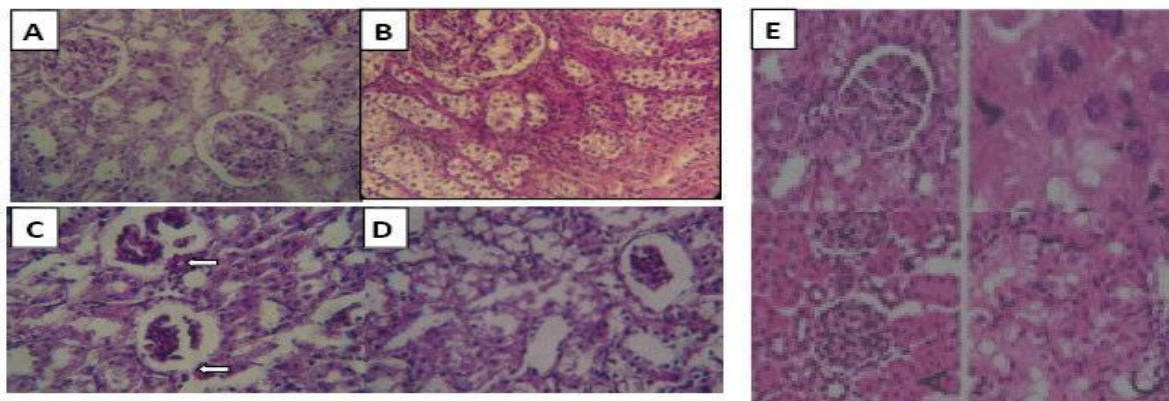


Figure 1. Representative photomicrograph shows the histopathological changes in CsA treated rats for 8 weeks. A: normal appearance of kidney section. B: CsA induced interstitial fibrosis, nflammatory cell infiltration, and tubular atrophy. C: CsA induced the typical afferent arteriopathy (Arteriolar hyalinosis as shown by arrows). D: CsA induced tubular injury including vacuolization, tubular collapse and loss of tubular epithelium. E: Telmisartan+CsA kidney section; PAS staining, original magnification: x40 (Table 3).

the kidney were not studied because of the difficulties in multiple blood sampling from rats.

The absence of significant effect of CrEL on oxidative stress parameters in renal tissue might be explained by the characteristic properties of this vehicle, where, (cremophor EL) CrEL has an extremely low volume of distribution, implying that its tissue delivery is probably insignificant (Gelderblom et al., 2001). It has a pharmacokinetic selectivity for the central blood/bone marrow compartment. This may be the cause for lack of *in vivo* effect on the tissue (Sparreboom et al., 1996), and in support with this observation, Sparreboom et al. (1996) demonstrated that CrEL levels in normal and tumor tissue were not detectable in mice (Sparreboom et al., (1996). Concerning the effect of telmisartan on CsA treatment, it failed to restore the altered renal functions including S.Cr, blood urea and serum K. This may be explained by the paradoxical effects of ARBs on renal function (Goodfriend et al., 1996; Matsukawa and Ichikawa, 1997). They reduced proteinuria and improved morbidity and mortality in diabetic nephropathy. On the other hand, in states of low fixed RBF, they could worsen renal function and even precipitate acute renal failure (Goodfriend et al., 1996; Matsukawa and Ichikawa, 1997) . Furthermore, CsA had a direct vasoconstrictive effect on renal artery and it reduced RBF and it had been shown to impair renal autoregulatory mechanisms.

Telmisartan did not improve CsA induced hyperkalemia. However, it did not lead to worsening of it. Gillum et al. (1990) observed that enalapril co-treatment with CsA led to worsening of serum K in a chronic model of CsAN in rats (Gillum and Truong (1990). This may be explained by the observation of Schmidt et al. (2001) who studied the difference between the effect of angiotensin-converting enzyme inhibitors (ACE-I) and ARBs on potassium homeostasis in renal transplant recipients treated with CsA. They found that administration of ACE-I led to exacerbation of hyperkalaemia through reduction of aldosterone production. While the selective ARB; losartan caused insignificant elevation in serum K. They explained the difference between the two drugs on K homeostasis by the degree of renin angiotensin system (RAS) blocked which seems to be less marked with ARB (Schmidt et al., 2001).

Reduction in CsA-induced oxidative stress by telmisartan is evident by the decrease in renal tissue MDA and the increase in GSH and catalase enzyme. This shows a potential protective effect of telmisartan against renal oxidative damage in CsA-treated rats. A reasonable explanation is that telmisartan acts as an antioxidant and this may be in part by blocking the effects of AngII, which will in turn block AngII-mediated ROS generation (Griendling and Ushio-Fukai, 2000). Reduction in ROS generation will decrease lipid peroxidation and conserve the endogenous antioxidants.

Telmisartan did not significantly improve CsA-induced tubular injury. This result may be explained by the direct

toxic effects of CsA on the renal proximal tubular epithelial cell and it induced apoptosis in low doses whereas high doses induced necrosis. Where, Healy et al. (1998) observed that DNA is a vital target for CsA injury and the mechanism of cell death induced by CsA in the proximal tubular cells is dose dependent (Healy et al., 1998). Improvement in the histological changes including TIF and arteriopathy was occurred through telmisartan co-treatment. The protective role of telmisartan against arteriopathy might be due to RAS blockade (Young et al., 1995) . Indeed arteriopathy occurs in sites where the renin is markedly stimulated. This suggests that stimulation of renin may also lead to a local generation of AngII through the presence of ACE and local angiotensinogen which lead to the subsequent AngII-mediated injury at these sites (Pichler et al., 1995). The observed effect of telmisartan on TIF might be explained by the crucial role of AngII in the development of chronic CsAN.

Johnson et al. (1992) observed that infusion of AngII provoked histological changes in rat kidneys similar to those observed in CsAN. Kagami et al. (1994) had demonstrated a link between AngII and TGF- by showing that AngII-stimulation of extracellular matrix protein (ECM) protein synthesis in rat glomerular mesangial cells is mediated by both an increase in transforming growth factor beta (TGF-) synthesis and an increase in the conversion from latent to active TGF- . Shihab et al. (1996) proposed that TGF- is a key fibrogenic cytokine involved in the development of interstitial fibrosis by enhancing ECM deposition and inhibiting its degradation. Other possible explanation that (angiotensin receptors blocker) ARBs blocks the effect of AngII on triggering of intrarenal innate immune response which might be responsible for the development of inflammation and fibrosis in chronic CsAN (Ahn et al., 2007). Recently Yoon et al. (2010) suggested that the protective effect of ARBs was through the inhibition of ageing process in the kidney by blocking the effect of AngII on the suppression of the anti-ageing gene (Klotho gene) in the kidney and by decreasing the oxidative stress (Yoon et al., 2011). The protective effect of telmisartan on TIF was also observed by Cibulskyte et al. (2007) in a model of chronic CsAN in pigs. Regarding the relationship between renal function and structure in chronic CsAN, the dissociation between renal functional and architectural damage in the chronic CsAN model had been observed by other investigators, where Burdmann et al. (1995) concluded that the pathogenesis of chronic CsAN might be related to a direct stimulatory effect of CsA on renal tissue scarring processes independent on CsA and AngII-induced vasoconstriction and it can be dissociated from those causing glomerular and tubular dysfunction (Burdmann et al., 1995). Other authors observed this effect like Ahn et al. (2007). These findings suggested that telmisartan has a promising reno-protective effect against chronic CsAN.

REFERENCES

- Ahn KO, Lim SW, Li C, Yang HJ, Ghee JY, Kim JY (2007). Influence of angiotensin II on expression of toll-like receptor 2 and maturation of dendritic cells in chronic cyclosporine nephropathy. *Trans.*, 83(7): 938-47.
- Benson SC, Pershadsingh HA, Ho CI, Chittiboyina A, Desai P, Pravenec M, Qi N (2004). Identification of telmisartan as a unique angiotensin II receptor antagonist with selective PPAR gamma-modulating activity. *Hypertension*. 43(5): 993-1002.
- Burdmann EA, Andoh TF, Nast CC, Evan A, Connors BA, Coffman TM (1995). Prevention of experimental cyclosporin-induced interstitial fibrosis by losartan and enalapril. *Am. J. Physiol.*, 4Pt 2: F491-9.
- Burke MD, Whiting PH (1986). The role of drug metabolism in cyclosporine A nephrotoxicity. *Clin Nephrol* 25:S111-S116.
- Cattaneo D, Perico N, Gaspari F, Remuzzi G (2004). Nephrotoxic aspects of cyclosporine. *Transplant Proc.* 234S-239S.
- Cibulskyte D, Pedersen M, Hørlyck A, Marcussen N, Hansen HE, Frøkiaer J (2007). Telmisartan attenuates chronic ciclosporin A nephrotoxicity in a pig model. *Nephrol. Dial Trans.*, 22(2): 369-75.
- del Moral RG, Andujar M, Ramirez C, Gómez-Morales M, Masseroli M, Aguilar M (1997). Chronic cyclosporin A nephrotoxicity, P-glycoprotein overexpression, and relationships with intrarenal angiotensin II deposits. *Am. J. Pathol.*, 151(6): 1705-14.
- Duan SB, Wang YH, Liu FY, Xu XQ, Wang P, Zou Q (2009). The protective role of telmisartan against nephrotoxicity induced by X-ray contrast media in rat model. *Acta. Radiol.*, (7): 754-9.
- Gelderblom H, Verweij J, Nooter K, Sparreboom A (2001). Cremophor EL: the drawbacks and advantages of vehicle selection for drug formulation. *Eur. J. Cancer*, 37(13): 1590-8.
- Gillum DM, Truong L (1990). Effects of chronic volume expansion and enalapril on chronic cyclosporine nephropathy. *Am. J. Physiol.*, 4Pt 2:F934-9.
- González-Correa JA, De La Cruz JP, Lucena MI, Sánchez CF (1996). Effect of cyclosporin A on platelet aggregation and thromboxane/prostacyclin balance in a model of extrahepatic cholestasis in the rat. *Thromb Res.*, 81(3): 367-81.
- Goodfriend TL, Elliott ME, Catt KJ (1996). Angiotensin receptors and their antagonist. *N. Engl. J. Med.*, 334: 1649-1654.
- Griendling KK, Ushio-Fukai M (2000). Reactive oxygen species as mediators of angiotensin II signaling. *Regul. Pept.*, 91: 21-27.
- Healy E, Dempsey M, Lally C, Ryan MP (1998). Apoptosis and necrosis: mechanisms of cell death induced by cyclosporine A in a renal proximal tubular cell line. *Kidney Int.*, 54(6): 1955-66.
- Johnson RJ, Alpers CE, Yoshimura A, Lombardi D, Pritzl P, Floege J, Schwartz SM (1992). Renal injury from angiotensin II-mediated hypertension. *Hypertension*. 19(5): 464-74.
- Kagami S, Border WA, Miller DE, Noble NA (1994). Angiotensin II stimulates extracellular matrix protein synthesis through induction of transforming growth factor- α expression in rat glomerular mesangial cells. *J. Clin. Invest.*, 93: 2431-2437.
- Lee SK, Park JY, Yu ES, Yang WS, Kim SB, Park SK (1999). Individual or combined effects of enalapril and verapamil on chronic cyclosporine nephrotoxicity in rats. *J. Korean Med. Sci.*, 14(6): 653-8.
- Ling BN, Eaton DC (1993). Cyclosporin A inhibits apical secretory K⁺ channels in rabbit cortical collecting tubule principal cells. *Kidney Int.*, 44: 974.
- Mason J (1990). The pathophysiology of Sandimmune (cyclosporine) in man and animals. *Pediatr. Nephrol.*, 4: 554.
- Matsukawa T, Ichikawa I (1997). Biological functions of angiotensin and its receptors. *Ann. Rev. Physiol.* 59, 395-412.
- Naughton CA. Drug-induced nephrotoxicity. *Am. Fam. Phys.*, 78(6): 743-50.
- Parra T, de Arriba G, Arribas I, Perez de Lema G, Rodriguez-Puyol D, Rodriguez-Puyol M (1998). Cyclosporine A nephrotoxicity: role of thromboxane and reactive oxygen species. 2(5): 323-330.
- Pichler RH, Franceschini N, Young BA, Hugo C, Andoh TF, Burdmann EA (1995). Pathogenesis of cyclosporine nephropathy: roles of angiotensin II and osteopontin. *J. Am. Soc. Nephrol.*, 6(4): 1186-96.
- Schmidt A, Gruber U, Böhmig G, Köller E, Mayer G (2001). The effect of ACE inhibitor and angiotensin II receptor antagonist therapy on serum uric acid levels and potassium homeostasis in hypertensive renal transplant recipients treated with CsA. *Nephrol. Dial Trans.*, 16(5): 1034-7.
- Schwedler SB, Bobadilla N, Striker LJ, Vaamonde CA, Herrera-Acosta J, Striker GE (1999). Pentosan polysulfate treatment reduces cyclosporine-induced nephropathy in salt-depleted rats. *Trans.*, 68(10): 1583-8.
- Shihab FS, Andoh TF, Tanner AM, Noble NA, Border WA, Franceschini N (1996). Role of transforming growth factor-1 in experimental chronic cyclosporine nephropathy. *Kidney Int.*, 49(4): 1141-1151.
- Sparreboom A, van Tellingen O, Nooijen WJ, Beijnen JH (1996). Nonlinear murine pharmacokinetics of paclitaxel results from the pharmaceutical vehicle Cremophor EL. *Cancer Res.*, 56: 2112-2115.
- Sparreboom A, Verweij J, van der Burg ME, Loos WJ, Brouwer E, Viganò L (1998). Disposition of Cremophor EL in humans limits the potential for modulation of the multidrug resistance phenotype in vivo. *Clin. Cancer Res.*, 4(8): 1937-42.
- Sugiyama H, Kobayashi M, Wang DH, Sunami R, Maeshima Y, Yamasaki Y (2005). Telmisartan inhibits both oxidative stress and renal fibrosis after unilateral ureteral obstruction in acatalasemic mice. *Nephrol. Dial Trans.*, 20(12): 2670-80.
- Sweetman SC (2007). *The Complete Drug Reference*. London Pharmaceutical Press. 35th ed.
- Takahashi T, Ono H, Ono Y, Ishimitsu T, Matsuoka H (2007). Combination therapy with telmisartan and spironolactone alleviates L-NAME exacerbated nephrosclerosis with an increase in PPAR-gamma and decrease in TGF-beta(1). *Int. Heart. J.*, 48(5): 637-47.
- Takano H, Hasegawa H, Zou Y, Komuro I (2004). Pleiotropic actions of PPAR gamma activators thiazolidinediones in cardiovascular diseases. *Curr. Pharm.*, 10: 2779-86.
- Tibell A, Larsson M, Alvestrand A (1993). Dissolving intravenous cyclosporin A in a fat emulsion carrier prevents acute renal side effects in the rat. *Trans. Int.*, 6(2):69-72.
- Tumlin JA, Sands JM (1993). Nephron segment-specific inhibition of Na⁺/K⁺ (+)-ATPase activity by cyclosporin A. *Kidney Int.*, 43: 246.
- Wang C, Salahudeen AK (1997). Lipid peroxidation accompanies cyclosporine nephrotoxicity: Effects of vitamin E. *Kidney Int.*, 47: 927-934.
- Wongmekiat O, Thamprasert K (2005). Investigating the protective effects of aged garlic extract on cyclosporin-induced nephrotoxicity in rats. *Fundam. Clin. Pharmacol.*, 19(5): 555-62.
- Yoon HE, Ghee JY, Piao S, Song JH, Han DH, Kim S (2011). Angiotensin II blockade upregulates the expression of Klotho the anti-ageing gene, in an experimental model of chronic cyclosporine nephropathy. *Nephrol Dial Transplant*.
- Young BA, Burdmann EA, Johnson RJ, Andoh T, Bennett WM, Couser WG (1995). Cyclosporine A induced arteriopathy in a rat model of chronic cyclosporine nephropathy. *Kidney Int.*, 48: 431-438.
- Zhong Z, Arteel GE, Connor HD, Yin M, Frankenberg MV, Stachlewitz RF (1998). Cyclosporin A increases hypoxia and free radical production in rat kidneys: prevention by dietary glycine. *Am. J. Physiol.*, 4 Pt(2): F595-604.