

## Case Report

# Lung abscess caused by *Mycobacterium tuberculosis* in a child

\*Swami Nath Kapoor, Satyajit K. O. and Salman Akshay

Department of Pediatrics, Faculty of Medicine, Central University of Haryana, Mahendragarh, India.

Accepted 19 October, 2015

***Mycobacterium tuberculosis* is a common cause of pulmonary morbidity and mortality in children. We report a seven month old unimmunized child admitted with complaints of cough and fever for fifteen days. Investigations revealed a large cavity in the right lung. Chest computed tomography scan revealed an abscess in the right upper lobe along with multiple necrotic lymph nodes. Gastric aspirates were positive for acid fast bacilli. However, children younger than five years old may develop disseminated TB before the Tubercular Skin Tests result becomes positive. As such, a very high index of suspicion must be adopted when pediatric patients have a contact history.**

**Key words:** Lung Abscess, *Mycobacterium tuberculosis*, Infant.

## INTRODUCTION

Lung abscess are thick walled cavities that contain purulent infection and are uncommon in childhood. They usually result due to aspiration of organisms. Anaerobes are most commonly implicated in the etiology of lung abscess (Brook and Finegold, 1979). Based on the fact that lung abscess due to *M. tuberculosis* is uncommon in children (Vijayasekaran et al., 1994), to the best of our knowledge, the first case of lung abscess in an infant caused by *M. tuberculosis* in English literature is reported in this study.

## Case report

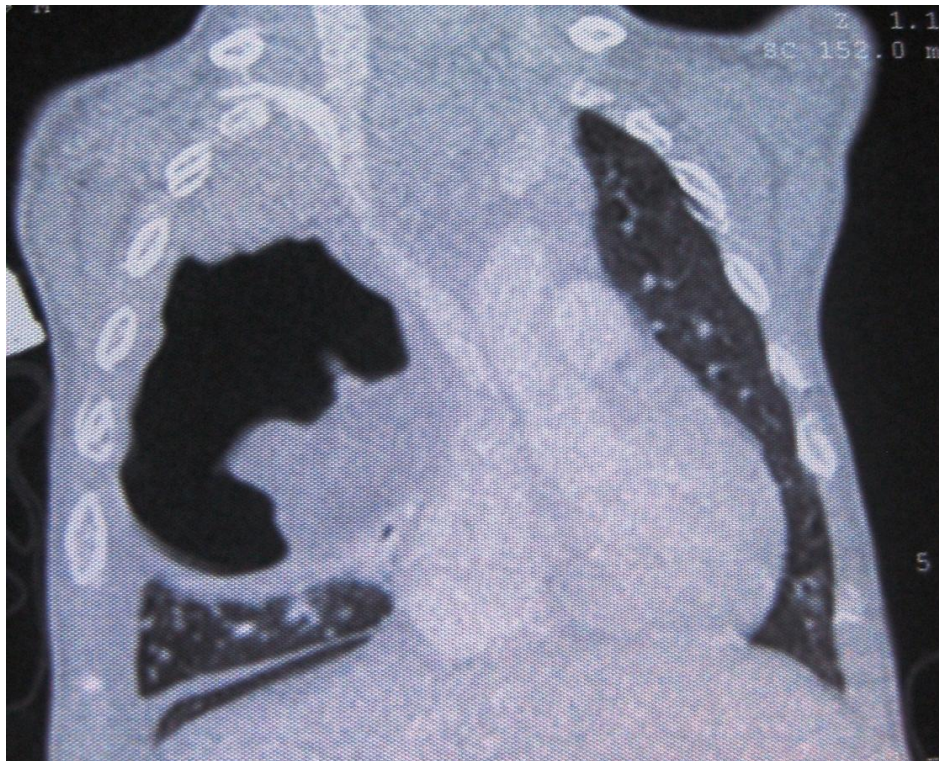
A seven month old boy was presented to the emergency room with complaints of daily, low to moderate grade

fever for over one month. He also had cough with gradual increase in respiratory distress for 15 days prior to presentation. The child had been normal before this illness.

The child was delivered at home at term gestation to a 33 years multigravida mother. Birth weight was not documented but he was of average weight according to the mother. The child was healthy till the age of 6 months. He was developmentally normal and was on mixed feeding since birth. No solid foods were introduced up till now and received only oral polio immunization. He had three elder siblings who are alive and apparently healthy. There was a family history of death of a 10 years old sibling three months back who was diagnosed to have tuberculosis, although no records could be traced.

At admission, his weight was 4 kg (weight for age; -5.82 S.D), length was 63.5 cm (length for age -2.79 S.D) and weight for length was -6.32 S.D. His pulse rate was 118 per minute, respiratory rate was 54 per minute with mild respiratory distress. There was no cyanosis,

\*Corresponding author. E-mail: [swami.nath@yahoo.com](mailto:swami.nath@yahoo.com)



**Figure 1.** Computed tomography (CT) scan of the chest.

clubbing or significant lymphadenopathy and also, no BCG scar mark. On chest auscultation, air entry was found to be reduced on the right side. There was hepatomegaly of 5 cm below the costal margin in the mid clavicular line and splenomegaly of 3 cm along its long axis. Neurological examination was normal apart from mild irritability.

Furthermore, treatment began with the administration of intravenous antibiotics (ceftriaxone and vancomycin), supplemental oxygen, along with other supportive treatment. His investigations revealed a Hemoglobin of 10.4 g/dL, total leukocyte count of  $16 \times 10^9$  /L with 67% polymorphs and 30% lymphocytes. Serum biochemistry was normal and his blood culture was sterile. Chest X ray showed a large cavitary lesion in the right upper lung field. Mantoux test was positive with 17 x 10 mm induration after 72 h. Possibility of necrotizing pneumonia was kept and the child was shifted to intensive care unit for monitoring and treatment (Figure 1).

CECT of the chest showed a large size of 12 cm thick walled cavitary lesion with air fluid level and necrotic residual lung parenchyma within right upper lobe. In addition, consolidation was seen involving the posterobasal segment of right and left lower lobes. There were multiple conglomerate necrotic lymph nodes with largest measuring 2 x 1.7 cm in almost all compartments of the mediastinum with sparing of pretracheal and left hilar regions. Bilateral pleural was also found.

In view of history of possible contact with tuberculosis, hepato-splenomegaly, positive mantoux test and necrotic mediastinal adenopathy, a further work-up for tuberculosis, were done. His gastric aspirates were sent for acid fast staining. One of the gastric aspirates was positive for acid fast bacilli. HIV serology was done and it was nonreactive. Contact survey was done and his parents were screened. They did not have any evidence of tuberculosis. Siblings were not brought by the parents to the hospital for evaluation.

Empirical intravenous antibiotics were stopped and anti-tubercular treatment began with four drug regimen (Isoniazid, Rifampicin, Ethambutol and Pyrazinamide). The child improved dramatically with subsidence of fever and improvement in appetite. He was subsequently discharged and became healthy on follow up. The child gained 1 kg weight on first follow up visit after one month and the lung cavity healed almost after two months of therapy.

## DISCUSSION

Lung abscess are thick walled cavities that contain purulent infection and result from liquefactive necrosis in the lung parenchyma. It is also defined as a circumscribed area of necrosis of 2 cm or more in diameter, they are usually caused by anaerobes, gram positive organisms (*Staphylococcus aureus*, *streptococ-*

us) or gram negative bacilli (Bartlett, 1993). It is probably arbitrary to designate larger cavities by the term lung abscesses, and smaller, multiple cavities with similar histologic appearance by the term necrotizing pneumonia. After the liquefactive necrotic material empties through the bronchus, a necrotic cavity containing air fluid level is created. The most common sites of lung abscess formation are the most frequent destinations of aspirated material (that is, those most dependent in the recumbent position: the right and left upper lobes and the apical segments of both lower lobes). When periodontal disease is present, the potential for lower respiratory tract infections with aspiration is increased because these children have more oropharyngeal organisms. A review of several series of children with lung abscesses suggested that occurrence in the right lung was more frequent (about 70%) and that although any lobe may be involved, the upper, middle, and lower lobes accounted for about 40, 20, and 40%, respectively, of right-sided lung abscess in children.

Pulmonary TB in children can range from an asymptomatic primary infection to a progressive primary TB. Progression of the primary infectious complex may lead to enlargement of hilar and mediastinal lymph nodes with resultant bronchial collapse. Progressive primary TB, which is considered to be a serious form of the disease, may develop when the primary focus cavitates and bacteria spread through contiguous bronchi (Vijayasekaran et al., 1994).

Tuberculosis disease should be suspected if the child has been exposed to a contagious source. Unfortunately, children younger than five years old may develop disseminated TB before the Tubercular Skin Tests result becomes positive. Thus, a very high index of suspicion must be adopted when pediatric patients have a contact history.

## REFERENCES

- Bartlett JG (1993). Anaerobic bacterial infections of the lung and pleural space. *Clin. Infect. Dis.*, 16(4): S248-255.
- Brook I, Finegold SM (1979). Bacteriology and therapy of lung abscess in children. *J. Pediatr.*, 94: 10-12.
- Vijayasekaran D, Selvakumar, P Balachandran A, Elizabeth J, Subramanyam L, Somu N (1994). Pulmonary cavitary tuberculosis in children. *Indian Pediatr.*, 31: 1074-1078.