

Case Report

Chronic Uterine Inversion: An Uncommon Presentation of Uterine Leiomyosarcoma

Rekha Sachan^{1*}, Pooja Gupta¹ and ML Patel²¹Department of Obstetrics and Gynaecology, CSM Medical University, Lucknow, India.²Department of Medicine, CSM Medical University, Lucknow, India.

Accepted 22 November, 2022

Sarcomatous change in uterine fibroid is termed leiomyosarcoma. The tumor originates from smooth muscle cells and is rare, accounting for 2 to 5% of all uterine malignancies. The said patient had the history of irregular bleeding, but not typical menorrhagia, which is the usual presentation in this tumor. A 40 year old, P₄₊₀ women of North Indian origin, was admitted with huge polypoidal fungating mass with bosselated surface and variegated mass protruding from introitus consistently. It was 12 ×10 cm in size with fundal cuping and cervical rim around the mass, which indicates inversion of the uterus. Total abdominal hysterectomy with bilateral salpingoophorectomy and bladder repair was done via abdomino-perineal route and the histopathology confirmed the diagnosis of leiomyosarcoma. Because of their rarity, uterine sarcomas are not recommended for routine screening. Surgery is the only treatment modality of leiomyosarcoma and prognosis depends upon the stage of the cancer.

Key words: Leiomyosarcoma, inversion, hysterectomy.

INTRODUCTION

Leiomyosarcomas are rare and aggressive form of uterine cancer (Melona et al., 2008). Compared to the more common endometrial carcinomas, uterine sarcomas behave more aggressively and are associated with a poorer prognosis. It arises from smooth muscle of the uterus and accounts for 2 to 5% of all uterine malignancies (Bergman et al., 2000). We report an original case of an unusual presentation of this rare tumor.

PRESENTATION OF THE CASE

A 40 years old Para₄₊₀ postmenopausal lady was presented to our OPD with the chief complaints of something coming out of vagina for the past 6 months with low grade fever and discharge per vagina. The patient was apparently asymptomatic 4 years back when she had undergone myomectomy for bleeding uterine

fibroid at a private hospital. Since previous records were not available, the site size and histopathology of previous fibroid was not known.

Examination

On examination, mild pallor was present and pulse rate was 100 beats/min and blood pressure was 120/70 mmHg. Local examination revealed a huge unhealthy looking polypoidal fungating mass of about 10 to 12 cm in size, smeared with thick foul smelling discharge coming out of introitus. Per vaginum examination revealed the same mass was present in the vagina, but actually originating from inside the cervical os, with the cervical rim felt all around it.

On bimanual examination fundal cupping was present. The mass firm to hard in consistency with irregular surface and it bled on touch. Exact uterine size could not be assessed due to huge size of the mass (Figure 1). A strong suspicion of chronic uterine inversion with probable recurrence of uterine fibroid was made.

*Corresponding author. E-mail: drrekhasachan@gmail.com.

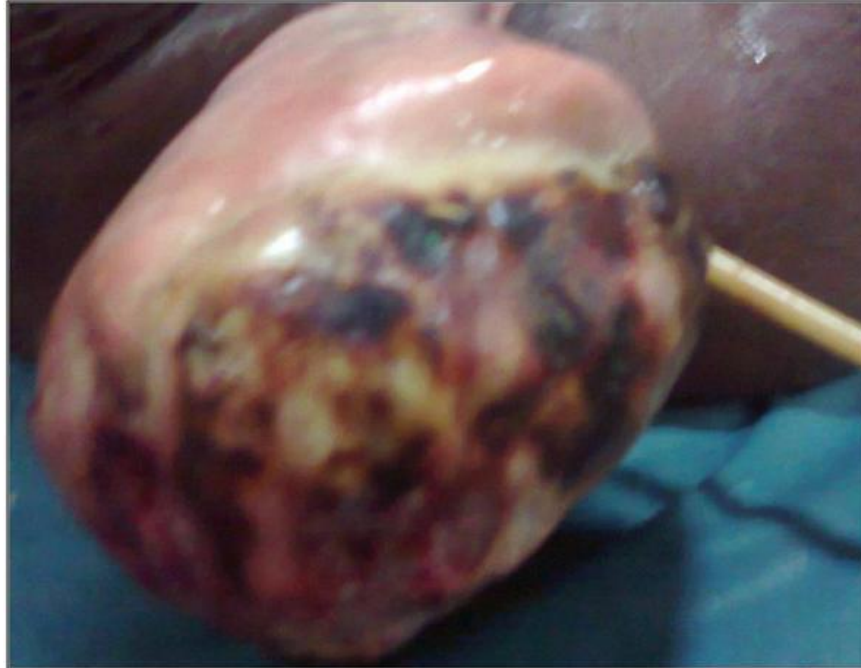

Figure 1. Inversion of uterus with fungating polypoidal growth protruding out of introitus.

Investigation

The patient had anemia with Hb% at 8 gm/dl. Serum chemistry showed liver and kidney function to be normal. Ultrasonography revealed empty uterine fossa with bilateral hydroureteronephrosis, which was further confirmed by Intravenous Pyelography. Viral markers (HbsAg, HIV, and HCV) were negative. Urine culture was sterile and the blood (sugar fasting and postprandial) was within normal limits. The chest x-ray and EKG were unremarkable.

Management

The patient was planned for simultaneous retrograde vaginal and abdominal resection of mass. Intraoperatively, a vague mass was seen arising from lower portion of pelvis extending into vagina, which was densely adhered to the posterior surface of the bladder. In the process of removal of adhesion, small rent occurred in bladder, which was followed by bilateral ureteric catheterization and repair of bladder. Resection of the mass both by abdominal and vaginal route then followed. Ovaries and tubes could not be visualized clearly due to severe distortion of anatomy.

Pathology

Histopathology shows an infiltrative malignant smooth

muscle tumour disposed in intersecting fascicles with occasional whirling and palisading. The individual tumour cells are pleomorphic with high nucleo cytoplasmic ratio, oval to elongated blunt ended nuclei, fibrillary eosinophilic cytoplasm. Fair numbers of a typical mitoses are seen. Adjacent areas show extensive coagulative necrosis and haemorrhage, suggestive of leiomyosarcoma of uterus as shown in Figure 2.

Follow up

The patient was followed in the cancer clinic of institute monthly (for 3 months) by vaginal cytology and was negative for malignancy.

DISCUSSION

Uterine sarcomas are rare hence they are not included in routine screening. The incidence of sarcoma is 1 to 2% in postmenopausal women (Wickerham et al., 2002). Abnormal vaginal bleeding and pelvic or abdominal pain are the most frequent presenting symptoms. The pattern of bleeding ranges from spotting to menorrhagia and is often associated with foul-smell and vaginal discharge. Weight loss, weakness, lethargy, and fever are less common symptoms (Van Dinh and Woodruff, 1982; Barter et al., 1985; Schwartz et al., 1985). Our patient did not have any history of genital bleeding, which is the

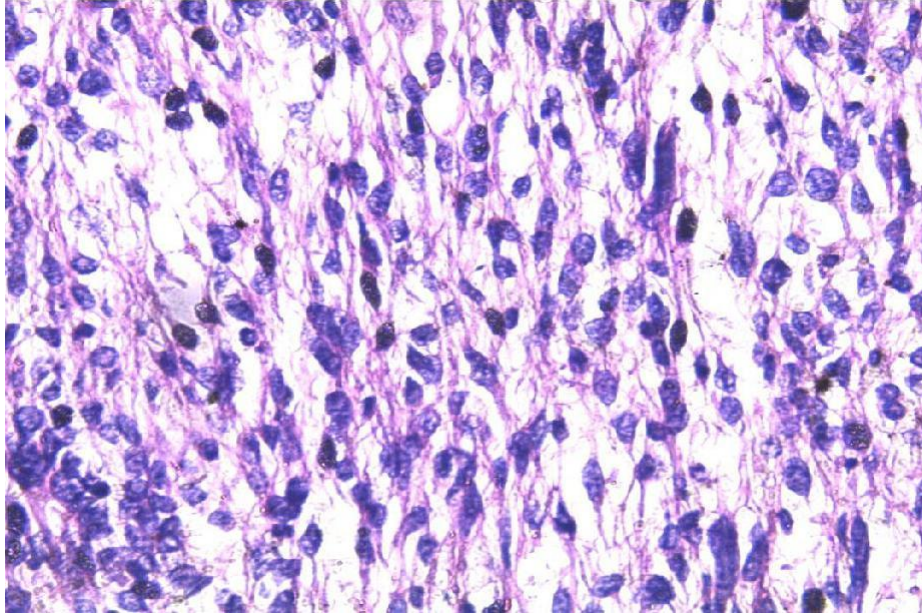


Figure 2. H and E: High power: showing an infiltrative smooth muscle tumor arranged in intersecting fascicles with oval to elongated blunt ended hyperchromatic nuclei with fibrillary eosinophilic cytoplasm (Leiomyosarcoma).

usual presentation, but she had low grade fever with foul smelling vaginal discharge. In our case, the lady had rapidly growing mass coming out of her introitus 6 months before she was presented.

A similar case was reported by Musa et al. (2005) in which patient had similar presentation but eventually turned out to be leiomyosarcoma of the uterus. Uterine leiomyosarcoma are considered neoplasm of high metastatic potential with 5 years overall survival rate varying between 0 and 73% (Bartsich et al., 1988; Hart and Billman, 1978). In this case, inspite of previous myomectomy, tumour had recurred, thus regular follow up may be suggested in perimenopausal women undergoing myomectomy. Women with tumor size more than 5 cm in maximum diameter have a poor prognosis (Evans et al., 1988).

CONCLUSION

Uterine leiomyosarcomas are rare, as such diagnosis is made only by histopathological examination, thus emphasizing the need for the same by an expert pathologist. Surgery is the mainstay of the treatment.

REFERENCES

- Melona GA, D'Elia A, Brogna C, Salvati M (2008). Uterine leiomyosarcoma metastatic to brain: A case report. *Tumori*, 94(6): 856-860.
- Bergman L, Beelen ML, Gallee MP, Hollema H, Benraadt J, van Leeuwen FE (2000) Risk and prognosis of endometrial cancer after tamoxifen for breast cancer. *Comprehensive cancer centres, ALERT Group Assessment of Liver and Endometrial Cancer Risk following Tamoxifen. Lancer*, 356: 881-887.
- Wickerham DL, Fisher B, Wolmark N, Bryant J, Costantino J, Bernstein L, Runowicz CD (2002). Association of Tamoxifen and uterine sarcoma. *J. Clin. Oncol.*, 20: 2758-2760.
- Van Dinh T, Woodruff JO (1982). Leiomyosarcoma of the uterus. *Am. J. Obstet. Gynecol.*, 144: 817.
- Barter JF, Smith EB, Szpak CA, Hinshaw W, Clarke- Pearson DL, Creasman WT (1985). Leiomyosarcoma of the uterus: Clinicopathologic study of 21 cases. *Gynecol. Oncol.*, 21: 220.
- Schwartz Z, Dgani R, Lancet M, Kessler I (1985). Uterine sarcoma in Israel: A study of 104 cases. *Gynecol. Oncol.*, 20: 354,.
- Musa J, Sagay AS, Wolmark N, Bryant J, Costantino J, Bernstein L, Runowicz CD (2005). Leiomyosarcoma uteri presenting as uterine inversion-A case Report. *J. Med. Trop.*, 7(1): 27-30.
- Bartsich EG, Bowe ET, Moore GT (1988). Leiomyosarcomas of the uterus: a 56 year review of 42 cases. *Obstet. Gynecol.*, 71: 845,.
- Hart RW, Billman JK (1978). A reassessment of uterine neoplasms originally diagnosed as leiomyosarcoma. *Cancer*, 41: 1902.
- Evans HL, Chawla SP, Simpson C, Finn KP (1988). Smooth muscle neoplasms of the uterus other than ordinary leiomyoma. A study of 46 cases, with emphasis on diagnostic criteria and prognostic factors. *Cancer*, 62(10): 2239-2247.