

Full Length Research Paper

Benign pleomorphic adenoma of minor salivary gland of palate

¹Mubeen K., Vijayalakshmi K. R.¹, Abhishek Ranjan Pati^{1, 2*}, Girish B. Giraddi³ and Chandravir Singh³

¹Department of Oral Medicine and Radiology, Government Dental College and Research institute, Bangalore, Karnataka, India.

²Department of oral Medicine and Radiology, Victoria Hospital Complex, Fort, Bangalore-560002, Karnataka, India.

³Department of Oral and Maxillofacial Surgery, Government Dental College and Research institute, Bangalore, Karnataka, India.

Accepted 21 April, 2019

Pleomorphic adenoma can be defined as a benign mixed tumor composed of epithelial and myoepithelial cells arranged with various morphological patterns, demarcated from surrounding tissues by fibrous capsule. It is one of the salivary gland tumors affecting both major and minor salivary glands. Parotid gland is the most commonly affected of the major group, and palate is the most common site intraorally. We report a case of palatal pleomorphic adenoma in a 35 year-old adult from South India. He came to Government Dental College with the chief complaint of a swelling at the left side of the palate. The oral mucosa covering the lesion was intact. CT scans revealed areas of bony destruction. Incisional biopsy was performed on this patient. The biopsy showed several ducts which were lined by cuboidal cells. These ducts were surrounded by myoepithelial cells, some of which had the plasmacytoid appearance. The patient was treated by wide local excision followed by placement of obturator and follow up was done for 1 year and no recurrence was observed till date.

Key words: Tumor, pleomorphic adenoma.

INTRODUCTION

Tumors arising from the minor salivary glands are uncommon clinical entities, accounting for 10 to 25% of all salivary gland tumors (Lucas, 1984). Pleomorphic adenomas, or benign mixed tumors, make up around 65% of all salivary gland tumors and are the most common type of tumors of the minor salivary glands (Waldron and Gnepp, 1998).

Pleomorphic adenomas occur at all ages, even occasionally in the newborn. Frazell (1954) reported instances in a 7-year old patient and an 82-year-old patient. However, the commonly affected age groups are

the fifth and sixth decades; 60% of them are women. We report a case of benign pleomorphic adenoma of the palate in a 34-year male patient.

CASE SUMMARY

A 35 year male reported to the department of oral medicine and radiology clinic with a slowly growing right hard palate mass that had been present for the past 1 year (Figure 1). The non tender mass was exerting pressure on the patient's tongue and this prompted him to seek medical attention. No associated constitutional symptoms were noted. On general examination, all the vital signs were within normal range with no history of diabetes or hypertension. On examining intraorally, a

*Corresponding author. E-mail: patiabhi@gmail.com. Tel: +9739809737.

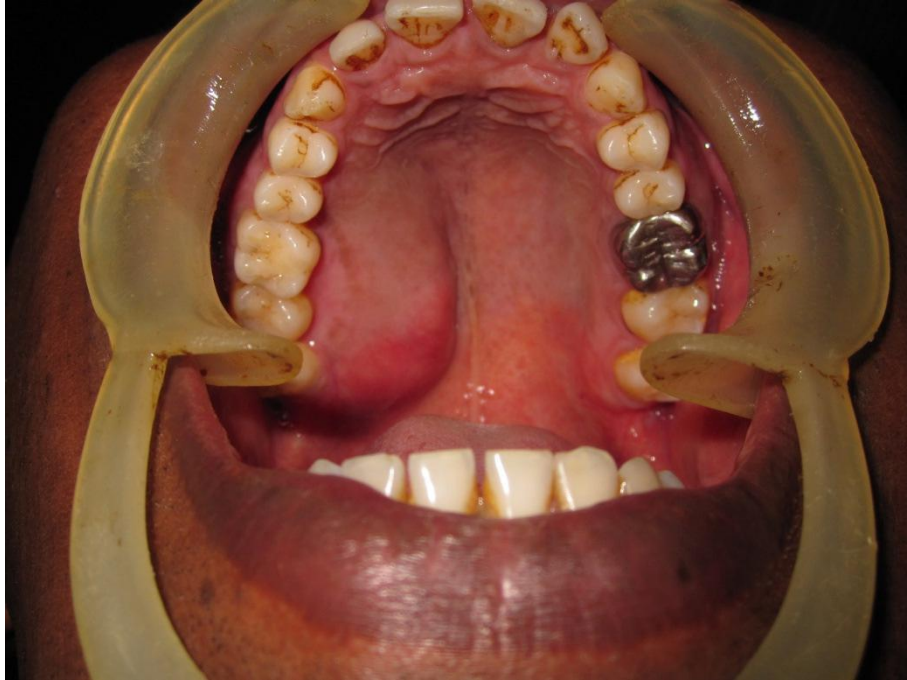


Figure 1. A diffuse swelling over the right side of the hard palate.

diffuse swelling was present in relation to the right side of the hard palate measuring roughly about 5 × 4.5 cm, roughly oval in shape (Figure 1). Anteroposteriorly, the swelling extends from the distal aspect of 13, posteriorly to the right side retromolar area. Mediolaterally, the swelling extends from the mid – palatal area to the lingual surface of maxillary molar teeth. The mucosa over the swelling appeared to be normal with no secondary changes. On palpation of the mass intraorally, the swelling was non – tender, firm in consistency, non-compressible, did not show any fluctuation or pus discharge. Hard tissue examination revealed no displacement or mobility of teeth however; Computed tomography (CT) showed a well-circumscribed 2.5 cm right hard palate mass with area of underlying bony destruction (Figures 2 and 3) Patient was taken to the theatre, under general anaesthesia, through nasoendotracheal intubation and throat pack was inserted. Then an incision was given surrounding the tumour including 2 mm of normal mucosal margins. Fine dissection was done and whole tumour mass was excised along with the mucoperiosteum and the eroded bone of the hard palate (Figures 4, 5 and 6). The palatal defect created after the wide excision of the tumour mass was covered with a palatal obturator. Patient was kept under observation as inpatient and cefotaxime 1g i.v and nasal decongestant were given for a week. Patient was given oral hygiene instructions and advised initially to wear obturator continuously for 10 days later only at meal times to promote healing by secondary intention. Complete healing of the defect took two and half months

and the patient was followed up every month up to 1 year and no recurrence was noted. The final histopathology report confirmed the diagnosis benign pleomorphic adenoma of minor salivary gland (Figure 7) of hard palate.

DISCUSSION

Pleomorphic adenomas, in general, comprise 40% of minor salivary gland tumors (Torske, 2006). They may arise in the nasal cavity, paranasal sinuses, and larynx (Seifert, 1996; Compagno, 1977). Patients with pleomorphic adenomas of the minor salivary glands present mostly in their fourth to sixth decades, with a slight predominance in female patients (Vellios and Shafer, 1959). They usually present as a unilateral, painless, slow-growing mass in the parotid gland. However, when they originate in the minor salivary glands, they mostly occur in the hard and soft palate (Frazell, 1954). The palate has the highest concentration of minor salivary glands in the upper aero digestive tract, and it is the most common site for benign and malignant minor salivary gland tumors (Tian et al., 2009; Wang et al., 2007; Toida et al., 2005; Daniels et al., 2007).

The clinical presentation of a pleomorphic adenoma arising from the hard palate is typically a firm or rubbery submucosal mass without ulceration or surrounding inflammation. FNA biopsy should be performed as an adjunct to diagnosis prior to definitive surgical treatment. CT or magnetic resonance imaging (MRI) should be

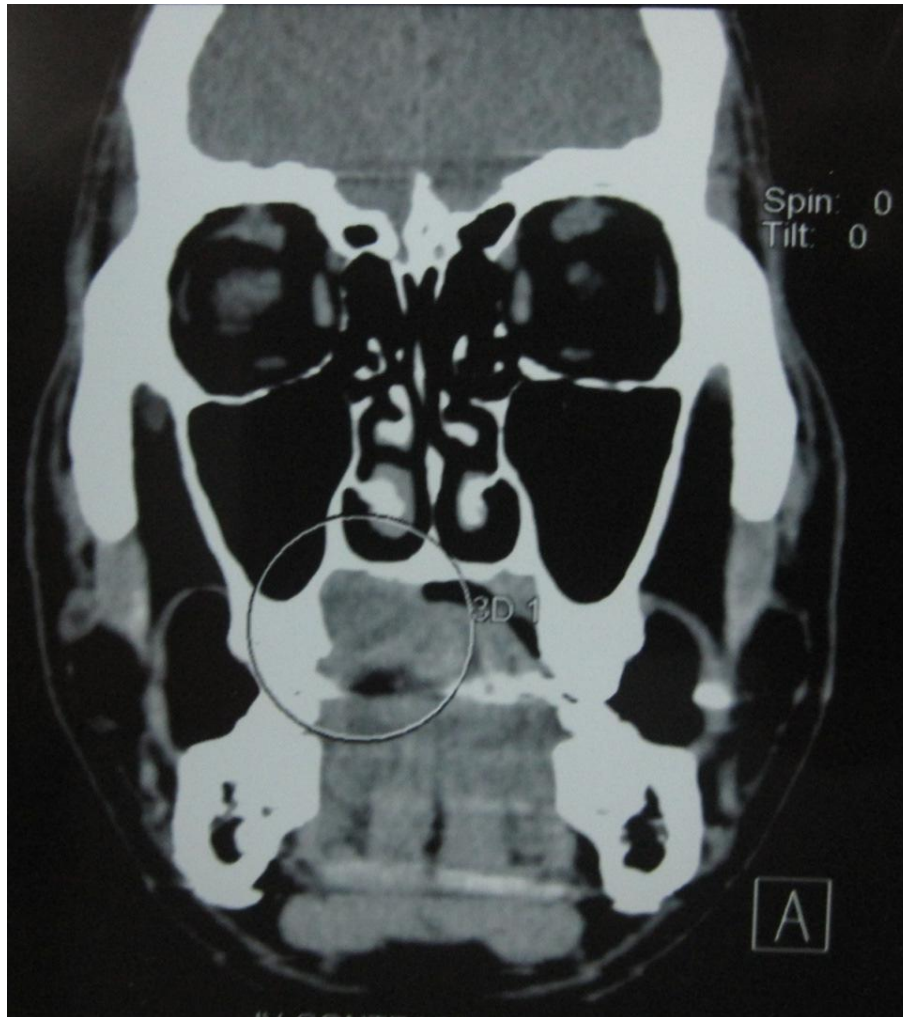


Figure 2.

Coronal ct section showing lesion extending to the palatal bone.

considered when assessing for presence of bony erosion or soft tissue and nerve involvement. Wide excision with negative margins is the optimal strategy for the management of pleomorphic adenomas (Mendenhall et al., 2008). Approximately 50% of all tumors derived from the minor salivary glands are reported to be malignant, adenoid cystic carcinoma being the most common malignant tumor (Frable and Elzay, 1970). Pleomorphic adenomas of minor salivary glands, like those on the palate, buccal mucosa or lip, occasionally lack encapsulations and may mix into normal host tissue as tumor growth (Gnepp et al., 2009); hence, a wide excision is necessary even if previous biopsies report a benign nature. The histological pictures of pleomorphic adenomas vary. Pleomorphic adenomas of the extra-major salivary glands are similar to those in the major salivary glands and are composed of a mixture of epithelial and stromal elements. Three main histologic subgroups have been identified: myxoid (80% stroma), cellular (myoepithelial predominant), and mixed (classic)

type (Ogata et al., 1994). A recurrence rate of 2 to 44% in the pleomorphic adenoma (mainly of the parotid gland) has been reported in the literature since 1939. Inadequate initial surgical procedure was reported to be the main causes of failure (Krolls and Boyers, 1971). Pseudopodia, capsular penetration, and tumor rupture with spillage of tumor cells are the most frequently encountered surgical issues (Patrick and Bradley, 2001). The differential diagnoses for this case include palatal abscess, odontogenic and non-odontogenic cysts, soft tissue tumors and salivary gland tumors. Palatal abscess can be ruled out by clinical examination since the source of palatal abscess which is typically a nonvital tooth in vicinity or a localized periodontal defect was not found. In addition, this patient showed no sign of inflammation. Both odontogenic and non-odontogenic cysts can be ruled out at the time of exploration into the mass since it did not demonstrate cystic nature. Palatal tissues contain components of soft tissue and harbour minor salivary gland tissues. As a result, soft tissue

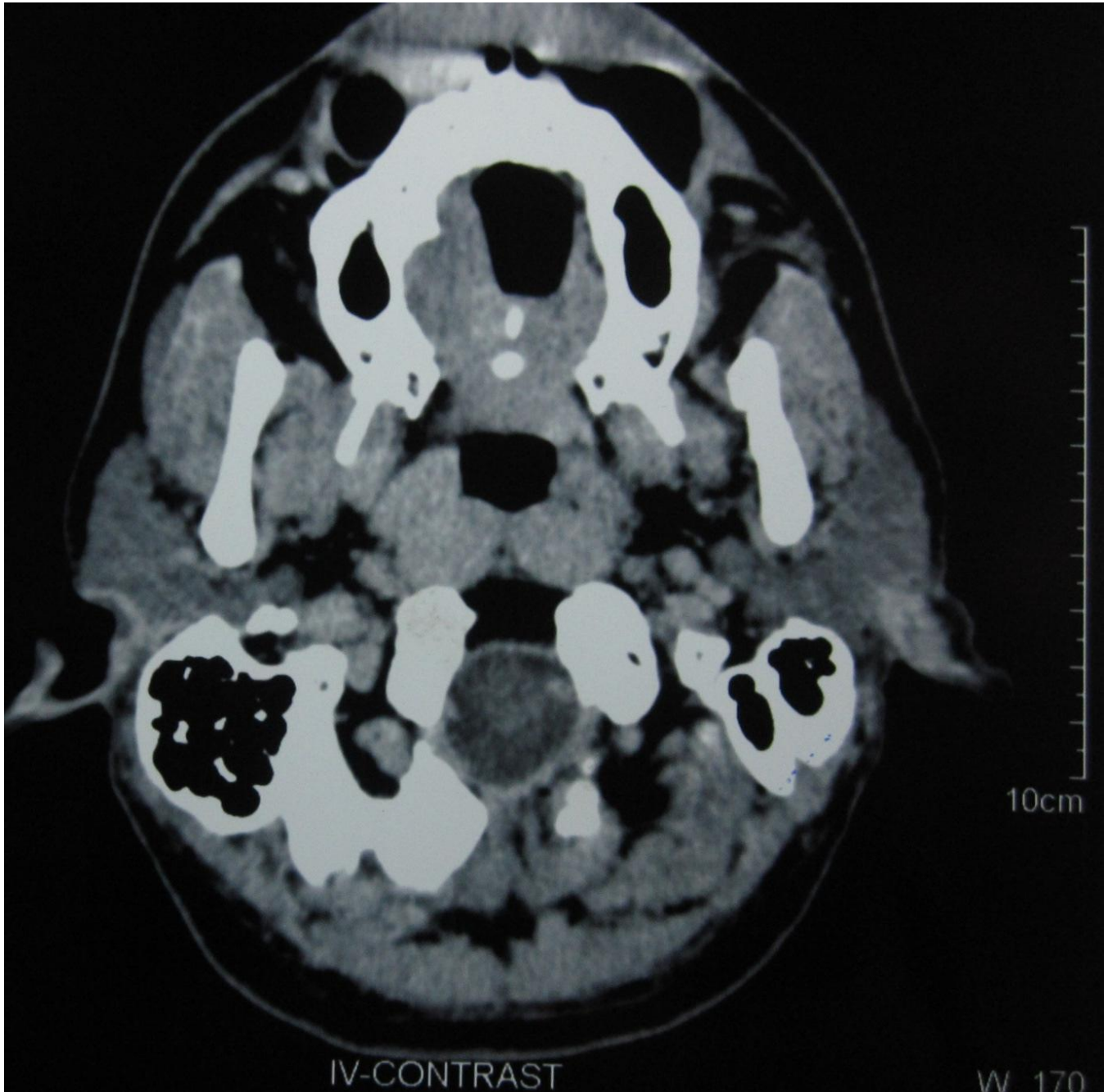


Figure 3. Sagittal ct image section showing lesion involving the right side of the hard palate..

tumors such as fibroma, lipoma, neurofibroma, neurilemmoma as well as salivary gland tumors should also be considered in the differential diagnoses for this case. The treatment of choice for pleomorphic adenoma in minor salivary gland is wide local excision with the removal of periosteum or bone if they are involved. Simple enucleation of this tumor is believed to lead to high local recurrence rate and should be avoided. Rupture of the capsule or tumor spillage is also believed

to increase the risk of recurrence, so meticulous dissection is paramount.

CONCLUSION

Pleomorphic adenoma generally does not recur after adequate surgical excision. Ultimately, complete surgical excision will provide the definitive diagnosis and treatment for this noteworthy salivary gland neoplasm.

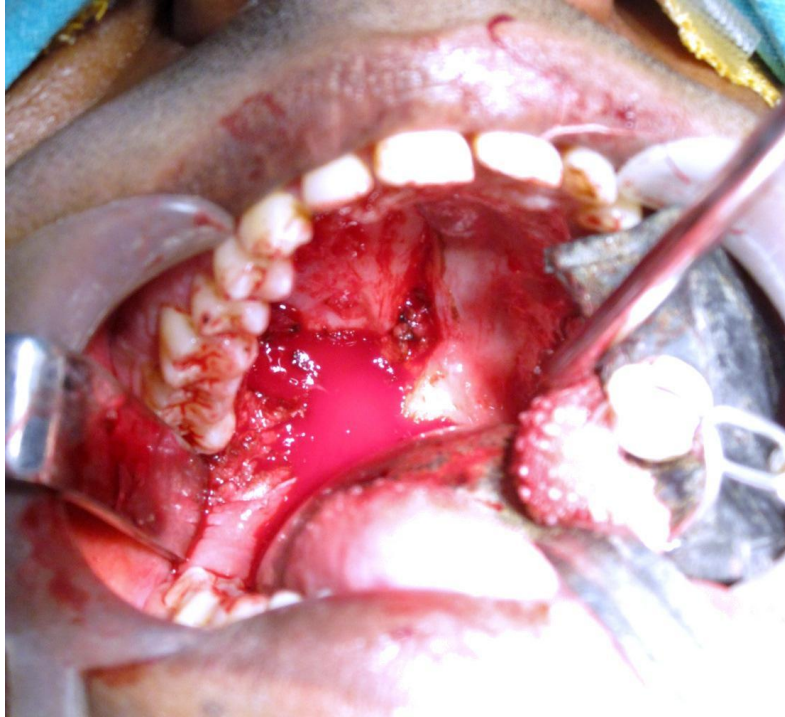

Figure 4. Surgically excised mass along with the underlying periosteum.

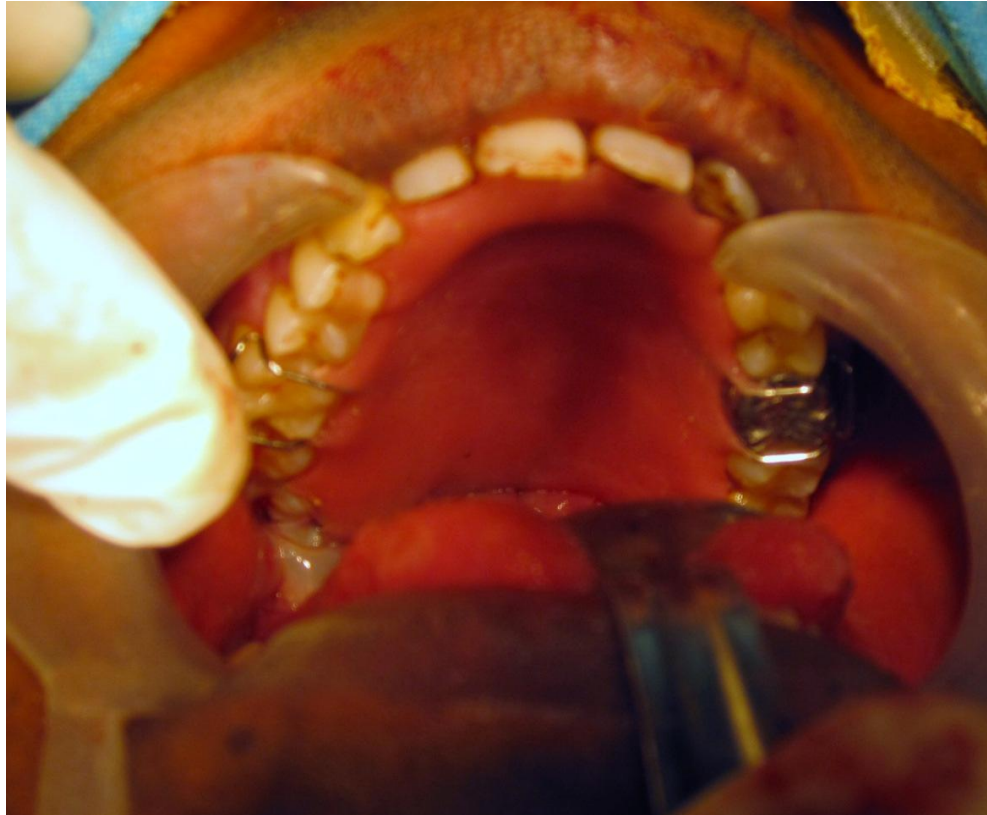


Figure 5. Maxillary obturator placed to prevent oroantral communication and to promote healing of the surgical area.

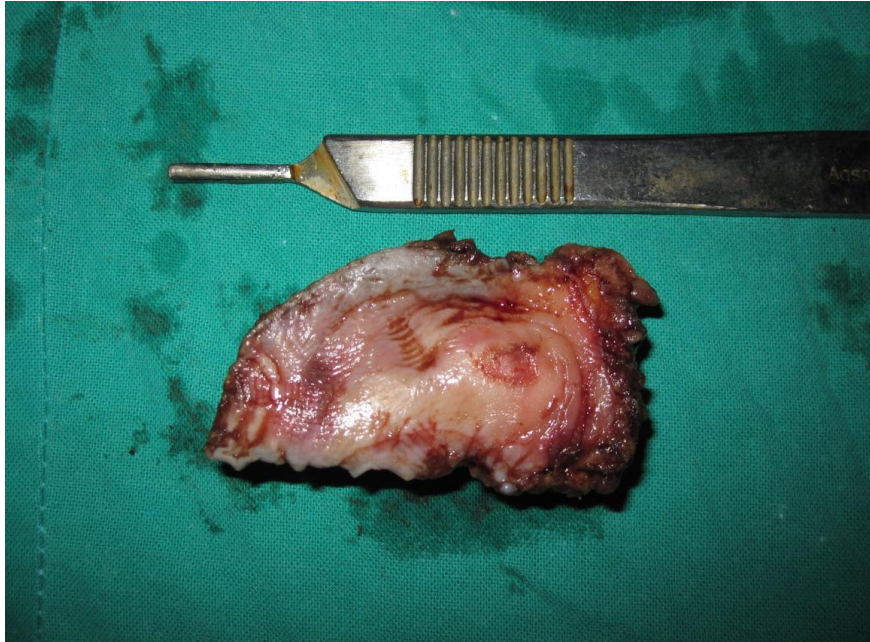


Figure 6. Surgically excised lesion.

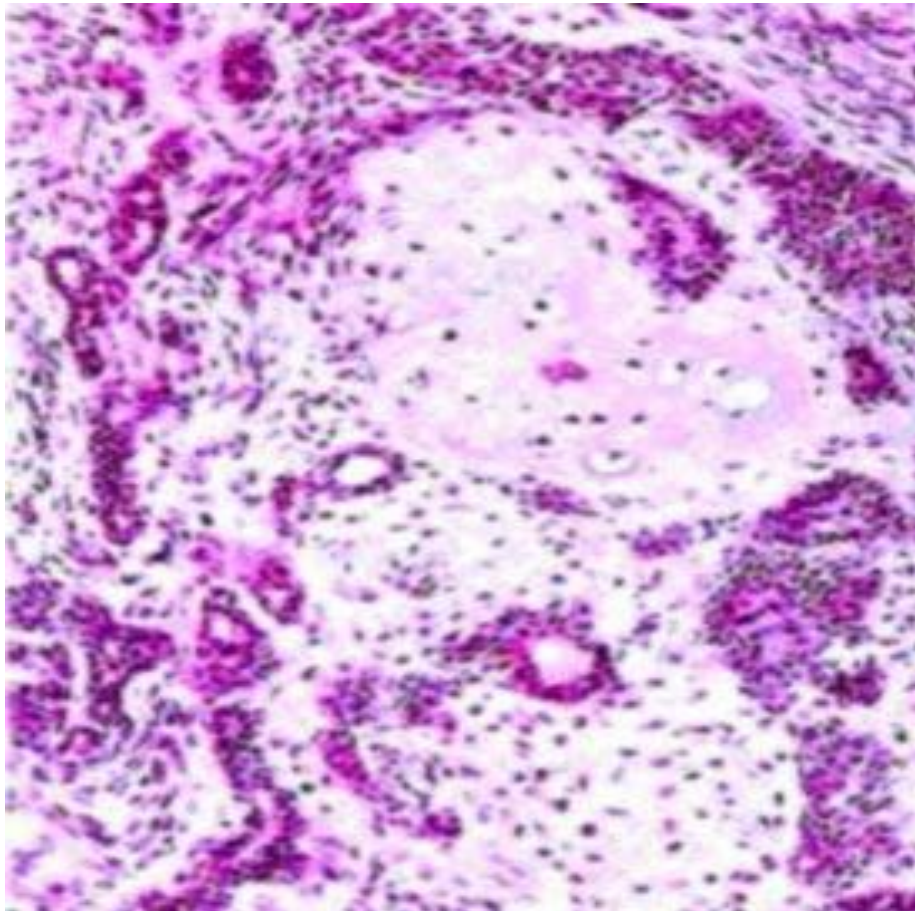


Figure 7. H/P shows sections fragments of benign neoplastic lesion formed of tubules and trabeculae of benign epithelial cells in a stroma that shows myxoid and chondroid tissue.

REFERENCES

- Lucas RB (1984). Pathology of tumors of the oral tissues. 4th ed. Edinburgh: Churchill Livingstone, 298-9.
- Waldron CA, Gnepp DR (1998). Tumors of the intraoral minor salivary glands: a demographic and histologic study of 426 cases. *Oral Surg. Oral Med. Oral Pathol.*, 66: 323-333.
- Frazell EL (1954). Clinical aspects of tumors Of the major salivary glands. *Cancer*, 1954: 637-642.
- Torske K (2006) Benign neoplasm of the salivary glands. In: Thompson LDR (ed.) *Head and neck pathology*, 1st edn. Elsevier, Philadelphia, pp. 295-300.
- Seifert GD (1996). Multiple tumors of the salivary glands: terminology and nomenclature. *Eur. J. Cancer B. Oral Oncol.*, 32: 3-7.
- Compagno JW (1977) Intranasal mixed tumors. *Am. J. Clin. Pathol.*, 68: 213-218.
- Vellios F, Shafer WG (1959). Tumors of minor salivary glands. *Surg Gynecol. Obstet.*, 108: 450-456.
- Tian Z, Li L, Wang L, Hu Y, Li J (2009). Salivary gland neoplasms in oral and maxillofacial regions: A 23-year retrospective study of 6982 cases in an eastern Chinese population. *Int. J. Oral Maxillofac. Surg.*, 39: 235-242.
- Wang D, Li Y, He H, Liu L, Wu L, He Z (2007). Intraoral minor salivary gland tumors in a Chinese population: A retrospective study on 737 cases. *Oral Surg. Oral Med. Oral Pathol. Oral Radiol. Endod.*, 104: 94-100.
- Toida M, Shimokawa K, Makita H, Kato K, Kobayashi A, Kusunoki Y (2005). Intraoral minor salivary gland tumors: A clinicopathological study of 82 cases. *Int. J. Oral Maxillofac. Surg.*, 34: 528-532.
- Daniels JS, Ali I, Al Bakri IM, Sumangala B (2007). Pleomorphic adenoma of the palate in children and adolescents: A report of 2 cases and review of the literature. *J. Oral Maxillofac. Surg.*, 65: 541-549.
- Mendenhall WM, Mendenhall CM, Werning JW (2008). Salivary gland pleomorphic adenoma. *Am. J. Clin. Oncol*, 31: 95-99.
- Frable WJ, Elzay RP (1970). Tumors of minor salivary glands. A report of 73 cases. *Cancer*, 4: 932-941.
- Gnepp DR (2009). Salivary gland (major and minor) and lacrimal gland. In: Gnepp DR (ed) *Diagnostic surgical pathology of the head and neck*, 2nd edn, WB Saunders, Philadelphia, pp. 434-449.
- Ogata H, Ebihara S, Mukai K(1994). Salivary gland neoplasms in children. *Jpn. J. Clin. Oncol.*, 24: 88-93.
- Krolls SO, Boyers RC (1971). Mixed tumor of salivary glands. Long-term follow-up. *Cancer*, 30: 276-281.
- Patrick J, Bradley M (2001). Recurrent salivary gland pleomorphic adenoma: Etiology, management, and results. *Curr. Opin. Otolaryngol. Head Neck Surg.*, 9: 100-108.