

Case Report

Fluoroscopic technique used to diagnose missed H-type tracheo-oesophageal fistula: Case report

Benard Ohene Botwe^{1,2*}, Y. B. Mensah², Kafui Kekesi², D. A. Anim², E. Akpanu², R. Vedenku², W. K. Antwi¹

¹Department of Radiography, School of Biomedical and Allied Health Sciences, P. O. Box KB 143, University of Ghana, Ghana.

²Department of Radiology, Korle-Bu Teaching Hospital, P. O. Box 77, Korle-Bu, Ghana.

Accepted 03 April, 2019

Congenital, isolated tracheo-oesophageal fistula (H-type) is a rare anomaly. It accounts for 4-5% of all congenital trachea-oesophageal malformations. This condition when undetected may present as chronic lung disease of unknown origin because repeated aspirations can lead to recurrent lung infections and bronchiectasis. Early diagnosis is essential in the newborn. However, the diagnosis of congenital H-type tracheo-oesophageal fistula is difficult. Oesophagram is usually a reliable radiographic method to identify the condition, though often requiring multiple attempts before the defect is confirmed. In some cases the disease may not be detected until adulthood. Herein, we present the fluoroscopic technique used to successfully diagnose originally missed H-type tracheo-oesophageal fistula at the Korle-Bu Teaching Hospital (KBTH), Ghana.

Key words: tracheo-oesophageal fistula, H-type, fluoroscopic techniques, 'AP by feeding technique'.

INTRODUCTION

A trachea-oesophageal fistula (TEF or TOF) is an abnormal connection between the oesophagus and the trachea (Jaiswal et al., 2014). Tracheo-oesophageal fistula and oesophageal atresia have a combined incidence of 1 in 3500 to 1 in 4500 births (Ross, 2011; Riazulhaq and Elhassan, 2012). TEF arise due to failed fusion of the tracheo-oesophageal ridges during the third/fourth week of embryological development as a result of interruption of the events responsible for elongation and separation of the oesophageal and tracheal tubes during the early foetal formation weeks

(Gunlemez et al., 2009). In addition, vascular insufficiencies, genetic factors, vitamin deficiencies, drug and alcohol exposures, and viral, chemical, and physical external events have been found to be contributors to the development of oesophageal atresia and/or TEF (Kronemer, 2014).

Pressure changes between the oesophagus and the trachea can cause entry of air into the oesophagus, or entry of oesophageal content into the trachea (Gunlemez et al., 2009). Clinical manifestations such as cyanosis, cough and choking with feeding, recurrent chest infections and persistent gastrointestinal distension are related to the presence of the fistulous connection (Jaiswal et al., 2014). This condition when undetected can lead to repeated aspiration and eventually chronic lung

*Corresponding author. E-mail: bbotwe@chs.ug.edu.gh.

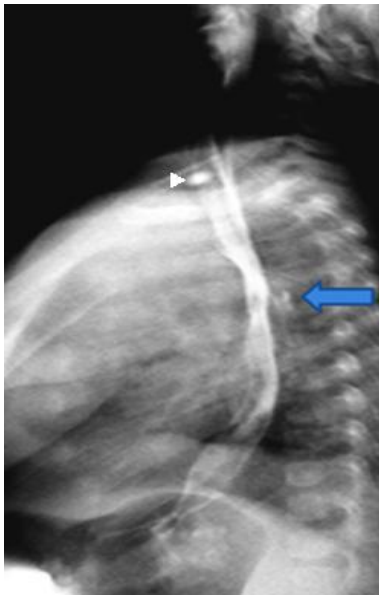


Figure1: Lateral projection; arrow showing spillage of contrast lungs. Arrow head shows artifact. (Source: patient's data).

disease and bronchiectasis of unknown origin. The presence of TEF also disrupts the normal development of the myenteric plexus of the oesophagus in utero, leading to disordered peristalsis and impaired lower oesophageal sphincter function (Kovesi and Rubin, 2014).

Congenital, isolated TEF (H-Type) was first described by Lamb in 1873 (Jaiswal et al., 2014) and it is a TEF without atresia which differs significantly from the other types of tracheo-oesophageal malformations in its presenting spectrum and features (Rose, 2011). H-type TEF accounts for 4-5% of all congenital tracheo-oesophageal malformations (Riazulhaq and Elhassan, 2012; Jaiswal et al., 2014).

However, this type of fistula is the most difficult to identify, both clinically and radiographically (Opilla, 2003; Kronemer, 2014). More commonly, the fistulae are small, inconstantly patent, and may require repeated examinations to identify (Coley, 2014). A major reason for inconstant patency of a fistula is that normal oesophageal mucosa can be redundant, which can transiently occlude the oesophageal side of the fistula (Mahalik et al., 2012; Coley, 2014). Early diagnosis is crucial in the newborn period therefore employing a strategic technique to identify it is very essential. We therefore report the fluoroscopic technique used to diagnose successfully congenital (H-type TEF) which was originally missed.

CASE REPORT

A 7 and half month old baby boy with history of recurrent

cough was referred to the radiology department of the Korle-Bu Teaching Hospital upon consultation with a radiologist. A contrast study had been requested to rule out tracheo-oesophageal fistula or aspiration. Prior to this request, the child had undergone barium swallow examination on two occasions at a different hospital for the same reason. The first attempt was not successful while the second showed barium in the trachea in the lateral projection but the result was inconclusive as the investigating team (comprising a radiologist and a radiographer) were not sure whether or not the contrast in the lungs was as a result of tracheo-oesophageal fistula or aspiration during the procedure.

Method used at KBTH

Prior to the procedure, the child's mother was told not to feed the child two hours prior to the procedure after consenting to the fluoroscopic examination. This was to ensure the stomach was empty to reduce tendency of aspiration, and enable the child drink the contrast when it is introduced.

A feeding tube was passed and tested for its right position. A control film was also acquired in anterior-posterior (AP) and lateral positions using digital pulsed fluoroscopy unit. Omnipaque (Iohexol) 300 mg I/ml was used as the contrast agent. The contrast was diluted with normal saline in a proportion of 1:1.

Under fluoroscopic guidance and intermittent screening, the contrast, with very careful volume control, was instilled by 20 ml syringe through the feeding tube while the distal part was in the stomach. The feeding tube was then withdrawn gradually, and at each segment (distal, mid and proximal) of the oesophagus, contrast was instilled to fill the oesophagus up to the hypopharynx for evaluation. This was undertaken with the patient in the right lateral projection, since the oesophagus is positioned posterior to the trachea and contrast spillage between the two structures would be expected. At this point contrast was noticed in lungs but the route of the contrast was unclear (Figure 1).

The baby was then placed in slightly right anterior oblique position with the feeding tube in-situ. The position was optimized during the examination to allow the best view of the anterior wall of the oesophagus and posterior wall of the trachea while contrast was being instilled. Contrast was seen in the trachea but failed to show an obvious H-type fistulous connection at T2 vertebral (Figure 2).

Since the feeding tube was removed after the oblique projection which was without success, the rest of the contrast (about 12 ml) was then poured into a feeding bottle and given to the baby to suck continuously to achieve full distension of the oesophagus while in AP position. The child's head was well adjusted and

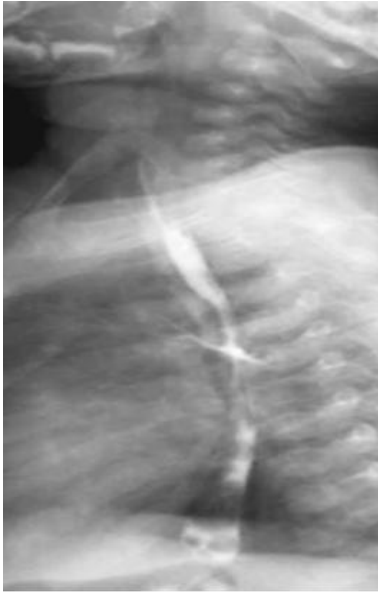

Figure 2. Oblique view showing contrast leakage but no obvious H-type fistulous connection. (Source: patient's data).

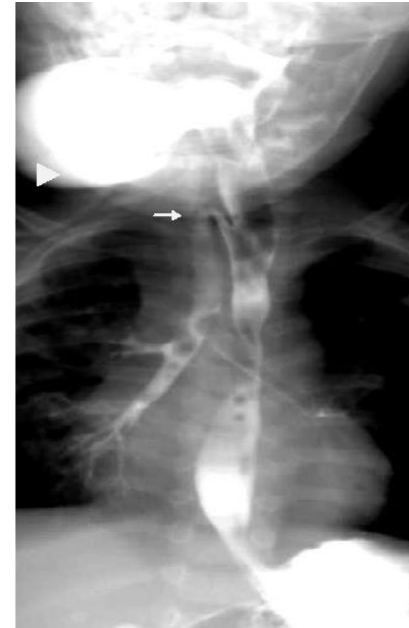


Figure 3: AP view. Arrow showing fistulous connection. Arrowhead shows feeding bottle.(Source: patient's data)

positioned with foam pads as though the child was sucking from the breast.

Contrast started outlining the fistulous tract and H-type TEF became conspicuous on the AP view at the level of T2 (Figures 3 and 4). The contrast administration was stopped immediately. Aftermath care then started.

DISCUSSION

Commonly, infants with oesophageal atresia with tracheo-oesophageal fistula have proximal atresia with distal TEF (Riazulhaq and Elhassan, 2012). They are easily diagnosed soon after birth as to obvious clinical features, nonetheless H-type TEF are not diagnosed early because oesophagus is patent (Riazulhaq and Elhassan, 2012). The obliquity of the H-type TEF and close apposition of the trachea and oesophagus mean that the fistula is occluded for much of the time, making its diagnosis very difficult and requiring strategic techniques (Gunlemez et al., 2009; Kronemer, 2014).

Bronchoscopy, a gold standard for diagnosing the above condition was not available in the hospital facilities during the diagnosing process. Many radiographic diagnostic techniques have been advocated in cases of H-type TEF such as scintigraphy, direct sagittal computed tomography (CT) and recently magnetic resonance imaging (Kronemer, 2014). However, Mahalik et al. (2012) suggest that although some of the modalities could provide good anatomic delineation, majority might

bottle. (Source: patient's data). [Note the arrows and their positions were misplaced in the proof copy sent to us.it with the above figure not help in surgical decision making.

Oesophagram3] is usually a reliable radiographic method to identify congenital H-type TEF and helps in management, though often requiring multiple attempts before the defect is confirmed (Riazulhaq and Elhassan, 2012). Some of these failed attempts have been linked to inadequate positioning and maneuvering. This patient has been subjected to two separate barium swallow examinations at a different hospital without success largely due to the latter aforementioned reason.

In our fluoroscopic approach, lateral, oblique and anterior-posterior (AP) projections were utilized. Contrast was first instilled at lateral position. Contrast was seen outlining the lungs when the oesophagus was well filled but it did not show any obvious tract (Figure 1). This suggest that lateral position may not always be definite in showing H-type TEF, since aspiration could have even accounted for the contrast in the lungs.

According to Coley (2014) the right lateral to slightly right anterior oblique position should be utilized during oesophagram. It is further suggested that the oblique position should be optimized during the examination to allow the best view of the anterior wall of the oesophagus and posterior wall of the trachea (Coley, 2014). In our study, the oblique view was utilized to provide some evidence of the contrast in the trachea but failed to show an obvious H-type fistulous connection (Figure 2).

An 'AP by Feeding Technique' was therefore adopted since the feeding tube was out during the oblique

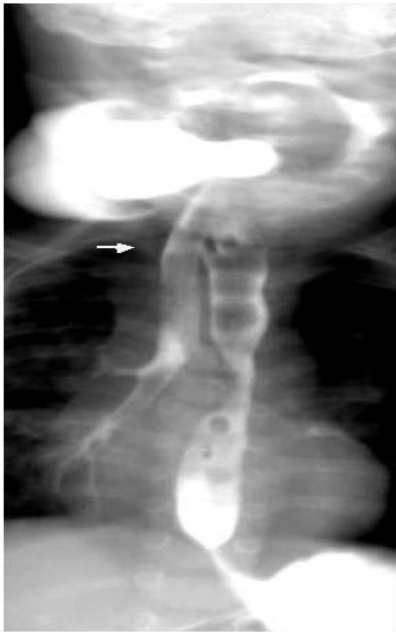

Figure 4. AP view depicting a typical H - Tracheo-oesophageal fistula. (Source: patient's data).

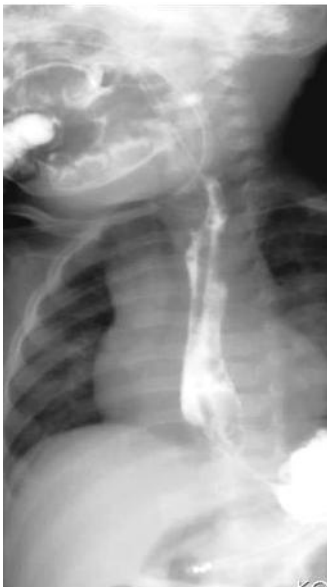

Figure 5. Post-surgery repair oesophagram shows no tracheo-oesophageal fistula. (Source: patient's data).

projection due to the struggling state of the child. Here the rest of the contrast (about 12 ml) was poured into a feeding bottle (a bottle with nipple like tip) and given to the child to drink continuously while in the AP position. Because the child had not eaten two hours to the

procedure drinking the contrast was successful. Subsequently distension of the oesophagus with contrast was achieved. This technique is not popular since there is much fear for aspiration tendencies in drinking supine (Opilla, 2013). However, with head well-adjusted as though the child was breast sucking, it proved to be the best in terms of diagnosing the condition minimising aspiration and being tolerated by the child. The use of contrast agents for examining children with oesophageal atresia and/or trachea-oesophageal fistula is of special concern because of the risk of aspiration. Barium possibly enables the best visualization; however, extra luminal barium has a risk of causing a granulomatous and fibrotic reaction that can result in fibrous mediastinitis (Kronemer, 2014). It is also suggested that Hyperosmolar agents, such as Hypaque and Gastroview should not be used because they cause marked irritation of bronchi and pulmonary edema if they are aspirated (Kronemer, 2014). The contrast used in our study was omnipaque (Iohexol) 300 mg I/ml, an aqueous low-osmolality agent. Aqueous low-osmolality agents are preferred in neonates, premature infants, and children with a suspected oesophageal perforation (Kronemer, 2014:

10). This is because they have very minimal deleterious effects on the GI and the respiratory systems (Kronemer, 2014; Coley, 2014; Generic drugs, 2014). The concentration and dilution was based on the manufacturer's instructions. The contrast was diluted with normal saline in a proportion of 1:1 and in all 20 ml of the mixture was utilized. The dilution was enough to visualize the contrast on fluoroscopy and it was considered safer since omnipaque (Iohexol) in lower concentration (normally 140 mg I/ml) is isotonic with tissue fluid and has limited effects (Generic drugs, 2014). A post repair (a simple incision of the tracheo-oesophageal fistula) oesophagram, which also employed the 'AP by Feeding Technique', eight days later showed a successful disconnection of the oesophagus and the trachea at the level of T2 vertebral (Figure 5). Conclusion The radiographic diagnosis of congenital H-type tracheo-oesophageal fistula (TEF) is difficult, often requiring multiple oesophagram attempts before the defect is confirmed. With 'AP by Feeding Technique' of oesophagram, the diagnosis of congenital H-type TEF which was originally missed, has been successful at the Korle-Bu Teaching Hospital.

REFERENCES

- Coley B, D. Caffey's Pediatric Diagnostic Imaging. 12th edition, Ohio: Elsevier, 2014
- Gunlmez A, Anik Y, Elemen L, Tugay M, Gokalp AS (2009). H-type tracheo-oesophageal fistula in an extremely low birth weight premature neonate:

- appearance on magnetic resonance imaging. *J Perinatol.*, 29: 393–395.
- Jaiswal AA, Garg KA, Mohanty KM (2014). 'H' type Tracheo-oesophageal fistula-Case reports with review of literature. *Egyptians J. Ear, Nose, Throat Allied Sci.*, 15: 143-148
- Kovesi T, Rubin S (2004). Long-term complications of congenital esophageal atresia and/ or tracheoesophageal fistula. *Chest*, 126:915–925
- Kronemer KA (2014). Imaging in *Esophageal Atresia and Tracheoesophageal Fistula* Accessed 06 October, 2014.<http://emedicine.medscape.com/article/414368-overview>
- Mahalik SK, Sodhi KS, Narasimhan KL, Rao KLN (2012). Role of preoperative 3D CT reconstruction for evaluation of patients with esophageal atresia and tracheoesophageal fistula. *Pediatr. Surg. Int.*, 28:961-966.
- Opilla M (2003). Aspiration Risk and Enteral Feeding: A Clinical Approach. *Pract. Gastroenterol.*, 89-96
- Riazulhaq M, Elhassan E (2012). Early recognition of H-type tracheoesophageal fistula. *APSP J. Case Rep.*, 3: 1-4.
- Ross AJ (2011). Organogenesis of the Gastrointestinal Tract. In Polin, R., A, Fox, W,W, Abman, S.H. *Fetal and Neonatal Physiology*.4th edition. Philadelphia: Saunders. Pp.11-88.
- Generic drugs. *Omnipaque 300* 2014. Accessed 12 October, 2014. <http://www.igenericdrugs.com/gd.cgi?notran=1&s=omnipaque+300&search=SEARCH>