

Full Length Research paper

Studies on effects of aqueous *Garcinia kola* extract on the lateral geniculate body and rostral colliculus of adult Wistar rats

Olajide Olayemi Joseph* and Adeniyi Philip Adeyemi

Department of Anatomy, Faculty of Basic Medical Sciences, University of Ilorin, Ilorin, Kwara State, Nigeria.

Accepted 15 April, 2020

Study investigated the effects of *Garcinia kola* on the micro architecture of the rostral colliculus and lateral geniculate body of rats, and its effects on some enzymes were as well investigated. Sixteen F1 adult Wistar rats with an average weight of 195.5 g were randomly assigned into a control and an experimental group. Both groups consisted of eight animals each (4 males and 4 females). Aqueous extract of *Garcinia kola* was prepared and the stock solution was mixed with phosphate buffered saline. Each animal in the experimental group was administered 2.4 g/kg body weight/day of the extract for 21 days, while each of the animals in the control group were administered with equal volume of phosphate buffered saline for the same duration of time. Weight measurements were recorded on daily basis. After sacrifice, the tissues were excised and fixed in formolcalcium for routine histological examination (Hematoxylin and Eosin). Tissues for biochemical assay were homogenized in 0.25M sucrose to demonstrate the activities of lactate dehydrogenase (LDH) and glucose-6-phosphate dehydrogenase (G6PDH). Histological analysis showed normal cytoarchitecture of the tissues in the experimental group when compared with those in the control group, but there was a significant increase in the activities of LDH and G6PDH, suggesting that *Garcinia kola* increased carbohydrate metabolism and energy production through the Embden Meyerhoff's pathway and hexose monophosphate shunt respectively in the tissues of interest. The effects were however not sex dependent.

Key words: Rostral colliculus, *Garcinia kola*, phosphate buffered saline, formolcalcium, Bouin's fluid, lateral geniculate body.

INTRODUCTION

Garcinia kola: Medicinal applications

Garcinia kola, (bitter kola, name sometimes used for *Garcinia afzeli*) are species of flowering plant in the Clusiaceae or Guttiferae family. The tree is found in moist forest and grows as a medium size tree, up to 12 m high (Iwu, 1993). It is found in Benin, Cameroon, Democratic Republic of Congo, Ivory Coast, Gabon, Ghana, Liberia, Nigeria, Senegal and Sierra Leone. Its natural habitat is subtropical or tropical moist lowland forests (Iwu, 1993). The nut is medicinal and it has some aspect of spiritual healing factors attached to it over the

years as well. The seeds are rich in flavonoids, which have been shown to have antibiotic property (Hong and Song, 2001) anti-inflammatory property (Braide and Vittratio, 1989) and antimicrobial activity (Madubuyi, 1995). In Nigeria it is commonly called Orogbo in Yoruba, Naminji goro in Hausa and Akuilu in Igbo, serving as local snacks in some communities especially in the northern part of the country (Adie, 2008).

Trials on the plant have shown promising signs that it may benefit Ebola victims by slowing down multiplication of the virus, giving the victim's body more time to develop a proper autoimmune response (Adefule-Ositelu et al., 2010). The active compound responsible for its curing properties is a 'dimeric flavonoid', much like those found in oranges and lemon rinds that yields to modification, so

*Corresponding author. E-mail: llcooly03@yahoo.com. Tel: +23480-6838-4025, +23480-5429-0825.

even if this particular plant cannot cure Ebola on its own, it provides the foundation from which scientists can discover a cure. Studies, if successful, could spill over to other types of antiviral treatment (Iwu, 1993). The seeds are used in the treatment of bronchitis and throat infections. They are also used to prevent and relieve colic problems, cure head or chest colds and relieve cough. Also the plant is used as chewing stick and in liver disorders (Iwu, 1993).

Researchers believe that the chemical saponin, also present in *Garcinia kola* is responsible for its cleansing effect. Saponin is mainly used as tonic for the liver; it enhances the functions of the liver and gall bladder. *Garcinia kola* has also been reported to be used in many tropical countries to fight infectious diseases such as HIV, gonorrhoea and other viral diseases (Oguntola, 2009).

Garcinia kola is used traditionally to cure illness by African traditional medicine men. The seed is used in traditional medicine for various therapeutic purposes based on pharmacological effects of the active components (Flavonoid) in the seed and other parts of the plants (Braide and Vittrotio, 1989). Despite the fact that physiological studies are still lacking to validate the therapeutic ability of *Garcinia kola*, its use in African traditional medicine cannot be over emphasized (Orie and Ekon, 1993).

Holmes (1960) reported that *Garcinia kola* seeds are used as an antidote to the effects of *Strophantus gratus*. It also serves as a remedy to guinea-worm (Lewis, 1977). *Garcinia kola* is used for parasitic skin diseases while the latex is used internally for gonorrhoea. In the past, when food is suspected to be contaminated by bacteria, our fore fathers chew bitter kola immediately after the meal to forestall the development of any infection or poisoning and it works rather effectively. They also use bitter kola locally, with illnesses like mumps and measles in children, it is ground or chopped into tiny bits and mixed with honey or palm oil which the child drinks and some of it rubbed on his or her body.

It is also said to stop vomiting in children and adult during pregnancy. Also, by boosting serotonin levels in brain, bitter kola brings about a slight loss of appetite and is therefore used for dietary purposes. Bitter kola nut are also used in preventing arthritis, and is also used in some brewing industry as a substitute and preservative, it is used as a substitute for hops in brewing lager beer. It is especially useful in preventing beer spoilage (Oguntola, 2009). Despite its extensive use in both herbal and modern medicine, much work has not been done to find out the toxicological implications of heavy use on other related systems.

Few or no studies have been reported on the effects of bitter kola on the lateral geniculate body and superior colliculus as at the time of this research. This research work is intended to ascertain some of the effects of bitter kola on the lateral geniculate body and superior colliculus. The study however, is restricted to the histological assessment and biochemical studies of the

experimental animals and an evaluation of the sex dependency of the effects. Comparison of the experimental and the control animals were made to establish some of the effects of the plant on the tissue of interest.

Rostral colliculus

This is a paramedian eminence, one on either side, located in the upper part of the tectum in the midbrain. It is well developed in lower vertebrates, but much more simplified structurally in the higher vertebrates, and particularly so in primates. It functions in visual attention and centering of image on the retina, thereby serving essentially as a visual relay centre (Collins et al., 2005).

Profundum gross categorization

It is organized into 7 alternating fibrous and cellular layers. These are further categorized into superficial and deep layers: (Collins et al., 2005).

Superficial layer

Stratum zonale (SZ)
Stratum griseum superficiale (SGS)
Stratum opticam (SO)

Deep layer

Stratum griseum intermedium (SGI)
Stratum album intermedium (SAI)
Stratum griseum profundum (SGP)
Stratum album (SAP)

Cells in superficial layers respond to visual stimuli and their response is insensitive to shape and size of stimuli. They also respond to both moving and non moving stimuli, although moving stimuli produce more vigorous response. They respond more vigorously to stimuli that are the target of a saccade. Cells in the deep layers respond to multimodal sensory inputs and visuomotor cells that discharge in association with saccades. They also respond to bi- and tri-modal cells that respond to visual and somatosensory and/or auditory stimuli (Collins et al., 2005).

Lateral geniculate nuclei

The lateral geniculate nucleus (LGN) is the primary processing centre for visual information received from the retina of the eye. The LGN is found inside the thalamus of the brain, and is thus part of the central nervous system (Collins et al., 2005). The LGN receives information directly from the ascending retinal ganglion cells through the optic tract and from the reticular activating

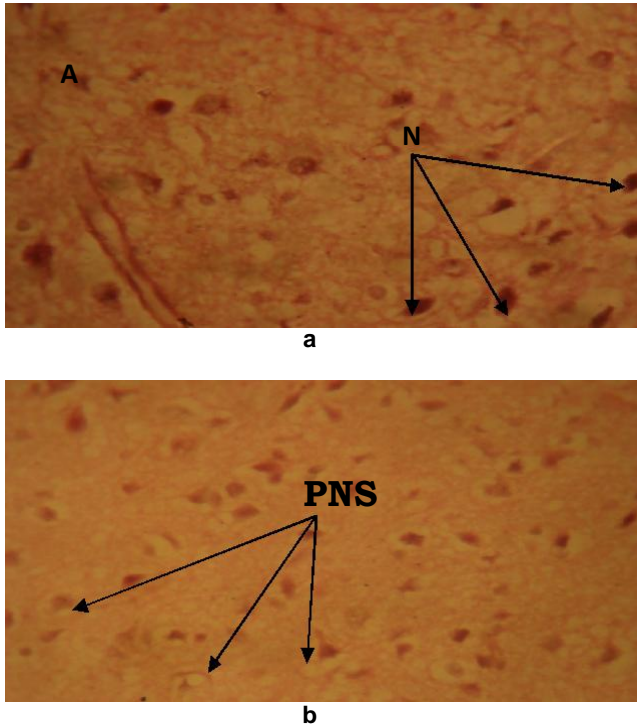


Figure 1. Photomicrograph of lateral geniculate nuclei of the experimental group (Plate a) and control group (Plate b) at day 21 (H and E x480), (A=axons, N=nuclei, PNS= perineural spaces).

system. Neurons of the LGN send their axons through the optic radiation, a pathway directly to the primary visual cortex (or V1), also known as the striate cortex. The primary visual cortex surrounds the calcarine fissure, a horizontal fissure in the medial and posterior occipital lobe (Collins et al., 2005).

MATERIALS AND METHODS

Experimental animals

Sixteen F1 Wistar rats were bred from six parents' adult Wistar rats (two males and four females) in the animal house of the Anatomy Department University of Ilorin. The cage floor was covered with saw dust to provide a "soft floor". The F1 generation rats were weaned at 40 days after birth using the method of (Sotoblanco and Aparicio, 2002). The animals were weighed twice a week and were raised to adulthood with an average weight of 195.5 g. The animals were then randomly selected in to a control group A, and a treatment Group B, each group containing equal number of males and females each (four male four females in each group). The animals were weighed on a daily basis throughout the duration of the experiment using the sensitive weighing balance (Gallenkhamp FA4102A) in the Department of Anatomy, University of Ilorin.

Extract preparation

Garcinia kola (seed) was peeled, chopped into bits and grounded into fine powder. Fifty grams of the powder was then mixed with

500 mls of water and allowed to soak for 48 h under room temperature. After 48 h, the mixture was filtered twice using a filter paper and the filtrate was left to evaporate under room temperature until it was totally dried. The stock solution was therefore prepared, such that 10 g of the *Garcinia kola* was dissolved in 100 ml of phosphate buffered saline, which serves as the vehicle of administration.

Administration of extract

The method of administration adopted was Oro-gastric method using an Oro-gastric tube. Each animal in the experimental group was administered 2.4 g/kg body weight/day of the extract for a period of 21 days, while each of the animals in the control group were administered an equivalent volume of phosphate buffered saline for the same number of days. During the course of administration, the animals were fed with grower's mash (Bendel mills) and water liberally.

Euthanasia

An ethical clearance was obtained from the ethical committee of the faculty of basic medical Sciences, University of Ilorin before the commencement of the study. The method of euthanasia used was cervical dislocation; the head was immediately separated from the trunk.

Histological parameters

After fixing the lateral geniculate body and rostral colliculus of the experimental and the control animals, they were processed for Hematoxylin and Eosin. After fixation, the tissues were embedded in paraffin wax; serial sections of 5 μ m thick were produced using the Leitz Rotary microtome (Leitz 1512 Microtome). The sections were mounted in DPX and examined with the aid of Olympus binocular light microscope (XSZ-107BN, No. 071771). The photomicrograph of each slide was taken with a digital photo camera (Coolpix E990; Nikon, Japan) for subsequent histological analysis.

Statistical analysis

Data were statistically evaluated using the student's t-test with SPSS/14.0 software (SPSS Inc, Chicago, USA) and were expressed as Mean \pm Standard error of mean (SEM). A value of $p < 0.05$ was considered to indicate a significant difference between groups.

RESULTS AND DISCUSSION

Histological analyses

Lateral geniculate body

Male sub-group: Photomicrograph of the experimental group (Figure 1a) shows large nuclei in its cell with numerous axons in the neurons than that of the control group (Figure 1b). The cells are also deeply stained in the experimental group than obtainable in the control. There also appear to be perineural spaces around the

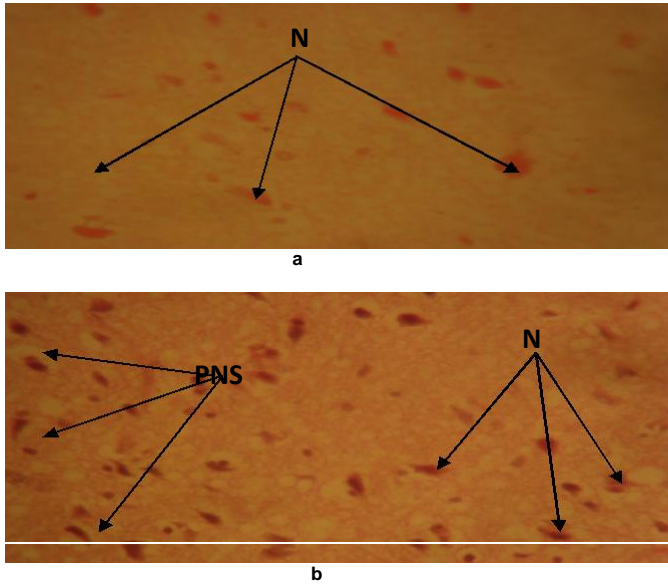


Figure 2. Photomicrographs of lateral geniculate nuclei of the experimental group (Plate a) and control group (Plate b) at day21 (H and Ex480), (PNS=perineural spaces, N= nuclei). Female sub-group.

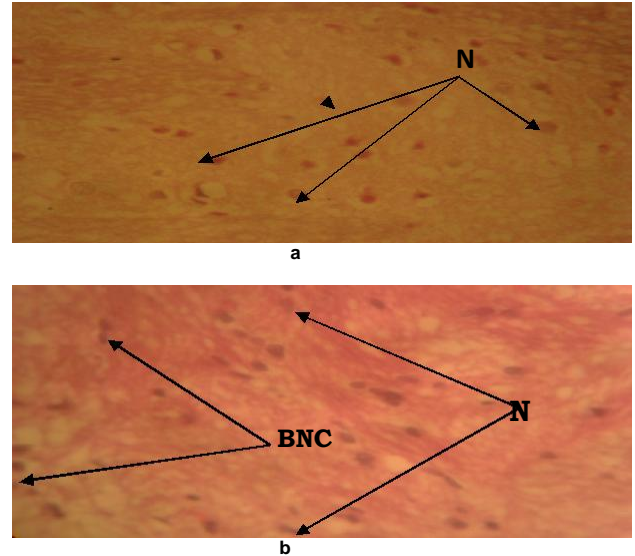


Figure 4. Photomicrographs of rostral Colliculus of the experimental group (Plate a) and control group (Plate b) after at day 21 (H and E x480) (BNC=binucleate cells, N=nuclei). Female sub-group.

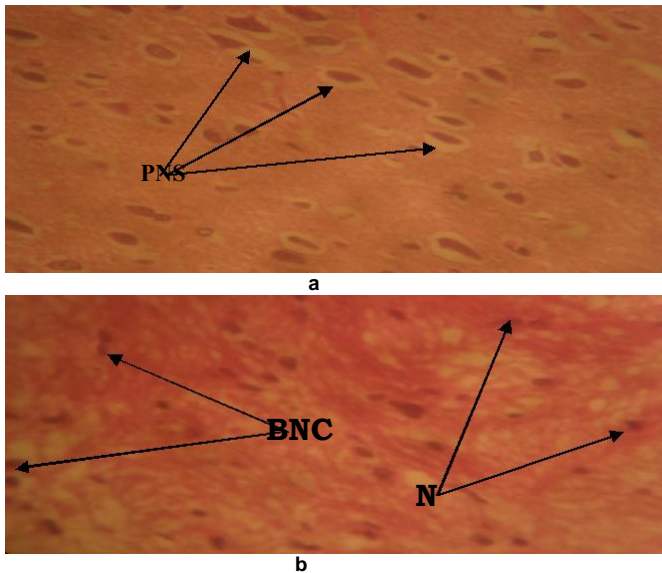


Figure 3. Photomicrographs of rostral colliculus of the experimental group (Plate a) and control group (Plate b) at day21 (H and E x480), (N=nuclei, BNC=binucleate cells, PNS= perineural spaces). Male sub-group.

nuclei of the control group. Numerous axons in the neurons of the experimental group may suggest that the tissue is active in transmission of nervous impulses.

Female sub-group: Very few nuclei are observable in the experimental group (Figure 2a) but they appear larger and are more deeply stained when compared with the nuclei of the control group (Figure 2b). Some perineural

spaces are noticeable in the control group. The cellular integrity of both groups appears normal. Axons of neurons are prominent in the experimental group and fibers can be seen crisscrossed. Larger nuclei with more visible axons of neurons might be a result of increased activities in the cells from tissues of the experimental groups in comparison to the control group. The cell architecture of both groups appears normal.

Rostral colliculus

Male sub-group: The photomicrograph of the experimental group shows bigger and prominent nucleated cells (Figure 3a) than obtainable in the control group (Figure 3b). On the contrary however, the experimental group shows perineural spaces around the nuclear membrane. Majority of the neurons are multipolar and the supporting fiber networks are adequately distributed within the background of the experimental group as opposed to the control group which have adequately dispersed and normal neurons.

The rostral colliculus receives and send visual fibers and they are believed to be involved in the mechanism of vision, although their specific action is unknown. The densely stained nucleated cells may suggest increased activity of the tissue which includes synthesis of energy and DNA replication within the cells. Perineural spaces around the nuclei might suggest degenerative changes.

Female sub-group: Photomicrograph of the experimental group (Figure 4a) shows few nuclei in the cells but the cells appear to be more deeply stained than the nuclei of cells in the control group (Figure 4b) which

Table 1. Biochemical assay raw data (1 and 2 for male sub-groups, 3 and 4 for female sub-groups).

S/N	Groups	Tissues	Animals (g)	Weight of tissues (g)	LDH ($\mu\text{l/g}$)	G6PDH ($\mu\text{l/g}$)
1	Experimental 1	LGB	221	0.0038	25.608	22.000
	Experimental 2	LGB	215	0.0045	27.904	27.604
	Experimental 3	LGB	183	0.0043	28.771	28.445
	Experimental 4	LGB	193	0.0052	23.881	31.333
2	Control 1	LGB	205	0.0032	20.404	15.402
	Control 2	LGB	205	0.0036	15.307	12.402
	Control 3	LGB	193	0.0028	17.321	17.243
	Control 4	LGB	203	0.0032	16.623	15.432
3	Experimental 1	SC	221	0.0037	28.318	20.620
	Experimental 2	SC	215	0.0350	33.062	27.743
	Experimental 3	SC	183	0.0036	31.876	29.064
	Experimental 4	SC	193	0.0032	29.432	22.432
4	Control 1	SC	205	0.0035	14.150	14.978
	Control 2	SC	205	0.0025	13.623	16.363
	Control 3	SC	193	0.0023	13.532	18.345
	Control 4	SC	203	0.0103	19.423	17.890

appear normochromic. The larger nuclei in the cells of the experimental group observable in both the male and female sub-groups may suggest increased activity of the tissues at the cellular levels. However, the perineural spaces of the experimental group in the male sub-group may be as a result of degenerative changes. On general observation, it was not observed much difference in the cytological integrity of both lateral geniculate body and superior colliculus when the tissues were stained with Eosin and Hematoxylin.

Biochemical analyses

Glucose-6-phosphate dehydrogenase (G6PDH)

The activity of G6PDH in LGB (Table 1) shows a considerable increase that was statistically significant when the experimental group (27.35 ± 1.95) was compared to the control group (15.12 ± 1.00) using a student t-test as in indicated by the value of mean \pm Standard Error of Mean (SEM). There is also an increase in G6PDH activities of the experimental group (24.97 ± 2.04) of the SC compared to the control group (16.84 ± 0.77) which is statistically significant. Glucose-6-phosphate dehydrogenase is a cytosolic

enzyme in the pentose phosphate pathway, a metabolic pathway that supplies reducing energy to cells (such as erythrocytes) by maintaining the level of the co-enzyme nicotinamide adenine dinucleotide phosphate (NADPH). The NADPH in turn maintains the level of glutathione in

these cells that helps protect the red blood cells against oxidative damage. Of greater quantitative importance is the production of NADPH for tissues actively engaged in biosynthesis of fatty acids and/or isoprenoids, such as the liver, mammary glands, adipose tissue, and other tissues in the body (Corpas, 1998). G6PD is widely distributed in many species from bacteria to humans. In higher plants, several isoforms of G6PDH have been reported, which are localized in the cytosol, the plastidic stroma, and peroxisomes (Vulliamy et al., 1993).

Glucose-6-phosphate dehydrogenase is stimulated by its substrate glucose-6-phosphate. The usual ratio of NADPH/NADP⁺ in the cytosol of tissues engaged in biosyntheses is about 100/1. Increased utilization of NADPH for fatty acid biosynthesis will dramatically increase the level of NADP⁺, thus stimulating G6PD to produce more NADPH.

G6PD converts glucose-6-phosphate into 6-phosphoglucono- δ -lactone and is the rate-limiting enzyme of the pentose phosphate pathway. Increased activity of glucose-6-phosphate dehydrogenase in the experimental groups indicates that *Garcinia kola* increased energy and ribose production through the pentose phosphate pathway.

Lactate dehydrogenase (LDH)

The activity of LDH in the LGB shows a significant increase in the experimental group (26.54 ± 1.12) when compared with the control group (17.41 ± 1.81). Also, a

statistically significant increase in LDH activity of the SC was noticeable in the experimental group (30.64 ± 1.09) when compared with the control group (15.18 ± 1.42) as shown by the values of mean and SEM.

Lactate dehydrogenases exist in four distinct enzyme classes. Two of them are cytochrome C-dependent enzymes, with each acting on either D-lactate or L-lactate. The other two are NADP-dependent enzymes with each also acting on either D-lactate or L-lactate (Vulliamy et al., 1993). Lactate dehydrogenase catalyzes the inter-conversion of pyruvate and lactate with concomitant inter-conversion of NADH and NAD⁺. It converts pyruvate, the final product of glycolysis to lactate when oxygen is absent or in short supply and it performs the reverse reaction during the Cori cycle in the liver. At high concentrations of lactate, the enzyme exhibits feedback inhibition and the rate of conversion of pyruvate to lactate is decreased.

It also catalyzes the dehydrogenation of 2-Hydroxybutyrate, but it is a much poorer substrate than lactate. There is little to no activity with beta-hydroxybutyrate (Butt, 2002). Elevated levels of LDH in some tissues may suggest enhanced carbohydrate metabolism, however, tissue breakdown also elevates the levels of LDH, and therefore a measure of it indicates, e.g., hemolysis. Other disorders indicated by elevated LDH include cancer, meningitis, encephalitis, acute pancreatitis, and HIV (Butt, 2002).

Increase in lactate dehydrogenase activity in these tissues may suggest that *Garcinia kola* increased carbohydrate metabolism through the Embden-meyerhof's pathway. The increase in the activity of these enzymes from the biochemical assay above are not sex dependent as both the female and the male sub-groups shows significant increase in the experimental groups.

ACKNOWLEDGEMENT

The authors wish to express their sincere gratitude to Professor E. A. Caxton-Martins of the Department of Anatomy, University of Ilorin, Kwara State, Nigeria for his guidance and technical assistance in the course of this study.

REFERENCES

- Adefule-Ositelu AO, Adegbehingbe BO, Adefule AK, Adegbehingbe OO, Samaila E, Oladigbolu K (2010). Efficacy of *Garcinia kola* 0.5% aqueous eye drops in patients with primary open-angle glaucoma or ocular hypertension. Middle East Afr. J. Ophthalmol., 17: 88-93.
- Adie VO (2008). Weekend magazine - Health extra 24th Ed: 32-38.
- Braide V, Vittrotio G (1989). Histological Alterations by a Diet Containing Seeds of *Garcinia kola*: Effects on liver, Kidney and intestine in the Rat. Gedenbaurs Morphol. Jahrb, Leipzig. 1334: 95-101.
- Butt AA (2002). LDH levels as a clue to the diagnosis of histoplasmosis. J. AIDS, 12(7): 317-21.
- Collins CE, Hendrickson A, Kaas JH (2005). Overview of the visual system of Tarsius Anat. Rec. J. Mol. Cell. Evol. Biol., 287(1):1013-1025.
- Corpas FJ (1998). A dehydrogenase-mediated recycling system of NADPH in plant peroxisome. J. Biochem., 330(7): 777-784.
- Hong XI, Song FL (2001). Activity of plant Flavonoids against Antibiotic-Resistant Bacteria. Phys. Res., 15: 39-43.
- Iwu M (1993). Handbook of African medicinal plants. CRC Press, Boca Raton, FL., 12: 32-38.
- Lewis WH, (1977). Medic Botany: Plants Effecting Mainsheath. New York: John Wiley – Int. Pub. 231 –232.
- Madubuyi II (1995). Antimicrobial activities of the constituents of *Garcinia kola* Seeds. Int. J. Pharm., 33(3): 232-237.
- Oguntola S (2009). Bitter kola nut extract, promising eye drop for glaucoma, apollo. Nigerian Tribune. 1121:2-3.
- Orie NN, Ekon EU (1993). The Bronchodilatory Effect of *Garcinia kola*. E. Afr. Med. J. 70:3.
- Sotoblanco RA, Aparicio MA (2002) Relationships between dietary cassava cyanide levels and Brain performance. J. Nutr. Reports Int., 37: 63-75.
- Vulliamy T, Beutler E, Luzzatto L (1993). Variants of glucose-6-phosphate dehydrogenase are due to missense mutations spread throughout the coding region of the gene. Hum. Mutat., 2(3): 159-67.