

*Full Length Research Paper*

# Anti-inflammatory activity of the venom from samsun ants *Pachycondyla sennaarensis*

M. A. Dkhil\*, A. S. Abdel-Baki, S. Al-Quraishi and M. Al-Khalifa

Zoology Department, College of Science, King Saud University, P. O. Box 2455, Riyadh 11451, Saudi Arabia.

Accepted 21 August, 2014

**Black ants considered as health hazard problem in many parts of the world. Sting of these ants caused local to systematic reactions and sometimes anaphylaxis. In this study, we proved that the black ant (samsun) venom exerts an anti-inflammatory action on mice model. It was proven that the venom inhibited xylene induced ear swelling in mice with a percentage nearly equal to that of diclofenac. This result was supported by the histological studies which revealed that venom reduced the thickness of the inflamed ears and the cellular infiltration.**

**Key words:** Samsun ant, venom, anti-inflammation, xylene induced ear swelling.

## INTRODUCTION

*Pachycondyla sennaarensis* (Mayr, 1862; Hymenoptera: Formicidae), commonly known as the samsun ant, was reported for the first time in Saudi Arabia in 1985 (Collingwood, 1985). Since that time, there have been further reports on their distribution especially in central area (Al-Shahwan et al., 2006). Sting of order Hymenoptera can cause reactions ranging from mild local reaction with painful erythromatous swelling to severe life

- threading anaphylaxis (Potier et al., 2009). The anaphylaxis effect of *P. sennaarensis* in Saudi Arabia was confirmed by Al-Shahwan et al. (2006). However, some reports proved that ant venom possesses many pharmacological effects as reducing inflammation, relieving pain, inhibition of tumor growth, proving the immunological function, liver protection and hepatitis treatment (Altman et al., 1984; Kou et al., 2005; Wang and Wu, 2006). It was confirmed that the venom of ants, *Polyrhachis lamellidens* exert a potent analgesic and anti-inflammatory action on mice models (Kou et al., 2005).

Although venom gland secretions have been studied in several species of genus *Pachycondyla*, the pharmacological activities and chemical constituents of Saudi Arabian populations of *P. sennaarensis* venom had not yet being assessed. In this work the anti-inflammatory effect of black (samsun) ant venom has

been investigated.

## MATERIALS AND METHODS

### Field collection, insect identification and dissection of the venom gland

Workers of *P. sennaarensis* were collected from south Riyadh, Saudi Arabia in June 2009. Identification of samsun ants were carried out according to Mayr (1862). Workers were dissected in distilled water using a binuclear microscope (Olympus SZX10, Soel, Korea). The sting apparatus was removed with a pair of forceps, by grabbing the last segment of the abdomen and detaching it with the sting apparatus. The venom gland was pinched out and placed in a small tube (Nikbakhtzadeh et al., 2009). Glands were homogenized, and then centrifuged at 1000 rpm for 2 min. The supernatant (venom) was collected.

### Animals

Male Swiss Albino mice weighing 20 - 35 g were obtained from the experimental animal center of King Saud University (Riyadh, Saudi Arabia). Mice were kept in plastic cages at 22 °C with free access to pellet food and water at a 12 h light/dark cycle. This study complied with current ethical regulations on animal research of our university and all animals used in the experiment received humane care.

### Xylene - induced ear edema in mice

The xylene - induced ear edema test was performed as described in Hosseinzadeh and Younesi (2002). Mice were divided into three

\*Corresponding author. E-mail: [mohameddkhil@yahoo.com](mailto:mohameddkhil@yahoo.com).  
Tel: 00966-552686399, 00966-14675754.

**Table 1.** Effect of the intraperitoneal doses of samsoum ant venom and diclofenac on xylene - induced ear swelling in mice.

Treatment	Dose	Swelling (mg)	Inhibition (%)
Control (saline)	10 ml/kg	13.2 ± 1.43	-
Diclofenac	15 mg/kg	8.6 ± 1.4*	34.8
Ant venom	10 µl/mouse	8.8 ± 0.85*	33.3

The increase in weight caused by the irritant (xylene) was measured by subtracting the weight of the untreated left ear section from that of the treated right ear sections. Values are the mean ± SD for 6 mice, \* $P < 0.001$ , compared to control (normal saline).

groups each of six mice. The first group was kept as a control group which intraperitoneally (i.p.) injected with normal saline (10 ml/kg). The second group was treated with 15 mg/kg diclofenac (HIKMA Pharmaceuticals, Amman, Jordan). The third group was treated with venom (10 µl/mouse).

Thirty minutes after i.p. injection of the venom and diclofenac, 30 µl of xylene was applied to the anterior surfaces of the right ear and another 30 µl to the posterior surface. The left ear was considered as control. Two hours after xylene application, mice were sacrificed and both ears were removed. Circular sections were taken, using a cork borer with a diameter of 7 mm, and weighed. The increase in weight induced by the irritant was measured by subtracting the weight of the untreated left ear section from that of the treated right ear sections.

### Histopathology

Biopsies from control and treated ears of mice in each treated group were collected and fixed in 10% formalin. Cross - sections of 7 µm were prepared. The sections were stained with hematoxylin and eosin (H and E) for the evaluation of leukocyte accumulation and edema. A representative area was selected for qualitative light microscopic analysis of the cell mediated inflammatory response.

### Statistical analysis

Statistical analysis was performed by using an unpaired Student's  $t$  test. The data were analyzed by using MS Excel 2003 (Microsoft, Rochester, NY, USA) and Sigma - Plot 2001 (Systat Software, Inc, Chicago, IL, USA).

## RESULTS

### Action of samsoum ant venom on cutaneous inflammation

We assessed the anti - inflammatory activity of samsoum ant venom through xylene induced ear edema in mice. The venom of *P. sennaarensis* markedly inhibited xylene induced ear swelling in mice with inhibition percentage nearly equal to that of diclofenac (Table 1 and Figure 1). Increased skin weight is often the first hallmark of skin irritation and local inflammation due to xylene application. Xylene induced skin inflammation, including increased vascular permeability, edema and swelling within the dermis, and proliferation of epidermal keratinocytes. Intraperitoneally injection of 10 µl samsoum ant venom

significantly decreased ear weight ( $P < 0.001$ ), indicating the anti - inflammatory effect of this venom (Table 1 and Figure 1).

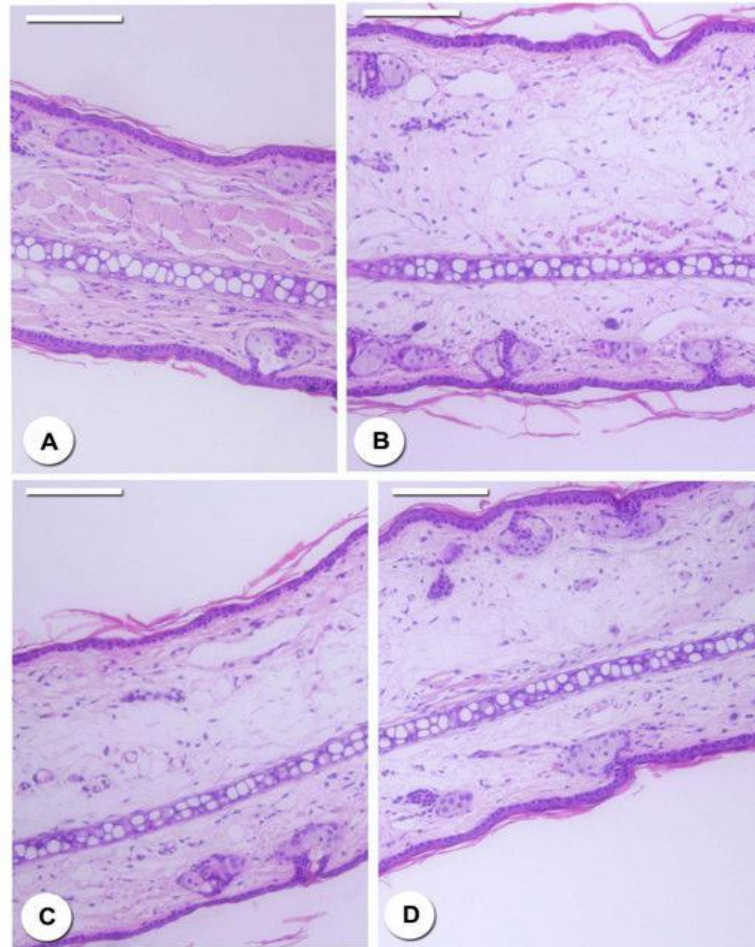
### Histological assessment of cutaneous inflammation

Xylene application resulted in a marked increase in ear thickness, with clear evidence of edema, epidermal hyperplasia, and substantial inflammatory cell infiltration in the dermis with accompanying connective tissue disruption compared to the control group (Figures 1a and b). Venom treatment reduced ear thickness and the associated pathological alterations to an extent comparable to the positive control treated with diclofenac (Figures 1c and d). These results directly illustrate the effects of venom within the target tissue.

## DISCUSSION

*P. sennaarensis* had been reported from all Arab gulf countries including Saudi Arabia. It stings human beings as a defensive behavior (Al Anazi et al., 2009). This ant has been observed around and inside houses in many localities in Riyadh region (Al Anazi et al., 2009). Ants have been used as medicine, owing to their special active substances such as citral, ATP, histamine, growth hormone, testosterone and superoxide dismutase etc. (Kou et al., 2005). *P. lamellidens*, a medicinal ant used in Chinese medicine, was confirmed to exert potent analgesic and anti - inflammatory actions. Its therapeutic efficacy in the treatment of various inflammatory disorders had been reported (Kou et al., 2005).

This study provides evidence that samsoum ant venom acts as an anti-inflammatory agent in mice. Xylene - induced inflammation test proved this anti-inflammatory action which is similar to the non steroidal anti - inflammatory drug (NSAID), Diclofenac. It is a well established fact that NSAIDs exert their analgesic and anti - inflammatory activity by the inhibition of cyclooxygenase activity (Vane, 1971; Miura et al., 1991; El-Banhawy et al., 1993; McCafferty et al., 1995; Waterbury et al., 2006). This was supported by observed reductions in skin thickness and weight, amelioration of several histopathological indicators. The increase in weight and inflammation exerted by xylene application is due to



**Figure 1.** Cutaneous induced inflammation with xylene and the anti-inflammatory action of *P. sennaarensis* venom. Histological sections in control ear (A), ears harvested 2h post treatment with saline (B), Diclofenac (C) and venom (D). Note the edema, polymorphonuclear cell influx and epidermal hyperplasia in saline treated mice and the reduction in inflammatory cells and edema in ears in diclofenac and venom treated mice. Sections from five animals in each group are shown. Sections stained with H and E, Scale - bar = 25 m.

neutrophil accumulation which plays a critical role in cutaneous inflammatory diseases such as dermatitis, and is related to the pathological mechanism of the disease (Bradley et al., 1982). The venom gland secretions of *Pachycondyla* species are known to contain a variety of volatiles, making the members of this genus distinctive among the ponerine ants. The main volatile components of the venom gland of samsum ants were phenol-2, 4-bis (1, 1 dimethylethyl) and trimethyl pyrazine (Nikbakhtzadeh et al., 2009) but the main chemical components is still unknown.

It is concluded that samsum ant venom has an anti-inflammatory effects; however, the chemical constituents and the mechanism responsible for the pharmacological activities remain to be investigated. This may be an important therapeutic strategy for the treatment of inflammatory skin diseases.

## ACKNOWLEDGEMENTS

We would like to thank Fahd Al-Mekhlafi, Mahmoud Metwaly and Mostafa Abdel Maksoud for extraordinary technical assistance. This research was supported by King Saud University through the Nobel Laureate collaboration project; number (NLCP-1/2009). We, therefore, thank the Nobel laureate, Prof. Günter Blobel (Laboratory of Cell Biology, Howard Hughes Medical Institute the Rockefeller University, New York).

## REFERENCES

- Al Anazi M, Alashahrani M, Alsalamah M (2009). Black ant stings caused by *Pachycondyla sennaarensis*: a significant health hazard. *Ann. Saudi Med.* 29: 207-211.
- Al-Shahwan M, Al-Khenaizan S, Al-Khalifa M (2006). Black (samsun)

- ant induced anaphylaxis in Saudi Arabia. Saudi med. J. 27: 1761-1763.
- Altman RD, Schultz DR, Collins-Yudiskas B, Aldrich J, Arnold PI, Brown HE (1984). The effect of a partially purified fraction of ant venom in rheumatoid arthritis. Arthritis Rheum. 27: 277-285.
- Bradley PP, Priebat DA, Christensen RD, Rothstein G (1982). Measurement of cutaneous inflammation: estimation of neutrophil content with an enzyme marker. J. Invest. Dermatol. 78: 206-209.
- Collingwood CA (1985). Hymenoptera: Fam. Formicidae of Saudi Arabia. Fauna of Saudi Arabia. 7: 230-302.
- El-Banhawy MA, Sanad SM, Sakr SA, El-Elaimy IA, Mahran HA (1993). Histopathological studies on the effect of the anticoagulant rodenticide "Brodifacoum" on the liver of rat. J. Egypt. Ger. Soc. Zool. 12: 185-227.
- Hosseinzadeh H, Younesi HM (2002). Antinociceptive and anti-inflammatory effects of *Crocus sativus* L. stigma and petal extracts in mice. B. M. C. Pharmacol. 15: 2-7.
- Kou J, Ni Y, Li N, Wang J, Liu L, Jiang ZH (2005). Analgesic and anti-inflammatory activities of total extract and individual fractions of Chinese medicinal ants *Polyrhachis lamellidens*. Biol. Pharm. Bull. 28: 176-180.
- McCafferty D, Granger DN, Wallace JL (1995). Indomethacin-induced gastric injury and leukocyte adherence in arthritic versus healthy rats. Gastroenterol. 109: 1173-1180.
- Miura S, Suematsu M, Tanaka S, Nagata H, Houzawa SI, Suzuki M, Kurose I, Serizawa H, Tsuchiya M (1991). Microcirculatory disturbance in indomethacin-induced intestinal ulcer. Am. J. Physiol. 24: 213-309.
- Nikbakhtzadeh MR, Tirgari S, Fakoorziba HA (2009). Two volatiles from the venom gland of the Samsun ant, *Pachycondyla Sennaarensis*. Toxicon. 54: 80-82.
- Potier A, Lavigne C, Chappard D, Verret JL, Chevailler A, Nicolie B, Drouet M (2009). Cutaneous manifestations in Hymenoptera and Diptera anaphylaxis: relationship with basal serum tryptase. Clin. Exp. Allergy. 39: 717-725.
- Vane JR (1971). Inhibition prostaglandine synthesis as a mechanism of action for aspirin-like drugs. Nature New Biol. 231: 232-235.
- Wang CP, Wu YL (2006). Study on mechanism underlying the treatment of rheumatoid arthritis by Keshiling. Zhongguo Zhong Yao Za Zhi 31: 155-158.
- Waterbury LD, Silliman D, Jolas T (2006). Comparison of cyclooxygenase inhibitory activity and ocular anti-inflammatory effects of ketorolac tromethamine and bromfenac sodium. Curr. Med. Res. Opin. 22: 1133-1140.