

Full Length Research Paper

# Toxicity of glyphosate herbicide on Nile tilapia (*Oreochromis niloticus*) juvenile

Ayoola S.O

Department of Marine Sciences, University of Lagos, Akoka, Yaba, Lagos State, Nigeria  
E-mail: [soaayoola@yahoo.com](mailto:soaayoola@yahoo.com). Tel: 234-0803-4650102.

Accepted 24 November, 2015

Fish are particularly sensitive to a wide variety of agrochemicals including glyphosate herbicide that may arise from not only deliberate discharge of these chemicals into waterways but also from approved agricultural practices. In the present study, the toxicity of glyphosate an herbicide was investigated with emphasis on histopathological effects. Nile tilapias (*Oreochromis niloticus*) juvenile  $15 \pm 1.0$  g were exposed to 0, 2, 9, 30, 97, 310 mg/l of glyphosate. The lethal concentration ( $LC_{50}$ ) value of glyphosate was 1.05 mg/l for 96 h of exposure. Glyphosate concentration corresponding to the 96 h  $LC_{50}$  values for juvenile tilapia was used to study the effects of glyphosate exposure for 4 days in inducing histopathological changes of gills, livers, kidneys and brains. In the gills, filament cell proliferation, lamellar fusion, lamellar cell hyperplasia, and epithelial lifting were observed. In the liver, there was vacuolation of hepatocytes and necrosis. Kidney lesion consisted of hyaline droplets in the tubular epithelial cells and pkynosis. The brain lesion also consisted of generalized neuronal degeneration and spongiosis. The changes in these tissues occur predominantly in the 96 h exposure. Respiratory stress, erratic swimming and instant death of fish were observed in exposed fish, which varied with the concentration of the toxicant and this showed that mortality increased with increase in concentration. Glyphosate is highly toxic to Nile tilapias, which are more susceptible to this herbicide; therefore their use near fish farm or in area close to aquatic environment should be discouraged.

**Key words:** Nile tilapia, *Oreochromis niloticus*, glyphosate toxicity, histopathology.

## INTRODUCTION

The constant flow of agricultural effluent discharge into water bodies often leads to a variety of pollutant accumulation, which becomes apparent when considering toxic pollution (Mason, 1991). The application of environmental toxicology studies on non-mammalian vertebrates is rapidly expanding for the evaluation of the effects of noxious compounds. The indiscriminate use of herbicide, careless handling, accidental spillage, or discharges of treated effluents into natural waterways have harmful effects on the fish population and other forms of aquatic life and may contribute long term effects in the environment (Akhtar, 1986).

Herbicides are widely used for the control of water plants, which may impede the flow of water during the summer, when sudden heavy rain can cause flooding (Annune et al., 1994). While the direct effect of herbicides addition is the loss of macrophytes, non-target organisms such as fish may also be affected through loss of habitat and food supply (Ervnest, 2004). Gigurlyphosate, the active ingredient which is the 48% acid equivalent, of the

isopropylamine salt of glyphosate (N-phosphonomethyl glycine), is used as a non-selective herbicide and for control of a great variety of annual, biennial, and perennial grasses, sedges, broad-leaved weeds, and woody shrubs. They are also used in fruits orchards, vineyards, conifer plantations and many plantation crops. It is perhaps the most important herbicide ever developed (WHO, 1994). Because of its low persistence, repeated applications of this herbicide are practiced for the control of weeds in agricultural fields and thereby, large quantities find their ways into the water bodies. However, only a few reports have described its effects on fresh water fish (Mitchell et al., 1987; Servizi et al., 1989).

Nile tilapia (*O. niloticus*) is one of the most important commercially cultured tilapia species indigenous to Nigeria. The juvenile of this species was used because of its economical importance, and easy handling in laboratory (Omitoyin et al., 2006). In view of the poor knowledge of the aquatic side-effects of this agrochemical, the objective of this study is to determine

the lethal concentration and the acute toxic effects of glyphosate herbicide on Nile tilapia (*O. niloticus*) with emphasis on the histological changes in the gills, livers, kidney and brains.

## MATERIALS AND METHODS

Five hundred juvenile of Nile tilapia (*O. niloticus*) with the mean weight  $15 \pm 0.1$  g and standard length range of  $8.1 \pm 0.3$  cm, obtained from university of Ibadan research fish farm, Ibadan, Nigeria were used for toxicity tests. This is due to the more sensitive nature of juveniles than adult for toxicity test (Reish and Oshida, 1987; Solbe, 1995; Odiette, 1999). The fish were acclimatized in the laboratory conditions for four weeks during which they were fed with commercial floating pellets at 10% (crude protein) of their body weight. Unconsumed feed and faecal were removed and water replenished regularly as recommended by Oyelese and Faturoti (1995). The water's temperature was  $26 \pm 0.80^\circ\text{C}$ , pH was 7.0, and dissolved oxygen was  $6.3 \pm 0.1$  mg/l. Temperature reading was taken by the use of digital Hanna instrument Ph211 microprocessor Ph meter. The hydrogen ion concentration was measured using Hanna instrument Ph211, microprocessor pH meter. The dissolved oxygen level of the water was taken with the Griffin oxygen (model 40). The reading on the meter was used in calculating the actual dissolved oxygen level of the water. The formular used was,

$$\text{DO} = \frac{S \times P}{100} \text{ mg/l}$$

Where S = conversion of percentage saturation to ppm.  
P = Reading obtained on the meter

### Acute toxicity tests

A static renewal bioassay technique (ASTM 729- 90(1990)) was adopted in which the test media was renewed at the same concentration once every 24 h. Preliminary screening was carried out to determine the appropriate concentration range for testing chemical as describe by Solbe (1995). Ten fish per concentration of toxicant were used with 3 replicates each for 96 h. Based on this; six concentrations of the herbicide were prepared and tested on fish for the definitive test.

A static renewal bioassay technique was adopted and the concentrations used for the definitive test were 0, 2, 9, 30, 79, 310 mg/l. Ten acclimated fish were used in each aquarium containing different concentrations of glyphosate as well as in the control (0 mg/l) as described by Solbe (1995) and Rahman et al. (2002). This was done in an attempt to maintain a more constant concentration of test media to which test animals were exposed and to prevent excessive accumulation of toxic metabolites. At the beginning of the tests and every

30 minutes, behavioural changes and the number of dead fish were recorded. Other external changes in the body of the fish were observed accordingly. Dead fishes were promptly removed and preserved in 10% formaldehyde. The organs (gills, livers, kidneys and brains) were removed and prepared for histopathological observation. They were fixed in bouin's fluid for 24 h, washed with 70% ethanol and dehydrated through a graded series of ethanol (Kelly, 1979; Schalm et al., 1995). They were embedded in paraffin, sectioned at 4 – 5  $\mu\text{m}$  thickness, stained with hematoxylin and eosin and examined using light microscope and photomicrography (Keneko, 1989). The median lethal concentration ( $\text{LC}_{50}$ ) at 96 h was computed using the probit, logit analysis and ANOVA.

## RESULT

The mean physico-chemical parameters of the test concentrations (glyphosate) on fish are presented in Table 1, while the effect of different concentrations and exposure time of glyphosate on fish are presented in Table 2. There were significant relationship ( $p < 0.05$ ) between the temperature, pH and dissolved oxygen with glyphosate toxicity.

### Toxicity of glyphosate

The  $\text{LC}_{50}$  value based on probit analysis was found to be 1.05 mg/l for 96 h and is presented in Figure 1. Linear relationship between the probit mortality and the concentration of glyphosate indicated a positive correlation and showed a significant difference at  $p < 0.05$  indicating that mortality rate of exposed fish increased as the concentration of glyphosate increased. No adverse behavioural changes or any mortality were recorded in the control fish throughout the period of the bioassay. The behaviour of the control fishes and their colour were normal. Symptoms of toxicosis observed in fish behaviour with glyphosate include lack of balance; agitated or erratic swimming, air gulping, restlessness, sudden quick movement, excessive secretion of mucus, rolling movement, and swimming on the back were observed. The exposed fish became very weak, settled at the bottom and died and the skin colour was shining.

### Histopathological studies

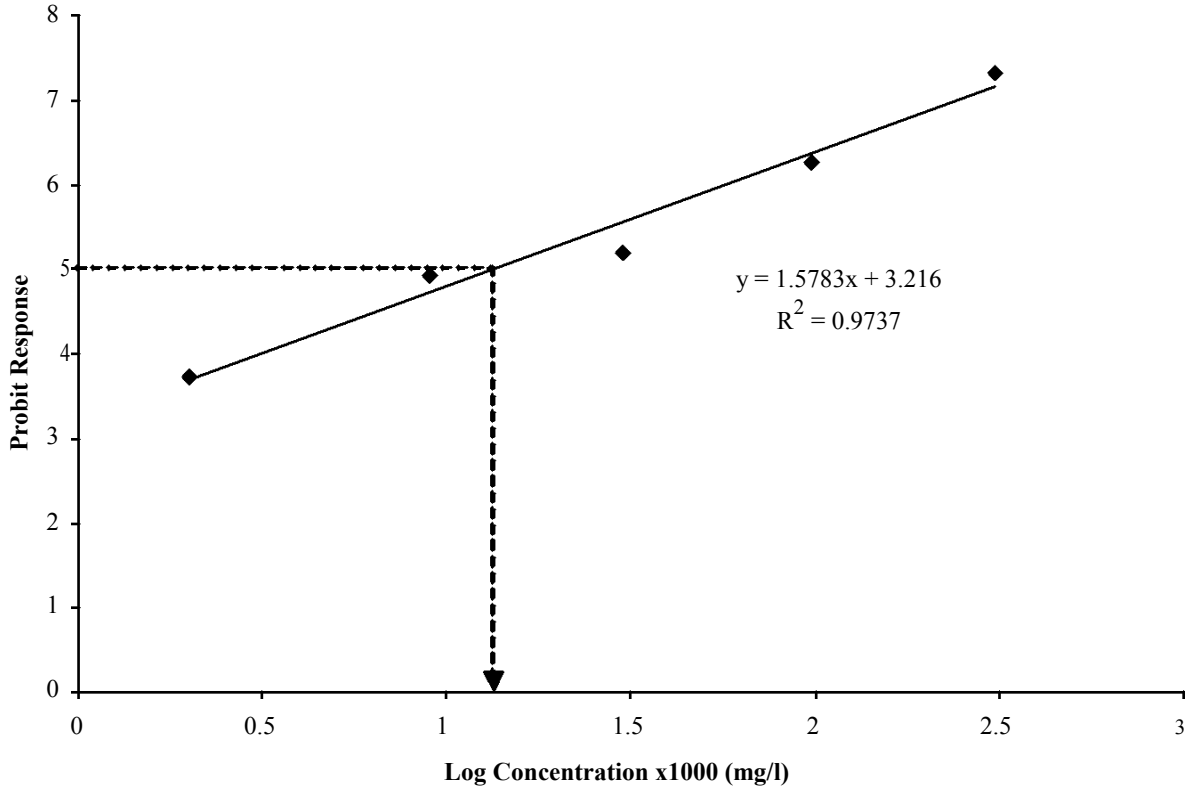
Summary of histopathological changes observed in the gills, livers kidney and brains of *O. niloticus* subjected to different concentration of glyphosate for 96 h is presented in Table 3. The photomicrography state of treated and control organs such as gills, Kidney, liver, and brain are presented in plates of group 1-4.

#### Gills

No recognizable changes were observed in the gills of the control fish. Each gill consisted of a primary lamellar filament and secondary lamellae (Plate 1a) . The primary lamellar epithelium was one or two cell layers thick. Chloride cells were visible along the primary lamellar epithelium, especially at the basis of secondary Lamellae. Light microscopic study of the gills of Nile tilapia exposed to glyphosate showed several pathological changes and their frequencies increased with increasing the exposure time. At different concentrations of glyphosate for 96 h exposure, there were cellular infiltration, irregular lamella (Plate 1b-1f) epithelium and neurosis of the gill.

#### Liver

The histology of control fish liver revealed the typical



**Figure 1.** Linear relationship between probit response and log concentration of glyphosate on juveniles of *Oreochromis niloticus*

**Table 1.** Mean physico-chemical parameters of the test concentrations (glyphosate) on *Oreochromis niloticus* for 96 h period.

Glyphosate Conc. (mg/l)	Physico- chemical parameters		
	DO <sub>2</sub> (mg/l)	pH	Temp °C
0.00	6.3 ± 0.1 <sup>e</sup>	7.0 ± 0.1 <sup>b</sup>	26.0 ± 0.8 <sup>a</sup>
2	6.0 ± 0.4 <sup>d</sup>	7.0 ± 0.2 <sup>b</sup>	27.0 ± 1.3 <sup>b</sup>
9	5.9 ± 0.3 <sup>c</sup>	6.9 ± 0.3 <sup>a</sup>	26.9 ± 1.6 <sup>b</sup>
30	5.8 ± 0.1 <sup>b</sup>	6.9 ± 0.1 <sup>a</sup>	27.0 ± 0.2 <sup>b</sup>
97	5.8 ± 0.4 <sup>b</sup>	6.9 ± 0.2 <sup>a</sup>	27.2 ± 1.6 <sup>b</sup>
310	5.7 ± 0.5 <sup>a</sup>	6.9 ± 0.2 <sup>a</sup>	27.5 ± 1.7 <sup>c</sup>

\*Mean values followed by the superscript in each column are not significant different (p<0.05).

parenchymatous appearance (Plate 2a). At the light microscopic level, the liver was divided into irregularly shaped lobules separated by the hepatopancreas and bile duct. The liver was made up of hepatocytes that were polygonal cells with a central spherical nucleus and a densely stained nucleolus. The fish liver exposed to glyphosate at different concentration (Plate 2b-2f) showed extensive pyknosis, and involution exhibiting

darkly stained specks of necrotic nuclei, as well as infiltration of leukocytes.

### Kidney

No recognizable changes were observed in the kidney of the control fish (Plate 3a). At the light microscopic level, the renal corpuscle was composed of the glomerulus's and Bowman's capsule. The first proximal tubule was composed of cuboidal or low columnar cells with a well-developed brush border containing vacuoles and round-based nuclei. The kidney exposed to different concentrations showed lesions of varying degrees (Plate3b-3f). Some glomerulus's were collapsed or distorted. Some of the cells were necrotic with small pyknotic nuclei and focal fibrosis.

### Brain

There were no recognizable changes on the brain of the control fish (Plate 4a). No discolouration and any morphological change on the brain of control fish. The histopathological observation on the brain showed that there was discolouration on the brain of fish exposed to different concentration of glyphosate. Fish exposed to glyphosate indicated severe congestion and mononuclear infiltration, haemorrhage and generalized spongiosis

**Table 2.** Rate of mortality of Nile tilapia juvenile on exposure to glyphosate pre treatment

Treatment /Hr	1	3	6	9	12	15	18	21	24	27	30	33	36	42	45	48	51	54	57	60	63	66	69	72	75	78	81	84	87	90	93	96	Total mortality	% mortality	
T <sub>0A</sub>																																	00	00	
T <sub>0B</sub>																																		00	00
T <sub>0C</sub>																																		00	00
T <sub>1A</sub>																									00								01	01	10
T <sub>1B</sub>																									01								01	02	20
T <sub>1C</sub>																									00								00	00	0
T <sub>2A</sub>																					01		00										01	02	20
T <sub>2B</sub>																					01		00										01	03	30
T <sub>2C</sub>																					01		01										01	03	30
T <sub>3A</sub>											01					01							01		01	00							00	04	40
T <sub>3B</sub>											00					01							00		00	01							01	03	30
T <sub>3C</sub>											01					01							00		00	01							01	04	40
T <sub>4A</sub>						01		02	01				01			01				01		00											01	08	80
T <sub>4B</sub>						00		01	00				01			01				01		01											01	07	90
T <sub>4C</sub>						01		01	01				01			01				01		01											01	08	80
T <sub>5A</sub>				02		01		01		01			02			00				01				00									01	10	100
T <sub>5B</sub>				01		01		01		01			01			01				01				02									01	10	100
T <sub>5C</sub>				01		01		01		00			01			01				01				01									02	10	100

T<sub>0</sub> = Control treatment without toxicant, T<sub>1</sub> = 2mg/l of toxicant, T<sub>2</sub> = 9mg/l of toxicant, T<sub>3</sub> = 30 mg/l of toxicant, T<sub>4</sub> = 97mg/l of toxicant

(Plate4b-4f).

## DISCUSSION

Glyphosate is one of the widely used herbicides that could be persistent and mobile in soil and water, and it is known to be one of the most common terrestrial and aquatic contaminants (Cox, 1998).

The LC<sub>50</sub> values of glyphosate vary widely from 2 to 5 ppm. These values have been depending on fish species and the test conditions (WHO, 1994). The present study showed that the 96 h LC<sub>50</sub> value of glyphosate herbicide was 1.05 mg/l. This value was within the concentration ranges reported in the previous studies. Glyphosate toxicity increased with increased concentration.

The observation is in consonance with earlier reports (GESAMP, 1991; WHO, 1994; Cox, 1998). Neibor and Richardson (1980) reported that the level of toxicity of any pesticide depends on its bioaccumulation, the different chemistries of the compound forming the pesticide and the reactions of the organisms receiving the toxicant. The physico-chemical parameters measured were fluctuated slightly during the toxicity test.

The values were normal for fish rearing. There was a significant negative correlation between pH and dissolved oxygen values. In case of dissolved oxygen, the treatments did not only show a dose dependent decline in concentration, but also rapid depletion of dissolved oxygen with time. Warren (1977) had earlier reported that the introduction of a toxicant into

an aquatic system might decrease the dissolved oxygen concentration, which will impair respiration leading to asphyxiation. Fish were stressed progressively with time before death. The stressful behaviour of respiratory impairment due to the toxic effect of glyphosate on the gills was similar with the report of Omitoyin et al. (2006) and Aguigwo (2002) that herbicide impair respiratory organ. Death could therefore have occurred either by direct poisoning or indirectly by making the medium uncondusive or even by both.

Several abnormal behaviour such as incessant jumping and gulping of air, restlessness, surface to bottom movement, sudden quick movement, resting at the bottom were similar to the observations of

Omoniyi et al. (2002), Rahman et al. (2002) and Aguigwo (2002). The stressful and

**Table 3.** Summary of histopathological changes observed in the gill, liver and kidney of *Oreochromis niloticus* juveniles subjected to different concentrations of glyphosate (force-up) for 96 h.

Glyphosate Concentration	Hour of Merit	Organs	Congestion	Necrosis	Cellular Infiltration	Spongiosis	Pyknosis	Hemorrhage
O (Control) mg/l	96	G	-	-	-	-	-	-
		L	-	-	-	-	-	-
		K	-	-	-	-	-	-
2 mg/l	96	G	-	-	½	-	-	-
		L	-	½	-	-	-	-
		K	-	-	-	-	½	-
9 mg/l	96	G	+	-	+	-	-	+
		L	-	+	-	-	-	½
		K	-	-	-	-	+	½
30 mg/l	96	G	+	-	+	-	-	+
		L	-	++	-	-	-	+
		K	+	+	-	-	+	+
97 mg/l	96	G	++	+	++	-	-	+
		L	-	++	+	-	-	+
		K	+	+	+	-	++	+
310mg/l	96	G	++	+	++	½	-	++
		L	½	++	+	-	+	++
		K	+	++	+	-	++	++

**Key:** G = Gill, L = Liver, K = Kidney, - = Completely absence, + = Present, ½ = Mild, ++ = Severe.

**Note:** Treatment with negative signs indicated no histopathological changes were observed.

erratic behaviour of fish in the present study indicated respiratory impairment, probably due to the effect of the glyphosate herbicide on the gills. The fish became inactive at higher concentrations with increased time of exposure to toxicant and this is a normal observation in acute and chronic toxicity test (Kulakkattolickal and Kramer, 1997).

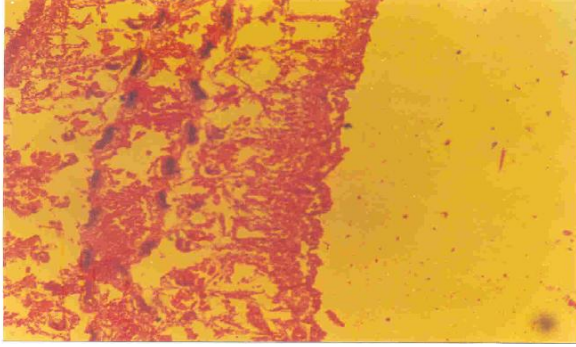
It was also observed that the higher the concentration of the toxicant, the higher the mortality rate. This demonstrates the observation of Fryer (1977) who found that in all toxicant; a

threshold is reached above which there is no drastic survival of animal. Below the threshold, animal is in a tolerance zone, above the tolerance zone is the zone of resistance. The time of toxicity disappearance and mortality were observed from the record of the relative mortality time in different concentrations of glyphosate for 96 h. The histopathological examination of the brain, liver, gill, and kidney of the exposed fish indicated that the liver and kidney were the organs mostly affected. Damages of the gills indicated

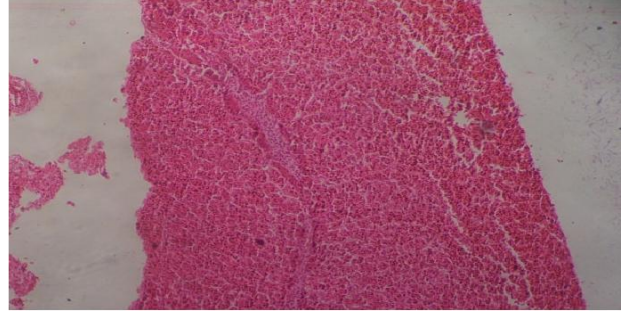
that the lethal concentrations of herbicide caused impairment in gaseous exchange efficiency of the gills.

The literature on histopathological effects of glyphosate on fish is extremely sparse. Neskovic et al. (1996) conducted sub acute toxicity test (14 days) of sublethal glyphosate concentrations on histopathological changes of carp organs such as gills, livers, and kidneys. In fish exposed to glyphosate concentration (96 h LC<sub>50</sub>) in the present study, the major changes of the gills were

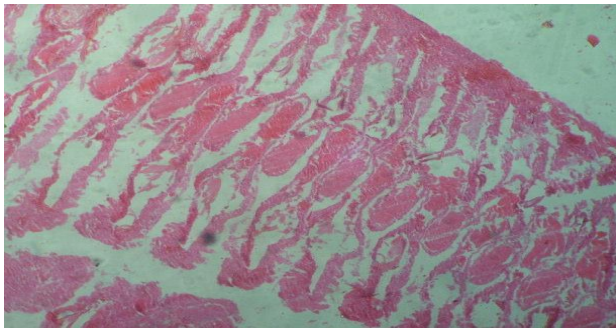




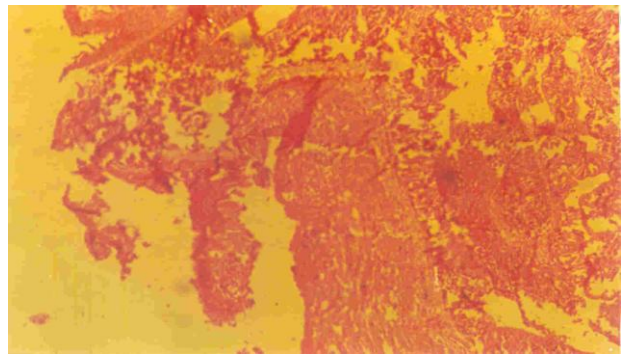
**Plate 1a.** Gill of *O. niloticus* X25. The exposed in the control group no lesion was seen in the primary lamellae



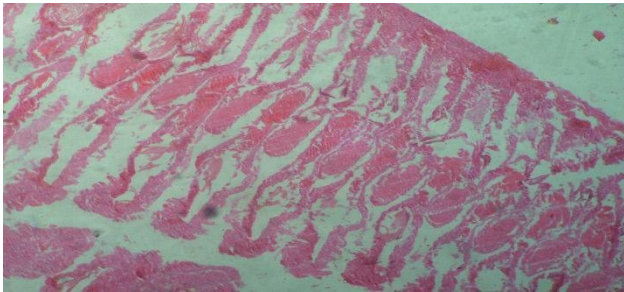
**Plate 1e.** Gill of *O. niloticus* X25. The 96 h exposed at 97 mg/l (glyphosate) showing severe cellular infiltration.



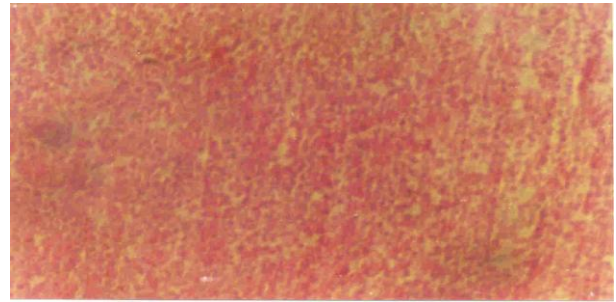
**Plate 1b.** Gill of *O. niloticus* X25. The 96 h exposed at 2 mg/l (glyphosate) showing mild cellular infiltration.



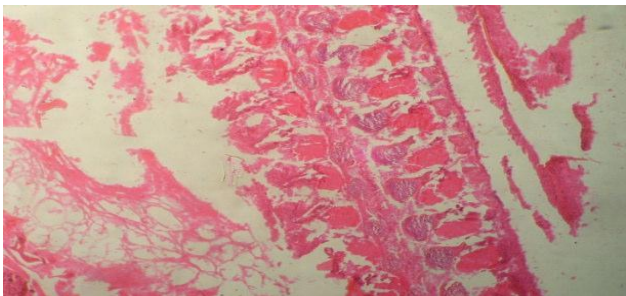
**Plate 1f.** Gill of *O. niloticus* X25. The 96-h exposed at 310mg/l (glyphosate) showing severe necrosis and oedema.



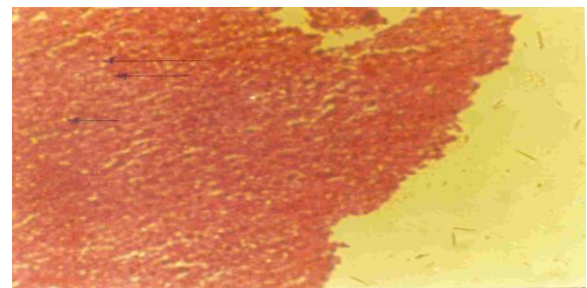
**Plate 1c.** Gill section of *O. niloticus* X25. The 96 h exposed at 9 mg/l (glyphosate) showing cellular infiltration.



**Plate 2a.** Liver of *O. niloticus* X25. The 96 h exposed in the control group no significant lesion seen.

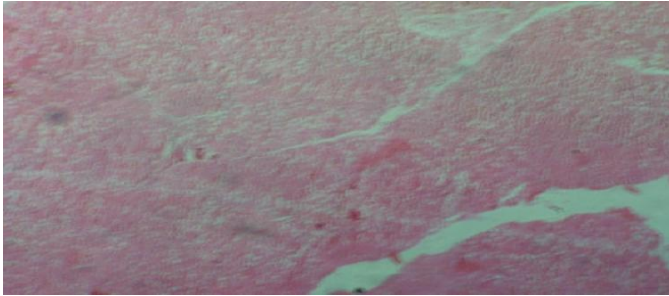


**Plate 1d.** Gill section of *O. niloticus* X25. The 96 h exposed at 30 mg/l (glyphosate) showing irregular lamellar epithelium.

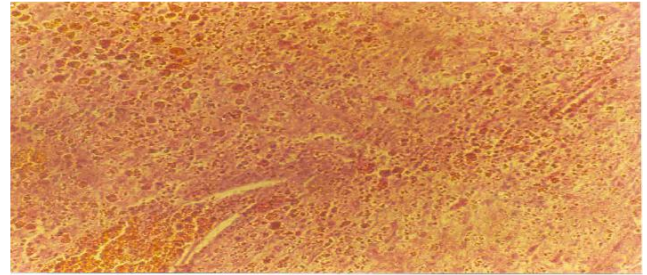


**Plate 2b.** Liver of *O. niloticus* X25. The 96 h exposed at 2 mg/l (glyphosate) showing glycogen vacuolation.

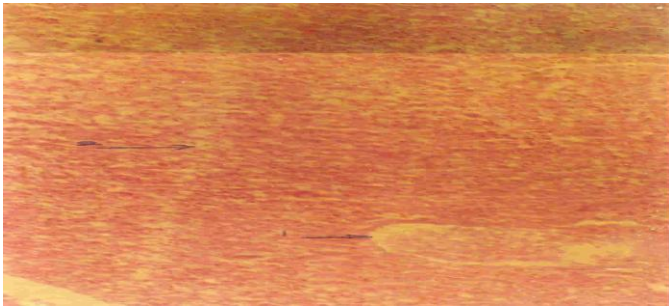




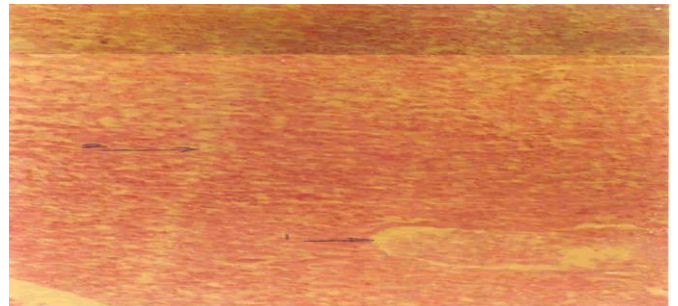
**Plate 2c.** Liver of *O. niloticus* X25. The 96 h exposed at 9 mg/l (glyphosate) showing severe fat vacuolation.



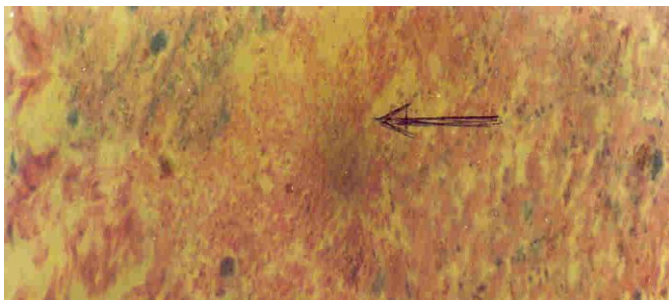
**Plate 3a.** Kidney section of *O. niloticus* X25. The 96 h exposed in the control group no significant.



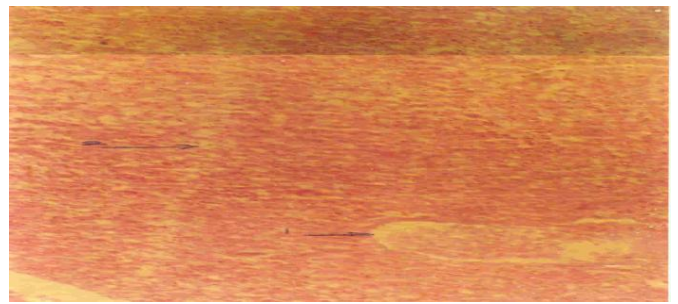
**Plate 2d.** Liver of *O. niloticus* X25. The 96 h exposed at 30 mg/l (glyphosate) showing  
1). Congested central vein  
2). Hydropic degeneration



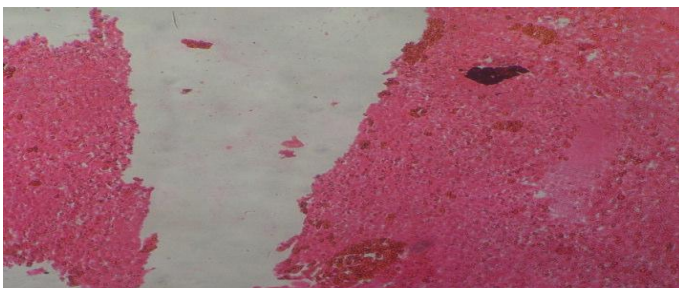
**Plate 3b.** Kidney section of *O. niloticus* The 96 h exposed at 2 mg/l showing mild pyknotic nuclei.



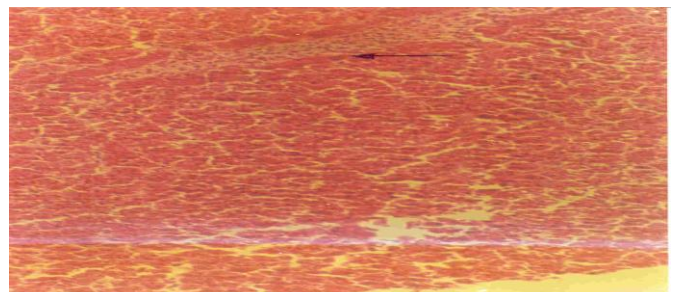
**Plate 2e.** Liver of *O. niloticus* X25. The 96-h exposed at 72 mg/l (glyphosate) showing severe infiltration of leukocytes (arrow) pyknotic (N) and lipid vacuoles (L)



**Plate 3c.** Kidney section of *O. niloticus* X25. The 96 h exposed at 9 mg/l (glyphosate) showing congestion and mild pyknosis.

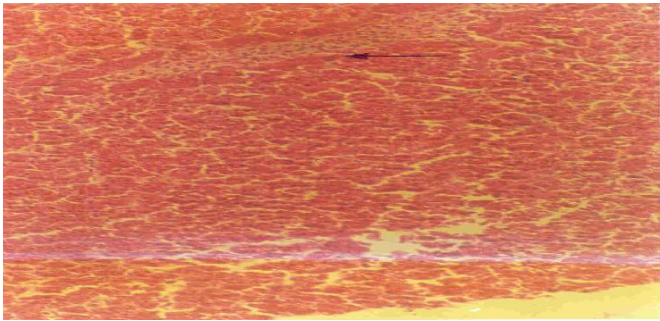


**Plate 2f.** Liver of *O. niloticus* X25. The 96 h exposed at 310 mg/l (glyphosate) showing diffuse hepatic necrosis

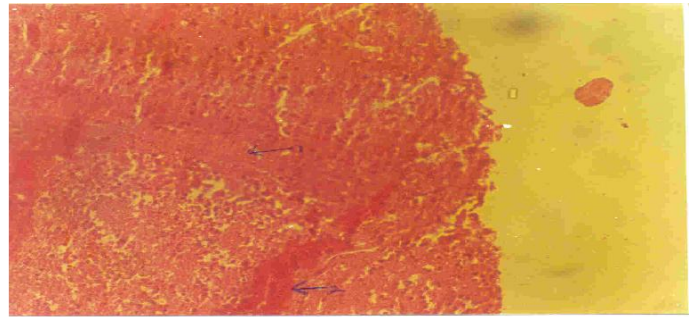


**Plate 3d.** Kidney section of *O. niloticus* X25. The 96 h exposed at 30 mg/l (glyphosate) showing pyknosis

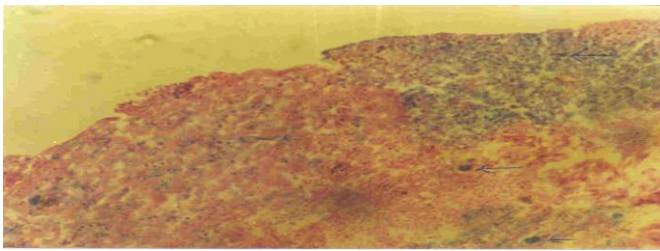




**Plate 3e.** Kidney section of *O. niloticus* X25. The 96 h exposed at 97 mg/l (glyphosate) showing and exfoliated severe pyknosis.



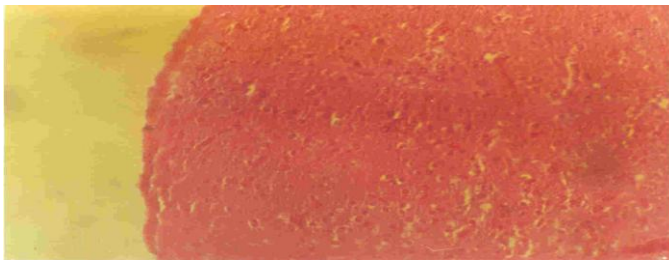
**Plate 4c.** Brain section of *O. niloticus*. The 96 h exposed at 9 mg/l (glyphosate) showing severe congestion and mononuclear infiltration.



**Plate 3f.** Kidney section of *O. niloticus* X25. The 96 h exposed at 310 mg/l (glyphosate) showing hyaline droplets (arrows) small vacuoles and severe pyknotic nuclei.



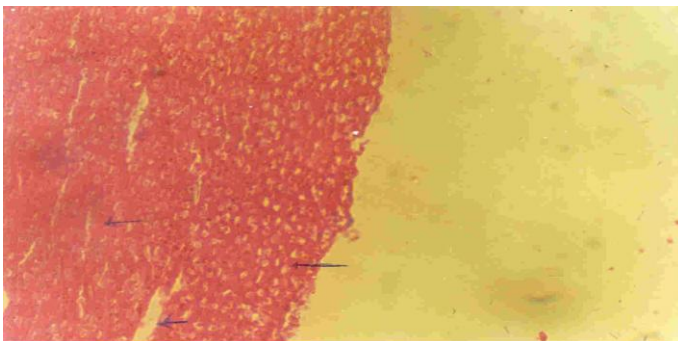
**Plate 4d.** Brain section of *O. niloticus*. The 96 h exposed at 30 mg/l (glyphosate) showing spongiosis



**Plate 4a.** Brain of *O. niloticus* X25. The 96 h exposed in the control group no significant lesion was seen.



**Plate 4e.** Brain section of *O. niloticus*. The 96 h exposed at 30 mg/l (glyphosate) showing cellular infiltration and spongiosis



**Plate 4b.** Brain section of *O. niloticus*. The 96-h exposed at 2mg/l (glyphosate) showing severe congestion mononuclear Infiltration.



**Plate 4f.** Brain section of *O. niloticus*. The 96 h exposed at 30mg/l (glyphosate) showing severe spongiosis.



Oedema, epithelial lifting, and thickening of the primary lamellar epithelium and fusion of secondary lamellae. Histopathological changes of gill such as hyperplasia and hypertrophy, epithelial lifting, aneurysm and increase in mucus secretion have been reported after the exposure of fish to a variety of noxious agents in the water, such as pesticides, phenols and heavy metals (Nowak, 1992).

In the present study, the liver of fish exposed to glyphosate concentration showed an infiltration of leukocytes, increasing hepatocyte size with pykrotic nuclei and presence of vacuoles. In the study of Risbourg and Bastide (1995), the exposure of fish to atrazine herbicide increased in the size of lipid droplets, vacuolization in the liver. The most frequent encountered types of degenerative changes are those of hydropic degeneration, cloudy swelling, vacuolization and focal necrosis. The liver of the exposed fish had slightly vacuolated cells showing evidence of fatty degeneration. Necrosis of some portions of the liver tissue that were observed probably resulted from the excessive work required by the fish to get rid of the toxicant from its body during the process of detoxification by the liver. The inability of fish to regenerate new liver cells may also have led to necrosis. In the present study, the kidney of fish exposed to glyphosate concentrations showed dilation of Bowman's space and accumulation of hyaline droplets in the tubular epithelial cells of the first proximal tubule. Oulmi et al. (1995) studied the effects of linuron herbicide on the rainbow trout (*Oncorhynchus mykiss*) and their results showed small cytoplasmic vacuoles, nuclear deformation in the epithelium of the first and second segments of the proximal tubule. The kidney cells were observed to have been massively destroyed. The renal corpuscles of the kidney were scattered resulting in their disorganization and consequently obstruction to their physiological functions. Some of the kidney cells were found clogging together while they were disintegrated in some tissues of the organ. This also agrees with the findings of Omoniyi et al. (2002), and Rahman et al. (2002). The brain also indicated severe congestion and generalized spongiosis that indicate severe brain damage. These findings agreed with those of Omitoyin et al. (2006).

## Conclusion

This study revealed that glyphosate herbicide is toxic to Nile tilapia juvenile and causes histopathological changes in different organs such as gills, liver, kidney and brain. Therefore the use of glyphosate herbicide on/near fish farms or in area close to aquatic environment should be discouraged.

## REFERENCES

Aguigwo JN (2002). The toxic effect of cymbush pesticide on growth

- and survival of African catfish, *Clarias gariepinus* (BURCHELL1822). *J. aquat. sci.* 17 (2): 81-84.
- Akhtar MH (1986). The disposition of <sup>14</sup>C agrochemical residues in plant and animal tissues when consumed by animals. In: Green halgh, T. and Roberts, T, R., (eds). *Pesticide Science and biotechnology. Proceedings of the 6<sup>th</sup> international congress of pesticide chemistry* Ottawa, Canada, August 1986, pp.10-15
- Annune PA, Hbele SON, Oladimeji AA (1994). Acute toxicity of cadmium to juveniles of *Clarias gariepinus* (Tuegls) and *Oreochromis niloticus* (Trewavas) *J. Environ. Sci. Health, A29*: 1357-1365.
- ASTM (American Society for Testing of Materials) method 729-90: (1990). Guide for conducting acute toxicity test with fishes, macro invertebrates and amphibians.
- Cox C (1998). Glyphosate (roundup). *J. Pestic Reform*, 18: 3-17.
- Ernest H (2004). *A Textbook of modern toxicology*(3<sup>rd</sup> ed), John Wiley&sons Hoboken, New Jersey.ISBN 0-471-26508-X 557pp.
- FAO (1977). Manual of methods in aquatic environment research part 4. Bases for selecting biological test to evaluate marine pollution. FAO fish. Tech. paper (104): 31pp
- Fryer JD (1977). *Weed control handbook Vol.1* Edited by Make Peace, pp. 384-389
- GESAMP (INO/FAO/UNESCO/WHO/IAEA/UN/UNDP (1991). Joint group of experts on the scientific aspects of marine pollution. Review of potential harmful substance carcinogen. *Report study*. GESAMP, 40: 56pp.
- Keneko JJ (1989). *Clinical Biochemistry of domestic animals* 4<sup>th</sup> ed. Diego, Academic press Inc. California, 132 pp.
- Kelly WR (1979). *Veterinary Clinical Diagnosis* 2<sup>nd</sup> ed. Balliere Tindall, London pp. 266-279.
- Kulakkattolickal AT, Kramer DI (1997). The Role of Air Breathing in the Resistance of Bimodally Respiring Fish to Water. *J. Fish Biol.* 32: 119-127
- Mason CF (1991). *Biology of fresh water pollution*.2<sup>nd</sup> Edition, Longman Scientific and Technical.U.K.351pp.
- Mitchell DG, Chapman PM, Long TL (1987). Acute toxicity of round up and Redeo herbicides to rainbow trout, Chinook and Coho salmon. *Bull. Environ. Contam. Toxicol.* 39:1028-1035.
- Neibor E, Richardson DH (1980). replacement of non-descript term heavy metal by a biological and chemically significant classification of metal ions. *Environmental pollution series.* 3(1): 24-45.
- Neskovic NK, Poleksic V, Elezovic I, Karan V, Budimir M (1996). Biochemical and histopathological effects of glyphosate on Carp. (*Cyprinus carpio* L.). *Bull. Environ. Contam. Toxicol.*, 56: 295-302.
- Nowak B (1992). histological changes in gills induced by residues of endosulfan. *Aquat Toxicol* 23.63-84
- Odiette WO (1999): *Environmental physiology of Animal and pollution.* 1<sup>st</sup> Ed. Diversified Resources Ltd. ISBN 978-028-957-7; Lagos. 360 pp.
- Omitoyin BO, Ajani EK, Fajimi AO (2006). Toxicity Gramoxone (paraquat) to juvenile African catfish, *Clarias gariepinus* (Burchell, 1822). *American Eurasian. J. Agric. Environ. Sci.* 1(1): 26-30.
- Omoniyi I, Agbon A, Sodunk, SA (2002). Effects of lethal and sub-lethal concentrations of tobacco (*Nicotiana tobaccum*), leaf dust extractum on weight and haematological changes in *Clarias ganiepinus* (Buchell 1822). *J. Appl. Environ. Man.*, 6: 37-41.
- Oulmi Y, Negele RD, Braunbeck T (1995). Cytopathology of liner and kidney in raindow trout (*Oncorhynchus mykiss*) after long-term exposure to sublethal concentrations of linuron. *Dis. Aquat. Org.* 21: 35-52.
- Oyelese OA, Faturoti EO (1995). Growth and mentality estimates in *Clarias gariepinus* fed graded levels of processed cassava peels *J. Trop. Forest Res.* 11: 71-81.
- Rahman MZ, Hossain Z, Mullah MFR, Ahmed GU (2002). Effect of Diazinon 60EC on *Anabus testudineus*, *Channa punctatus* and *Barbades gomonotus*. *NAGA. The ICLARM Quarterly*, 25: 8-11.
- Reish DL, Oshida OS (1987). *Manual of Methods in aquatic environment research. Part 10. Short- term static Bioassays.* FAO Fisheries Technical Paper No. 247. Rome 62pp.
- Risbourg SB, Bastide J (1995). Hepatic perturbations induced by a herbicide (atrazine) in juvenile grey mullet *Liza ramada* (Mugilidae Telostei): an ultra structural study. *Aquat. Toxicol.* 31: 217-229.
- Schalm OW, Jain NC, Carrol EJ (1975). *Veterinary haematology*, 3<sup>rd</sup>

Ed., Philadelphia, Leaard Febiger, pp. 15-81.  
Servizi JA, Gordon RW, Martens DW (1989): Acute toxicity of Garlon 4 and round up herbicides to salmon, daphnia and trout. Bull. Environ. Contam. Toxicol. 39: 15-22  
Solbe JF (1995). Fresh water in: Handbook of Ecotoxicology (Edited by Peter Collins) Black Well Science Ltd. Osneymeed OX 20EL. 683pp.

Warren CE (1977). Biology and water pollution. W.B. Sanders and Company Philadelphia, USA, 434pp.  
World Health Organization (WHO) (1994): Glyphosate. Environmental Health Criteria, Publication NO 159, Geneva, Switzerland.