

Full Length Research Paper

Histomorphometric study of gametogenesis sub-tropical breeders and helpers, co-operative breeder jungle babbler

Bozorgi Keyvan and Khukhan O.

Division of Avian Biology, Department of Zoology, Faculty of Science, Islamic Azad University, P.O.Box 79085, Tehran, Iran.

Accepted 25 June, 2014

In majority of birds, the reproductive commotion is restricted to a favorable but short period of time. This results in crowding of several physiological and histological changes during its breeding state. Such changes take place in both sexes for successful breeding. Jungle Babblers are termed social/co-operative breeders because of the fact that the breeding pair is assisted by other individuals of the flock (termed as “helpers”). These helpers forgo their own breeding and show allo-parental behavior and help the parents in taking care of all the reproductive chores except egg formation and laying. To understand the breeding cycle, histological and histomorphometric studies of gonadal tissues were carried out in these birds. The testicular cycle of Jungle Babbler could be roughly divided into seven stages showing different types and numbers of germ cells. As per histomorphometric studies, the seminiferous tubule diameter and germ layer thickness increases in breeders. Interstitium reduces in diameter in breeders but is densely packed with leydig cells resulting in high steriodogenesis. Ovaries also show varying degree of follicular maturation in breeders, non-breeders and helpers. The breeding ovaries had maximum number of large follicles with largest diameter. The granulosa cells of the mature follicles are responsible for the production of progesterone the fact which is also supported by the progesterone titers. The non-breeding ovaries consists of maximum number of small follicles in cortical region whereas helpers show both mature as well as small follicles along with large number of atretic follicles. Helpers show intermediate number of mature follicles which results in subdued production of progesterone. Progesterone is responsible for parental behavior as well as oviduct development. Helpers lack a fully functional and active oviduct due to subdued progesterone levels but the titers are enough to evoke the allo-parental behavior in them. To support the findings, in this paper hormonal titers (viz. testosterone, progesterone (Bharucha and Padate; 2009), cholesterol and ascorbic acid concentration in gonads in different individuals are also represented. Therefore, considering the lack of knowledge of reproductive biology about *TURDOIDES STRIATUS*, the purpose of this paper consists of reporting a study on testicular and ovarian cycle in breeders and helpers. From this study it could be inferred that gonads of jungle babblers show cyclicity of development and regression during breeding and non-breeding states.

Key words: Jungle babbler, testicular cycle, mature follicle, atretic follicle.

INTRODUCTION

Reproduction is a biological phenomenon/ which exhibits a regular recurrence of pattern of activities in a cyclic manner (Lofts and Murton, 1973). Birds have an intense

reproductive rhythm which is synchronized by seasonal changes of the environment and by the external factors, because of seasonality and rhythmicity, the reproductive functions exhibit meticulous regulation of initiation and development of gonadal functions which have to be a balanced interaction between environmental and physiological conditions (Phillips et al., 1985). Birds are

*Corresponding author. E-mail: Proff_van@yahoo.fr

adaptively diversified group of vertebrates and detailed information is available regarding correlation of environmental factors and their reproductive patterns. Voluminous literature exists on the annual breeding cycles of birds and greater attention has been given to the seasonal breeding cycles of the temperate seasonal breeders with more emphasis on the migratory birds. However, information regarding subtropical co-operative species is inadequate. Cooperative" or "communal" breeding occurs when more than two birds of the same species provide care in rearing the young from one nest. About 3% (approximately 300 species) of bird species worldwide are cooperative breeders. There are two types of cooperative arrangements: those in which mature non breeders ("helpers-at-the-nest" or "auxiliaries") help protect and rear the young, but are not parents of any of them, and those where there is some degree of shared parentage of offspring. Cooperative breeders may exhibit shared maternity, shared paternity, or both. Females generally disperse and pair after one or two years of helping. Helpers participate in all nonsexual activities except nest construction, egg laying, and incubation. Pairs with helpers are more successful; they fledge one and a half times more than pairs without helpers. In the most common form of cooperative breeding, such as occurs in the Jungle Babbler, most helpers are non breeding individuals that have remained on their natal territory. Jungle Babbler (*Turdoides striatus*) occur in groups that consist of a single breeding female, a dominant male breeder, and up to 4 subordinate, non breeding helpers, most of which are females. Helpers participate in territory defense, construction, and maintenance of nest cavities, incubation, brooding, feeding nestlings, and tending fledglings. Helpers have been shown to significantly improve the reproductive success of the breeding pair.

However, the helpers may be incapable of reproducing because they are sexually immature (delayed maturation) (Reyer et al., 1986) or helpers may be physiologically incapable of reproducing because of poor body condition and /or high levels of stress (physiological suppression) (Wingfield et al., 1991).

Gonadal architecture of seasonally breeding birds, poultry birds and migratory birds is well known, but the information regarding the anatomy of gonads of co-operative birds is less known and unfamiliar. One intriguing question about the co-operative breeders is that whether there is any disparity in the structure of gonads in helpers as compared to breeders and non-breeders and if so the possible physiological cause behind that dissimilarity.

Thus, the study pertaining to the histology and histomorphometry of gonads of Jungle Babbler was undertaken as it is an endemic bird to the Indian sub-continent. Jungle Babbler is also an integral part of the agro-ecosystem where the standing crops can be benefited by their insectivorous activity. Thus, understanding

their reproductive cycle through the histological, histometric and physiological changes was taken up.

The breeding season of Jungle Babblers (*T. striatus*); seem to differ slightly in different parts of India (Ali, 1993; Whistler, 1949; Andrews, 1968). Jungle Babbler is a very common feral bird around, which has kept up its originality of reproductive rhythms without undergoing a modifying influence of urbanization. It is a social co-operative bird which lives in a flock of 7-8 birds and during breeding season it breaks up into a group of 3-4 birds. In this group of 3-4 birds, apart from the breeding pair, other individual members termed "helpers" forgo their breeding in order to assist the breeding pair. Hence, the aim of the present study was to inspect the histological and histomorphometric changes occurring in the gonads of breeders and especially in helpers in Jungle Babbler, a bird from semi arid subtropical region of India. This paper also presents the results of the investigations carried out to establish the correlation between changes in gonadal cholesterol and ascorbic acid concentration in different individuals along with the hormonal titers, with the histological, histomorphometric studies of the gonads (Bharucha and Padate, 2003).

The relationship of cholesterol concentration in the gonadal tissue to maturation and steroidogenesis as well as gametogenesis is been studied in birds (Marsa and Aoki, 1976; Ikegwuonu and Aire, 1977; Chand et al., 1978; Kanwar et al., 1977), while the reproductive effects of ascorbic acid have been researched extensively in mammals. The antioxidant property of ascorbic acid is essential to maintain membrane and genetic integrity of sperm cells by preventing oxidative damage to sperm DNA. Attempt has also been made to study the gonadal ascorbic acid depletion in phases of increased steroidogenesis activity during maturation in cockerels (Chand et al., 1978), because of their key role in the phenomenon of steroidogenesis (Kitabachi, 1967). The antioxidant property of ascorbic acid may delay formation of degenerative cells, MGC: multinucleated giant cells (Neuman et al., 2002). Reports were estimates of gonadal cholesterol or ascorbic acid concentrations in relation to gonadal maturation in this species were not found in literature.

Spermatogenesis is a complex process involving mitotic cell division, meiosis and the process of spermiogenesis. The regulation of spermatogenesis involves both endocrine and paracrine mechanism. The endocrine stimulation of spermatogenesis involves both FSH and LH, the later acting through the intermediary testosterone produced by the leydig cells of testes (de Kretser et al., 1998). Porter et al. (1989) proposed a "3-cell theory" for avian ovarian steroidogenesis which explained the different steroid production of the follicular tissues (granulosa: progesterone, theca interna: androgen, theca externa: estrogen). There is an increased progesterone concentration in granulosa and decrease in estrogen production of theca during follicular maturation. Ovarian

hormones affect the reproductive state, the secondary sexual characters, metabolism and behaviour in birds (Sturkie, 1965). Silver et al. (1974) observed a significant correlation between follicle development and progesterone. The dominating synthesis of androgen was localized in the theca interna of immature follicles (Hackl et al., 2003). Therefore, in the present study the entire the aspect of the breeding biology of *T. striatus* is evaluated.

MATERIALS AND METHODS

The study was carried out according to the guidelines of the Committee for the Purpose of Control and Supervision of Experiments on Animals, India and approved by the Animal Ethical Committee of Department of Zoology, The M.S University of Baroda, Vadodara, India. The study carried out has been funded by ICAR (Indian Council of Agricultural Research) due to the importance of the bird in IPM (Integrated Pest management) approach. The objective of the project was to assess the relationship of carbohydrate, protein and lipid metabolism along with the histology, histochemistry and reproductive/breeding physiology including hormonal interaction during different seasons. So sufficient amount of tissue (especially in non-breeders where gonad size is too small) was required to carry out all the above said parameters, that is why the number of birds used was 8, even though for statistical analysis 6 are sufficient.

The birds were procured locally by means of a professional net to seize the flock. Thus the birds of the same flock were used for the above said studies. The number of birds used for the study for breeding and non-breeding males was 8, respectively. In case of females, the number of individuals for breeders, non-breeders and helpers was 8, respectively. They were kept in an open aviary with food and water *ad libitum*. After laparotomy, and the uncovering of the sternal breast plate and evisceration of the alimentary tract, the gonads were removed and blotted free of the tissue fluid. Sections were made, immersed in Bouin's fluid and later dehydrated in 70% alcohol, according to the technique of histological routine. The testis/ovary was embedded in paraffin and histological sections (5 μ thickness) were obtained to be later stained using Hematoxylin-Eosin technique. 20 cross-sections of testis/ovary were chosen at random to obtain the morphometric measures.

The following measurements were done with the aid of ocular-micrometer.

For male birds

1. Diameter of at least 20 seminiferous tubules (in T.S.) of both breeding and non-breeding males.
2. Thickness of the germ layers of at least 20 seminiferous tubules (in T.S.) of both breeding and non-breeding males.
3. Diameter of interstitium of at least 20 seminiferous tubules (in T.S.) of both breeding and non-breeding males.

For female birds

1. The increase and/or decrease in the number of different types of follicular cells (*viz.* small, medium, large and atretic follicles).
2. Diameter of the largest follicle.

For hormonal studies

Blood was collected in the heparinised test tubes from the

ventricles of the anesthetized birds and later centrifuged for 60 min at 3000 rpm. After centrifugation plasma was collected in Eppendorf tubes and stored at -4°C . The separated plasma fraction was used for quantitative measurements of progesterone and testosterone (by EIAgen kit, Biochem; Italia) respectively in both male and female Jungle Babblers.

EIAgen testosterone/progesterone kit

To evaluate testosterone/ progesterone content in blood plasma, a micro plate solid phase enzyme immunoassay kit was used. The EIAgen testosterone/ progesterone kit contains: a testosterone/ progesterone micro plate, testosterone/progesterone calibrators, testosterone/progesterone conjugates, washing solution, TMB H_2O_2 HS, stop solution (H_2SO_4). The solid phase enzyme immunoassay for testosterone/progesterone is a competitive type immunoassay wherein HRP labelled testosterone/progesterone competes with the testosterone/progesterone present in the sample (10 μl) for a fixed and limited number of antibody sites immobilised on the wells of the microstrips.

Once the competitive immunoassay reaction has occurred, the wells are washed and the HRP- testosterone/ progesterone fraction bound to the antibody in the solid phase is measured by adding the chromogen/substrate solution which is converted to a blue compound. After 15 min of incubation, the enzyme reaction is stopped with H_2SO_4 , which also changes the solution to a yellow colour. The absorbance of the solution is measured photometrically at 450 nm and is inversely related to the concentration of the testosterone/progesterone present in the sample (10 μl). Calculations of the testosterone/ progesterone content in the sample are made by reference to a calibration curve.

Calculations of results for testosterone/ progesterone

To calculate the mean absorbance of calibrators and samples (A), the absorbance of the chromogen blank (A_c) is subtracted from the absorbance of all the samples. This is considered as the corrected value. Corrected values of the sample are divided by the corrected absorbance of the zero calibrator (A_o) and multiplied by 100 ($A - A_c / A_o - A_c \times 100$). The respective testosterone/progesterone values are plotted on the logit log or semi log graph paper and the concentration of testosterone/progesterone in the samples are determined by the interpolation from the calibration curves.

Total cholesterol

The total cholesterol estimation was carried out by the method described by Crawford (1958) and is expressed as mg cholesterol/ 100 mg of tissue. Cholesterol was extracted in 3: 1 chloroform-methanol mixture. 2 ml of the extract was taken and dried completely in air oven. After drying of the tubes, 3 ml of FeCl_3 was added and boiled for 5 min. After cooling, 2 ml of conc. H_2SO_4 was added and mixed thoroughly. The brown color developed was measured colorimetrically after 30 min at 540 nm.

Ascorbic acid

Ascorbic acid estimation was carried out by the method described by Roe (1954) and is expressed as mg ascorbic acid/100 mg tissue. Tissue was homogenized in prechilled mortar-pestle with 6% TCA. Norit was added which acts both as oxidizing and clarifying agents. The solution was allowed to stand for 15 min and filtered. 2 ml aliquote was taken in a test tube, 2 drops of thiourea and 0.5 ml of 2, 4 DNP were then added and left for incubation in boiling

Table 1. The histological changes observed in male Jungle babbler.

	Body weight (gms)	Testes weight (mgs)	GSI	Avg. diameter of seminiferous tubule (μ)	Avg. thickness of germinal layer (μ)	Avg. diameter of interstitium (μ)
Breeding	61.4 ± 2.27	205.0 ± 14	0.326 ± 0.032	55.25 ± 0.11	16.25 ± 0.09	4.72 ± 0.03
Non-breeding	56.7 ± 2.24	13 ± 1	0.025 ± 0.004	24.37 ± 0.1	8.12 ± 0.088	10.72 ± 0.036

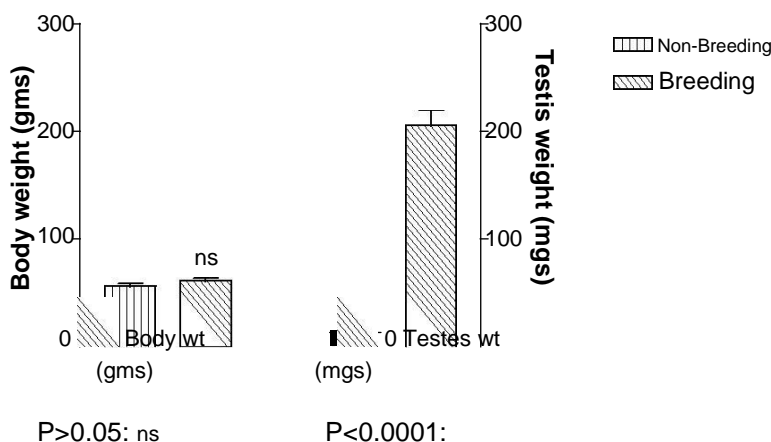


Figure 1. Body and testis weight in breeding and non-breeding male jungle babbler (*Turdoides striatus*).

water bath for 15 min. At the end of incubation, tubes were transferred to ice bath and 2.5 ml of 85% H₂SO₄ was added and allowed to stand for 30 min. The color developed was read at 540 nm.

Statistics

Statistical evaluation for males was done by T-test (non-parametric test), while the data for the females was done by one way ANOVA (non-parametric) followed by the Bonferroni multiple comparison post test and results are expressed as mean ± S. E (P<0.0001: ***, P<0.001: **, ♦♦, P<0.01: *, P>0.05: non-significant), using Graph Pad Prism version 3.0 for Windows, Graph Pad Software, San Diego California, USA.

The student's t-test was done to analyse the male data, because t-test assesses only two groups (in this case breeder and non-breeder males) and help identify whether the means of two groups are statistically different from each other. This analysis is appropriate when comparing the means of two groups, and especially appropriate as the analysis for the post test-unpaired, non-parametric and would yield identical results. While one way ANOVA was done to analyse the female data because it enables the difference between more than two samples means (in this case breeders, non-breeders and helper females), achieved by subdividing the total sum of squares. It enables all classes to be compared with each other simultaneously rather than individually; it assumes that the samples are normally distributed.

RESULTS

The histomorphometric measures which includes the

average thickness of diameter of the seminiferous tubule, average thickness of the germinative layer and the average diameter of the interstitium along with the body weight, testes weight and GSI (Gono somatic index) for breeding and non-breeding males are given in Table 1, Figures 1 and 2 whereas body weight, weight of the ovary, weight of oviduct with GSI and different follicular sizes are given in Table 2, Figures 3 and 4. The histological features of testes are given in Plate I and of ovary in Plate II. Variations in hormones and certain metabolites involved in steriodogenesis in breeding, non-breeding and helper birds are represented in Table 3.

TESTES

The right testis of Jungle Babbler was always found to be superior in size and higher in weight than the left one. These differences were more pronounced during the breeding season. A regular well defined spermatogenic cycle as reported by (Andrews, 1968) was also found in the present study. The spermatogenic cycle of the Jungle Babbler is divided into the following stages:

Stage I. Resting spermatogonia only

spermatocytes.

Stage III. Many spermatocytes.

Stage IV. Spermatids and spermatozoa.

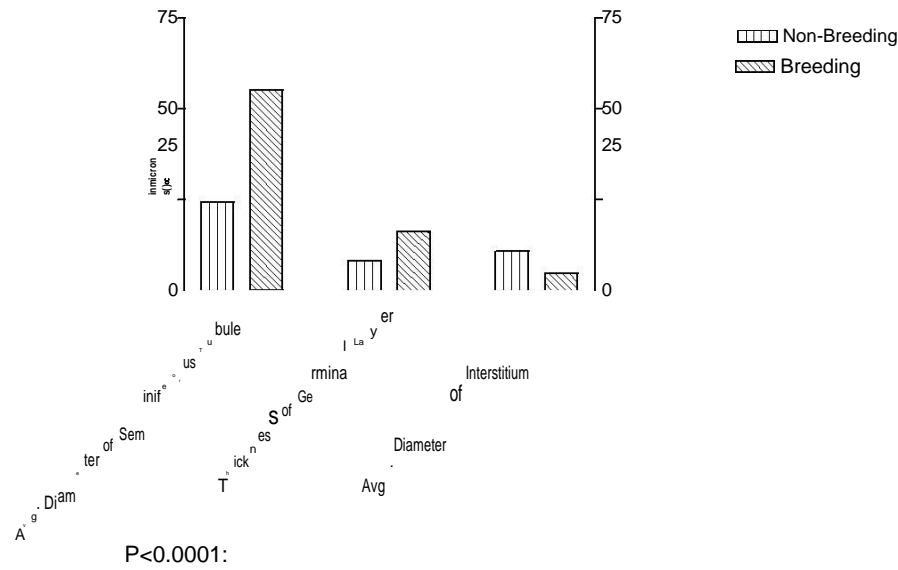


Figure 2. Average diameter and thickness of seminiferous tubules, interstitium and germinal layer of breeding and non-breeding male jungle babblers (*Turdoidea striatus*).

Table 2. Variation in gono-somatic ratio and percentile of the follicles in female Jungle babblers.

	Body weight (gms)	Ovary weight (mgs)	Oviducal weight (mgs)	GSI	Small follicles (%)	Medium follicles (%)	Large follicles (%)	Atretic follicles (%)	Mean diameter of largest follicle (mm)
Breeding	58.66 ± 4.5	72.66 ± 9.39	181.66 ± 30.17	0.129 ± .024	4	12	10	5	8.90
Non-breeding	54.0 ± 2.47	9.0 ± 1.27	8.71 ± 2.87	0.028± 0.011	17	5	2	6	1.98
Helper	58.14 ± 1.86	65.71 ± 6.03	47.57 ± 8.30	0.113± 0.010	8	10	4	8	5.60

Stage V. Many spermatozoa.

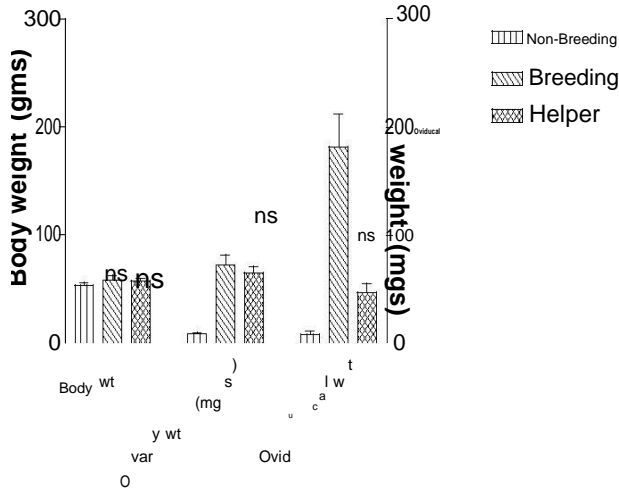
Stage VI. Full spermatogenic activity with many spermatozoa still attached to the tubular wall.

Stage VII. Regressing testis.

Most of the breeding testes with spermatids and spermatozoa (Plates I, 4) were found from May to

November indicating that Jungle Babbler are in readiness to breed for long period from May to November. However, non-breeding testes with resting spermatozoa were also found all throughout the year (Plate I, 1). In breeding testes the diameter of the seminiferous tubule was 55.25 ± 0.11 µm and in non-breeding testis it was 24.37 ±

0.1 µm (F = 1.210, P value = 0.3410, t = 207.7). When spermatids and spermatozoa were present (Plate I, 4) the seminiferous tubule diameter was larger than stage in which spermatozoa were still attached to germ layer (Plate I, 6). Maximum diameter was observed in seminiferous tubule with primary and secondary spermatocytes.



: Non-breeding vs. breeding P<0.001:
 : Non-breeding vs.helper P<0.001:
 : Breeder vs. helper P<0.001:

Figure 3. Body, ovary and oviductal weights in non-breeding, breeding and helper female jungle babblers (*Turdoides striatus*).

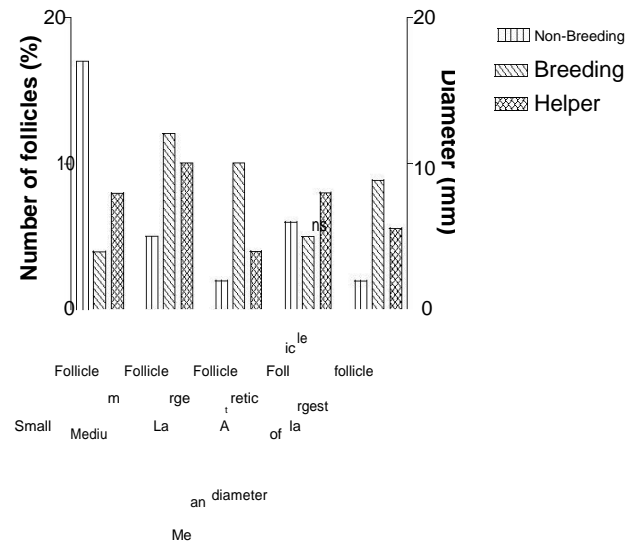
The average thickness of germinal cell layer in breeding and non-breeding testes were 16.25 ± 0.09 and $8.12 \pm 0.088 \mu\text{m}$ ($F = 1.046$, P value = 0.4615 , $t = 64.59$), respectively. The average interstitium diameter in breeding and non-breeding males was 4.72 ± 0.03 and $10.72 \pm 0.031 \mu\text{m}$ ($F = 1.440$, P value = 0.2170 , $t = 128$), respectively (Table 1). In the regressing testes the rows of spermatogonia and occasionally a few spermatocytes were seen.

The Jungle Babbler combines characteristic of the interstitium found variably in mammals (Aire, 1997) with centrally located blood vessels and Leydig cells (Plate I, 3). The basal lamina resting on a closely associated homogenous microfibrillar layer can be seen in (Plate I; 2, 3, 4 and 6). The basal lamina in resting testes was not distinct. In Jungle Babbler, the Leydig cells were distinct in all stages except the stage when spermatozoa are present still attached to the germ layer (Plate I; 6).

The average body weight, testis weight, GSI and hormonal titers along with the metabolites involved in steroidogenesis in breeding and non breeding males are given in Tables 1, 3 and Figure 1.

OVARY

The ovaries were covered by single columnar epithelium, containing many follicles in the cortical zone. The type and degree of development varied between the stages. The inner medullar stroma was composed of well vascularised and innervated connective tissue, with spaces (lacunae) whose covering epithelium changed in each period. The various follicular stages observed in the



: Non-breeding vs. breeding P<0.0001 :
 : Non-breeding vs.helper P<0.001 :
 : Breeder vs. helper P<0.01 : /

Figure 4. Percentile of various follicles and mean diameter of largest follicle in non-breeding, breeding and helper females of jungle babblers (*Turdoides striatus*).

ovary of Jungle Babbler in present study were categorized as small follicles, medium follicle, large follicles and atretic follicles. These stages were noted for all the three females' viz. breeding and non-breeding females along with the helper females. The percentile of these follicular stages in the above mentioned females are given in Table 2. The percentiles of small follicles present in breeding, non-breeding and helper females were 4, 17 and 8 { $F = 860.3$, P value = 0.9589 , t (B vs. Nb) = 40.49 , t (B vs. H) = 12.46 , t (H vs. Nb) = 28.03 }, respectively, whereas the percentage of medium sized follicles were 12, 5 and 10 { $F = 407.7$, P value = 0.9773 , t (B vs. Nb) = 10.16 , t (B vs. H) = 28.26 , t (H vs. Nb) = 17.66 }, respectively. The large sized follicles were seen maximum in breeding females at 10% followed by helper females at 4% and least were observed in the non-breeding females at 2% { $F = 346.9$, P value = 0.9755 , t (B vs. Nb) = 25.31 , t (B vs. H) = 18.98 , t (H vs. Nb) = 6.327 }. The atretic follicles were observed maximum in helper females at 8% followed by non-breeding and breeding females at 6 and 5% { $F = 44.87$, P value = 0.8481 , t (B vs. Nb) = 3.10 , t (B vs. H) = 9.30 , t (H vs. Nb) = 6.20 }, respectively. The mean diameter of the largest follicle present in the breeding females was 8.90 mm while that in helper females was 5.60 mm and least follicular diameter was observed in non-breeding females at 1.98 mm { $F = 58.64$, P value = 0.9600 , t (B vs. Nb) = 10.83 , t (B vs. H) = 5.17 , t (H vs. Nb) = 5.64 }. The active ovary consisting of number of large follicles which are passing through the final stages of yolk accumulation are shown in Plate II; 2. The follicle consists of number of layers, the theca externa, the

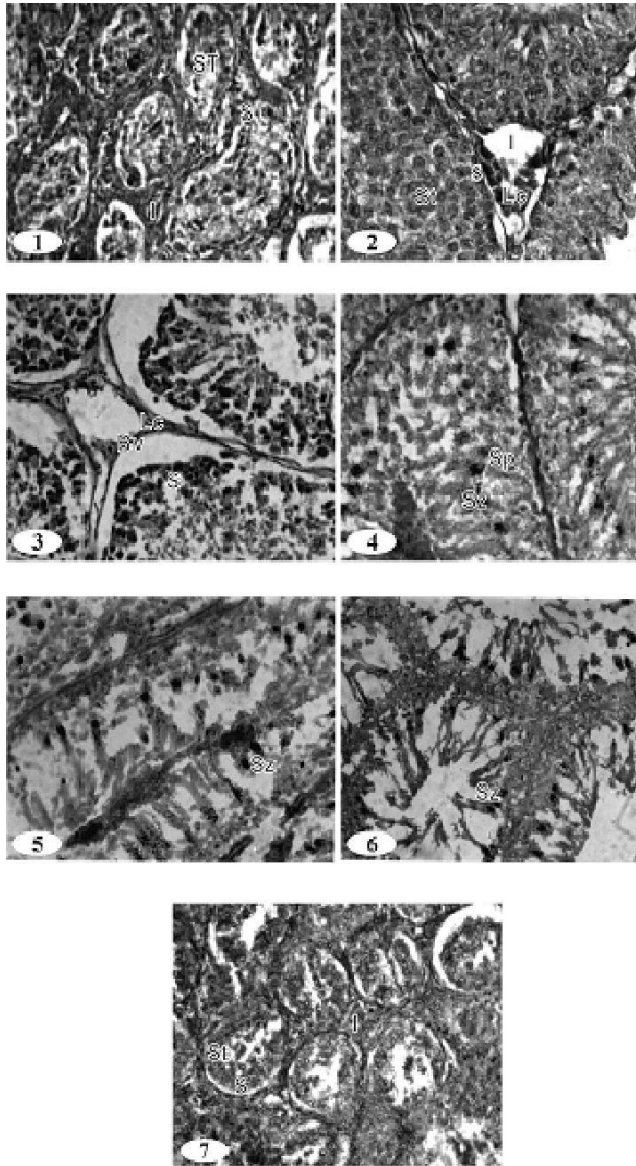


Plate I. Spermatogenic cycle in male jungle babbler (*Turdoidea striatus*). Stage 1. Resting spermatogonia (800 X). Stage 2. Dividing spermatogonia with a few spermatocytes (800 X). Stage 3. Many spermatocytes (800 X). Stage 4. Spermatids and spermatozoa (800 X). Stage 5. Many spermatozoa (800 X). Stage 6. Full spermatogenic activity with many spermatozoa still attached to the tubular wall (500 X). Stage 7. Regressing testis (800 X). S, spermatogonia; St, spermatocytes; Lc, Leydig cells; BV, Blood vessel; Sp, Spermatids; Sz, spermatozoa; L, Lumen; ST, Seminiferous tubule; I, Interstitium.

theca interna, the basement membrane, the membrana granulosa and the perivitelline membrane as shown in Plate II, 2.

The theca externa is known to comprise the greater part of the thickness of the follicular wall and contains muscle fibers. In birds the theca interna is a much thinner layer (Plate II, 2) which consists of collagen fibers. Basement membrane is a layer of cells separating the

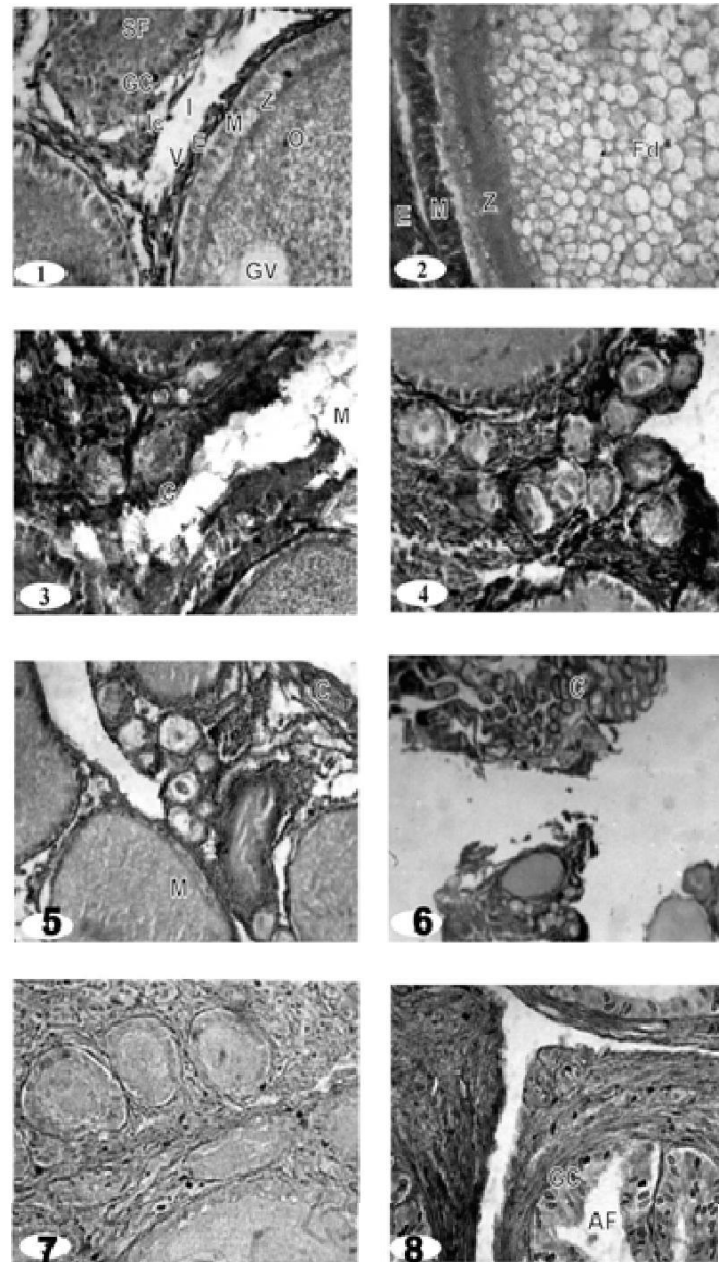


Plate II. Ovary of breeding, non-breeding and helper female jungle babblers. Figure 1. Ovarian follicles of large and medium size (800 X). Figure 2. Enlarged (large) follicle, within ova fat droplets (Fd) (800 X). Figures 3 and 4. Cortex with many small sized follicle (800 X). Figure 5. Many small and medium sized follicles (500 X). Figure 6. Cortical region with many small follicles (200 X). Figure 7. Non-breeding ovary with large number of small follicles (800X). Figure 8. Atretic follicle (AF) with cellular mass invading follicular cavity (C) (800 X). SF, Secondary follicle; O, Oocyte; GC, Granulosa cells; GV, Germinal vesicle; Lc, Interstitial cells; Z, Zona radiate; M, Membrana granulosa; V, Theca externa; M, Medulla; C, Cortex; AF, Atretic follicle; GC, Granulosa cells.

theca interna from the membrana granulosa. The follicular epithelium (membrana granulosa) is a layer immediately adjacent to the ovum (Plate II, 2). Zona

Table 3. Variations in hormones and certain metabolites involved in steroidogenesis in breeding, non-breeding and helper birds.

Parameters	Male (Testes)		Female (Ovary)		
	Non-breeding	Breeding	Non-breeding	Breeding	Helpers
Testosterone	0.21 ± 0.040	0.76 ± 0.027***	0.18 ± 0.049	0.65 ± 0.050***	0.63 ± 0.033**/ns
Progesterone	0.15 ± 0.054	0.3 ± 0.025*	0.16 ± 0.042	1.13 ± 0.066**	0.7 ± 0.00**/◆◆
Cholesterol	0.041 ± 0.001	0.029 ± 0.001***	0.04 ± 0.001	0.012 ± 0.003**	0.011 ± 0.004**/ns
Ascorbic acid	3.46 ± 0.53	2.93 ± 0.67 ns	2.55 ± 0.63 ns	1.85 ± 0.41 ns	2.4 ± 0.25 ns

(P < 0.0001: *** P < 0.001: ** P < 0.01: * P > 0.05: non-significant).

radiata is the most peripheral region of the oocyte. Atretic follicles are known to occur normally and regularly in active ovaries. When follicles reach the maximum size, the granulosa cells begin to proliferate forming numerous irregular layers around the ovum. The ovum size decreases and eventually granulosa cells fill the entire follicle (Plate II, 8). This undergoes hypertrophy and becomes a connective tissue scar. Immediately after ovulation the follicle shrinks and due to this the walls become thickened and granulosa increases to several cells in thickness. The follicle regresses rapidly and is eventually reabsorbed into the mass of the ovary.

The average body weight {male = (F = 1.027, P value = 0.4887, t= 1.477), Female = (F = 0.6562, P value = 0.1484)}, ovary weight (F = 29, P value = 0.0022), oviducal weight (F = 25.02, P value = 0.0001), GSI and hormonal titers {Male (testosterone)= (F = 2.195, P value = 0.2043, t= 11.40), Male (progesterone) = (F = 4.666, P value = 0.0581, t= 2.251), Female (testosterone) = (F = 36.53, P value = 0.5122), female (progesterone) = (F = 115.8, P value = 0.001)} along with the metabolites involved in steroidogenesis in the breeding, non breeding and helpers are represented in Tables 2 and 3 and Figures 3 and 4.

DISCUSSION

In birds, there is a pronounced increase in the size of testes during breeding. Histologically this increase in size occurs primarily as a consequence of the enlargement of the seminiferous tubules in which sperms are produced (Lofts and Murton, 1973). Spermatogenesis is reported to be fairly conserved process throughout the vertebrate series. Spermatogenesis occurs in the seminiferous tubules, that possess a permanent population of sertoli cells and spermatogonia which act as a germ cell reservoir for succeeding bouts of spermatogenic activity (Pudney, 1995). Some testicular histological parameters have been explored in the bird's testis for characterization of testicular cycle such as seminiferous tubule diameter, the thickness of seminiferous epithelium, thickness of tunica albuginea, number of interstitial cells, the number of germinative cells (Fuenzalida et al., 1989; Baraldi-Artori et al., 1997). The present study establishes

the correlation between histological and histomorphometric changes occurring in the testis in breeding and non-breeding males.

The interstitial tissue of breeding testes is known to be tightly packed with the Leydig cells which contain relatively large amounts of lipid droplets related to androgen synthesis; while that in the non-breeding testes, the interstitial tissue contains only occasional Leydig cells with an enlarged intercellular space (Rosenstrauch et al., 1998). In Jungle babbler, the average interstitium diameter in breeders is less and tightly packed with interstitial cells while in non-breeders the diameter of interstitium is more with less number of leydig cells. Breucker (1982) has worked with testis of sexually mature swans *Cygnus olor* and considered that an adequate parameter to evaluate the variation of spermatogenic activity is the variation of the seminiferous tubular diameter. The seminiferous tubular diameter of the swan shows a progressive increase in winter and maximum values in spring (proliferation period) with a decrease in summer and fall (periods of sexual regression and rest). In Jungle babblers, we found smaller relative values as to the diameter of the seminiferous tubules and thickness of the germinative epithelium in non-breeders while the tubular diameters, thickness of the germinative epithelium was maximum in breeders. The variation in the mean body weight does not show any marked variation in relation to the breeding activities. These observations are also supported by the evaluation of testosterone, cholesterol and ascorbic acid in the testis of both breeders and non-breeders. Jungle babblers are social/co-operative breeders and they rely on daily food supply rather than accumulation of fat prior to breeding as seen in many seasonally breeding birds. Hence, no significant variation was observed in the body weights amongst the breeders and non-breeders males.

The avian ovary consists essentially of an outer cortex containing ova which surrounds a highly vascular medulla composed primarily of connective tissue. The surface of the cortex is covered by the cuboidal germinal epithelium. There is vast number of ova developing in the ovary but only few reach maturity and only a comparative few are ovulated. The surface of the ovary is covered by the germinal epithelium consisting of a single layer of cells. All the ova within the ovary are primary oocytes until

before ovulation. Within the cortex there are numerous minute developing ova. Also, in Jungle babbler similar stages were found. A histochemical study has been made of seasonal fluctuations in the follicular atresia and interstitial gland tissue with the ovarian cycles of the house sparrow (Guraya and Chalana, 1976) in crow and myna (Chalana and Guraya, 1979) in grey quail (Saxena and Saxena, 1980) in house swift (Naik and Naik, 1965). The atresia of the primordial oocyte forms the predominant feature of the quiescent-winter ovary. The building up of interstitial gland tissue of the thecal origin, which precedes the breeding activity, is closely related to the atresia of previtellogenic follicles of variable sizes (Chalana and Guraya, 1979). In Jungle babblers the ovaries were covered by single columnar epithelium, containing many follicles in the cortical zone. The type and degree of development varied between breeders, non-breeders and helpers. The inner medullar stroma was composed of well vascularised and innervated connective tissue, with spaces (lacunae). In breeding females maximum number of medium sized follicles with biggest diameter was observed, while in non-breeding females more number of small follicles with least diameter was observed. Helper females showed nearly same number of small and medium sized follicles but maximum number of atretic follicles. In Florida Scrub Jay helpers ovarian follicles were not as developed as breeders, they were not completely regressed (Schoech, 1996). The same thing was observed for helper females in Jungle Babblers too. This data is also supported by the levels of progesterone in these females. In helpers, as intermediate numbers of mature follicles are present, the granulosa cells of which are capable of progesterone synthesis also reflected in the progesterone titers in helpers. Due to the subdue levels of progesterone, functional and active oviduct development in helpers was not seen but the progesterone titers are enough to evoke the allo-parental behavior in them. Same as in case of males, no significant variations was seen in body weights of breeders, non-breeders and helpers. The amount of cholesterol and co-enzyme ascorbic acid also supports the histological and morphometric analysis of the ovaries in these females.

Therefore, the present data concerning seminiferous tubules diameter, thickness of the germinative epithelium and diameter of the interstitium revealed a variation in breeders and non-breeders. The highest seminiferous tubules diameter, thickness of germinative epithelium was detected in breeders demonstrating that the greater spermatozoa production occurs in them. The histological and histomorphometric studies carried out in testis show cyclicity in spermatogenesis wherein it could be roughly divided into 7 stages depending on the type of germ cell present. Histomorphometric variations were also noted for the interstitium diameter which decreases during the breeding state. Observation of breeding ovaries, showed cells at various stages of follicular maturation. It had

maximum number of large follicles with maximum diameter. The non-breeding ovaries had maximum number of small follicles while the helper females showed both small and large follicles. Maximum atretic follicles were observed in helpers.

REFERENCES

- Aire TA (1997). The structure of the interstitial tissue of the active and resting avian testes. *Onderstepoort, J. Vet. Res.*, 64(4): 291-299.
- Ali S (1993). *Book of Indian Birds*. Bombay Natural history Society, 53: 421.
- Andrews MI (1968). Ecology of the social system of Jungle babbler, *Turdoides striatus* (Dumont). Thesis submitted to the M.S. University of Baroda.
- Baraldi-Artoni SM, Orsi AM, Lamano-Carvalho TL, Lopes RA (1997). The annual testicular cycle of the domestic quail (*Coturnix coturnix japonica*). *Anat. Histol. Embryol.*, 26: 337-339.
- Bharucha B, Padate GS (2002). Ascorbic acid-cholesterol correlation in socially breeding species of bird, Jungle babbler (*Turdoides striatus*). *Pavo*. 40-41(1-2): 127-132.
- Breucker H (1982). Seasonal spermatogenesis in the mute swan (*Cygnus olor*). *Anat. Embryol. Cell Biol.*, 72: 1-91.
- Chalana RC, Guraya SS (1979). Seasonal fluctuations and histochemical characteristics of the interstitial cells in the ovary of Crow and Myna. *Pavo.*, 17(1-2): 65-70.
- Chand D, Arneja DV, Arora KL (1978). Relation of testicular ascorbic acid concentration to testicular development in Desi and White Leghorn poultry. *Indian J. Exptl. Biol.*, 16: 676-678.
- Crawford N (1958). An improved method for the determination of free and total cholesterol using ferric chloride reaction. *Clin. Chim. Acta.*, 3: 357-367.
- De Kretser DM, Loveland KL, Meinhardt A, Simorangkir D, Wreford N (1998). Spermogenesis. *Hum. Reprod.*, 13(1): 1-18.
- Fuenzalida H, Leyton V, Valencia J, Blanquez MJ, Gonzalez ME (1989). Morfologia del testiculo de *Pygoscelis papua* (FOSTER) durante el periodo de actividad sexual. *Arch. Anat. Embryol.*, 20: 79-81.
- Guraya SS, Chalana RK (1976). Histochemical observations on the seasonal fluctuations in the follicular atresia and interstitial gland tissue in House Sparrow ovary. *Poult. Sci.*, 55(5): 1881-1885.
- Hackl R, Bromundt V, Daisley J, Kotschal K, Hostl E (2003). Distribution and origin of steroid hormones in the yolk of Japanese quail eggs (*Coturnix coturnix japonica*). *J. comp. physiol. B.*, 173: 327-331.
- Ikegwuonu FI, Aire TA (1977). Age influenced variations in levels of cholesterol and ATPase activity in the testes of prepubertal chicks. *Poult. Sci.*, 56: 1158-1160.
- Kanwar U, Sheikher C, Mehta HS (1977). Seasonal changes in the lipids of the crow *Corvus splendens*: Cytochemical and biochemical studies. *Indian J. Exptl. Biol.*, 15: 1040-1042.
- Kitabachi AE (1967). Ascorbic acid in steroidogenesis. *Nature, Lond.*, 215: 1385-1386.
- Lofts B, Murton RK (1973). Reproduction in birds. In: *Avian Biology*. Ed. Farner DS and King JR Academic press Inc, NY., 3: 5-40.
- Marsa EM, Aoki A (1976). Differentiation of cholesterol compartments in the immature chick testis. *J. Reprod. Fert.*, 47: 313-318.
- Naik RM, Naik S (1965). Studies on the House Swift (*G. E. Gray*) 4. Gonadal cycle. *Pavo.*, 3(2): 77-88.
- Neuman SL, Orban JI, Lin TL, Latour MA, Hester PY (2002). The effect of dietary ascorbic acid on semen traits and testis histology of male turkey breeders. *Poult. Sci.*, 81(2): 265-268.
- Phillips JG, Butler PJ, Sharp PJ (1985). Environment and Reproduction. In: *Physiological strategies in avian biology*. Ed. Blackie, Chapman and Hall, New York pp. 113-124.
- Porter TE, Hargis BM, Silsby JM, El Halawani ME (1989). Differential steroid production between theca interna and theca externa cells: a three-cell model for follicular steroidogenesis in avian species. *Endocrinol.*, 125: 109-116.
- Pudney J (1995). Spermatogenesis in non-mammalian vertebrates.

Microse. Res. Tech., 32(6): 459-497.

Reyer HU, Dittami JP, Hall MR (1986). Avian helpers at nest: are they physiologically castrated? Ethol., 71: 216-228.

Roe JH (1954). Chemical determination of ascorbic acid. In: methods of biochemical analysis. Vol 1. Glick D. (ed.), New York, Interscience publishers.

Rosenstrauch A, Weil S, Degen AA, Friedlander M (1998). Leydig cell function, structure and plasma androgen level during the decline in fertility in aging roosters. Gen. Comp. Endocrinol., 109(2): 251-258.

Saxena A, Saxena AK (1980). Gonadal cycle and secondary sexual characters of the Grey Quail (*Coturnix coturnix*). Pavo., 18(172): 62-77.

Schoech SJ (1996). Endocrine Mechanisms of Cooperative Breeding in Florida Scrub Jays (*Aphelocoma coerulescens*). Abstracts from International Symposium on Avian Endocrinology. Chateau Lake Louise, Alberta. p. 4.

Whistler H (1949). Popular hand book of Indian birds. Gurney and Jackson, London.

Wingfield JC, Hegner RE, Lewis DM (1991). Circulating levels of luteinizing hormone and steroid hormones in relation to social status in the cooperatively breeding white-browed sparrow weaver, *Plocepasser mahali*. J. Zool., 225: 43-58.