

Full Length Research Paper

Anti-ulcerogenic activity of *Gynura procumbens* leaf extract against experimentally-induced gastric lesions in rats

A. A. Mahmood^{1*}, Abdalbasit A. Mariod², Fouad Al-Bayat³ and Siddig Ibrahim Abdel-Wahab⁴¹Department of Molecular Medicine, Faculty of Medicine, University of Malaya, 50603, Kuala Lumpur, Malaysia.²Department of Food Science and Technology, College of Agricultural Studies, Sudan University of Science and Technology, P.O. Box 71, Khartoum North, Sudan.³Department of Restorative Dentistry, Faculty of Dentistry, University Technology Mara, 40000, Shah Alam, Selangor, Malaysia.

Accepted 25 November, 2021

Several plants are used in folk medicine to treat gastrointestinal disorders. *Gynura procumbens* is a medicinal plant commonly used in traditional treatment of many ailments. In this study, *G. procumbens* ethanolic leaf extract (GPELE) was used to investigate its gastroprotective effect in adult *Sprague dawley* rats which were divided into six groups. The rats were orally pre-treated with carboxymethyl cellulose (CMC) solution (ulcer control groups), omeprazole 20 mg/kg (reference group), 50, 100, 200 and 400 mg/kg of GPELE in CMC solution (experimental groups), one hour before oral administration of absolute ethanol to generate gastric mucosal injury. After an additional hour, the rats were sacrificed and the ulcer areas of the gastric walls were determined. The ulcer control group exhibited severe mucosal injury, whereas groups pre-treated with GPELE exhibited significant protection of gastric mucosal injury. These findings were also confirmed by histological studies. Acute toxicity study with a higher dose of 5 g/kg did not manifest any toxicological signs in rats. These results suggest that GPELE promotes ulcer protection as ascertained grossly by significant reduction of ulcer area, and histologically by comparatively decreases in ulcer areas, reduction or absence of edema and leucocytes infiltration of submucosal layer compared to ulcer control group.

Key words: *Gynura procumbens*, cytoprotection, gastric ulcer, histology, ethanolic extract.

INTRODUCTION

Gastric ulcer is an illness that affects a considerable number of people worldwide. The etiological factors of this disorder include: stress, smoking, nutritional deficiencies, infections, frequent and indiscriminate use of non-steroidal anti-inflammatory drugs (NSAIDs) (Khazaei and Salehi, 2006). The pathogenesis of gastro-duodenal ulcers is influenced by various aggressive and defensive factors, such as mucus secretion, mucosal barrier, acid-pepsin secretion, blood flow, cellular regeneration and endogenous protective agents (Mizui et al., 1987). Although the introduction of proton-pump inhibitors to the classic anti-ulcer therapy had revolutionized treatment

of peptic ulcers and other gastrointestinal disorders, there is still no complete cure for this disease. It has been shown that long term use of these drugs may be associated with ineffectiveness of different drug regimens and even resistance to drugs are emerging (Al-Mofleh et al., 2007). Thus, there is an urgent need to identify more effective and safe anti-ulcer agents.

A widespread search has been launched to identify new anti-ulcer therapies from natural sources. Herbs, medicinal plants, spices, vegetables and crude drug substances are considered to be a potential source to combat various diseases including gastric ulcer. In the scientific literature, a large number of medicinal plants with gastric anti-ulcer potential have been reported (Al-Mofleh et al., 2008; Devi et al., 2008; Coelho et al., 2009). *G. procumbens* (Merr.) which is known in Malaysia as "Sambung nyawa." is widely distributed in South East

*Corresponding author. E-mail: ammeeen@um.edu.my. Fax: +6003 79676600.

Asian countries such as Indonesia, Malaysia, and Thailand.

The plant is used in the traditional treatment of many ailments such as inflammation, rheumatism, viral diseases of skin, kidney diseases, rashes, fever, migraine, constipation, and cancer (Perry, 1980). The leaves of this plant are not toxic (Rosidah et al., 2009) and have been shown to possess anti-herpes simplex virus (Nawawi et al., 1999), anti-hyperglycemic (Akowuah et al., 2002), anti-inflammatory (Iskander et al., 2002), anti hyperlipidemic (Zhang and Tan, 2000) and anti-hypertensive effects (Kim et al., 2006).

Several studies have shown that GPELE contains several pharmaceutically active chemical constituents, such as flavonoids, saponins, tannins, and terpenoids (Akowuah et al., 2002). Thus far, there is no data available on gastroprotective activity of GPELE. The present study was undertaken to evaluate anti-ulcerogenic properties of GPELE in rats.

MATERIALS AND METHODS

In this study, omeprazole was used as the reference anti-ulcer drug, and was obtained from the University Malaya Medical Centre (UMMC) Pharmacy. The drug was dissolved in carboxymethyl cellulose (CMC) and administered orally to the rats in concentrations of 20 mg/kg body weight (5 ml/kg) according to the recommendation of Pedernera et al. (2006).

Plant specimen and extract preparation

G. procumbens leaves were obtained from Ethno Resources Sdn Bhd, Selangor Malaysia, and identified by comparison with the Voucher specimen deposited at the Herbarium of Rimba Ilmu, Institute of Science Biology, University of Malaya, Kuala Lumpur. The dried leaves were powdered using electrical blender. Hundred grams of the fine powder were soaked in 500 ml of 95% ethanol in conical flask for 3 days. After 3 days the mixture was filtered using a fine muslin cloth followed by filter paper (Whatman No. 1) and distilled under reduced pressure in an Eylea rotary evaporator (Sigma-Aldrich, USA).

The dry extract was then dissolved in CMC (0.25% w/v) and administered orally to rats in concentrations of 50, 100, 200 and 400 mg/kg body weight (5 ml/kg body weight) according to the recommendation of De Pasquale et al., 1995.

Acute toxicity test LD₅₀

Adult male and female *Sprague dawley* rats (6 - 8 weeks old) were obtained from the Animal House, Faculty of Medicine, University of Malaya, Kuala Lumpur (Ethics No. PM 07/05/2008 MAA (a) (R)). The rats weighed between 150 - 180 g. The animals were given standard rat pellets and tap water ad libitum. The acute toxic study was used to determine a safe dose for the rhizome extract. Thirty six rats (18 males and 18 females) were assigned equally each into 3 groups labeled as vehicle (CMC, 0.25% w/v, 5 ml/kg); 2 and 5 g/kg of GPELE preparation, respectively.

The animals fasted over-night (food but not water) prior to dosing. Food was withheld for a further 3 - 4 h after dosing. The animals were observed for 30 min and 2, 4, 8, 24 and 48 h after the administration for the onset of clinical or toxicological symptoms.

Mortality, if any was observed over a period of 2 weeks. The acute toxicity LD₅₀ was calculated as the geometric mean of the dose that resulted in 100% lethality and that which caused no lethality at all. The animals were sacrificed on the 15th day. Histological, hematological and serum biochemical parameters were determined following standard methods (Bergmeyer, 1980; Tietz et al., 1983). The study was approved by the ethics committee for animal experimentation, Faculty of Medicine, University of Malaya, Malaysia. All animals received human care according to the criteria outlined in the "Guide for the Care and Use of laboratory Animals" prepared by the National Academy of Sciences and published by the national Institute of health.

Experimental animals

Sprague dawley healthy adult male rats were obtained from the Experimental Animal House, Faculty of Medicine, University of Malaya, and Ethic No. PM/27/07/2009/MAA (R). The rats were divided randomly into 6 groups of 6 rats each. Each rat that weighed between 200 - 225 g was placed individually in a separate cage (one rat per cage) with wide-mesh wire bottoms to prevent coprophagia during the experiment. The animals were maintained on standard pellet diet and tap water. The study was approved by the Ethics Committee for Animal Experimentation, Faculty of Medicine, University of Malaya, Malaysia. Throughout the experiments, all animals received human care according to the criteria outlined in the "Guide for the Care and Use of laboratory Animals" prepared by the National Academy of Sciences and published by the national Institute of health.

Gastric ulcer-induction by ethanol

The rats fasted for 48 h before the experiment (Garg et al., 1993), but were allowed free access to drinking water up till 2 h before the experiment. Gastric ulcer was induced by orogastric intubation of absolute ethanol (5 ml/kg) according to the method described by De Pasquale et al. (1995) with slight modification. Ulcer control groups were orally administered vehicle (CMC, 0.25% w/v, 5 ml/kg). The reference group received oral doses of 20 mg/kg omeprazole in CMC (5 ml/kg) as positive control.

Experimental groups were orally administered GPELE in CMC solution (5 ml/kg) at doses of 50, 100, 200 and 400 mg/kg. One hour after this pre-treatment all groups of rats were lavaged with absolute ethanol (5 ml/kg) in order to induce gastric ulcers. The rats were euthanized by cervical dislocation 60 minutes later (Paiva et al., 1998) under an overdose of diethyl ether anesthesia and their stomachs were immediately excised.

Gross gastric lesions evaluation

Ulcers of the gastric mucosa appear as elongated bands of hemorrhagic lesions parallel to the long axis of the stomach. Gastric mucosa of each rat was thus examined for damage. The length and width of the ulcer (mm) were measured by a planimeter ($10 \times 10 \text{ mm}^2 = \text{ulcer area}$) under dissecting microscope (1.8x). The ulcerated area was measured by counting the number of small squares, $2 \times 2 \text{ mm}$, covering the length and width of each ulcer band.

The sum of the areas of all lesions for each stomach was applied in the calculation of the ulcer area (UA) wherein the sum of small squares $\times 4 \times 1.8 = \text{UA} (\text{mm}^2)$ as described by Kauffman and Grossman (1978) with slight modification. The inhibition percentage (I.0 %) was calculated by the following formula as described by Njar et al. (1995) with slight modification.

$$(1\%) = [(UA_{\text{control}} - UA_{\text{treated}}) \div UA_{\text{control}}] \times 100\%.$$

Table 1. Effect of GPELE on ulcer area and inhibition percentage in rats.

Animal group	Pre-treatment (5 ml/kg dose)	Ulcer area (mm) ² (Mean ± S.E.M)	Inhibition (%)
1	CMC (Ulcer control)	984.17 ± 5.39 ^a	-
2	Omeprazole (20 mg/kg)	180.00 ± 9.66 ^b	81.71
3	GPELE (50 mg/kg)	391.67 ± 13.02 ^c	60.20
4	GPELE (100 mg/kg)	225.00 ± 5.92 ^d	77.14
5	GPELE (200 mg/kg)	115.00 ± 7.64 ^e	88.35
6	GPELE (400 mg/kg)	55.83 ± 5.39 ^f	94.33

All values are expressed as mean ± standard error mean. Means with different superscripts are significantly different. The mean difference is significant at the 0.05 level.

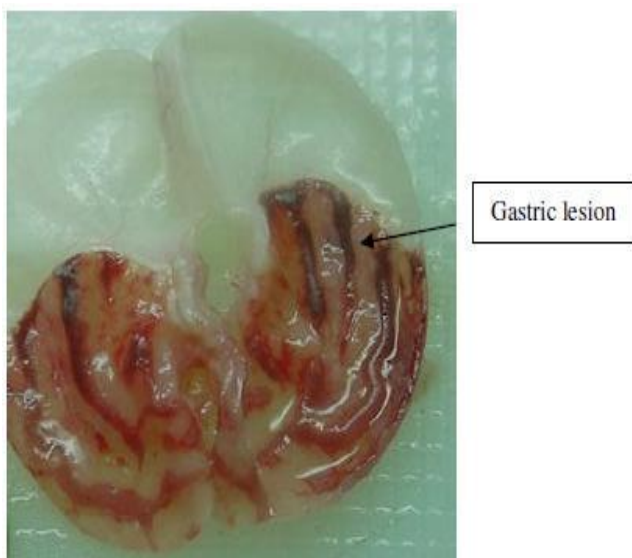


Figure 1a. Gross appearance of the gastric mucosa in a rat pre-treated with 5 ml/kg of CMC (negative control). Severe injuries are seen in the gastric mucosa.

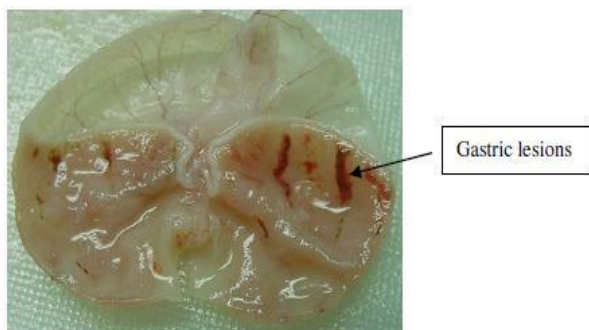


Figure 1b. Gross appearance of the gastric mucosa in a rat pre-treated with 5 ml/kg of omeprazole (20 mg/kg). Injuries to the gastric mucosa are milder compared to the injuries seen in the negative control rat.

Histological evaluation of gastric lesions

Specimens of the gastric walls from each rat were fixed in 10%

buffered formalin and processed in a paraffin tissue processing machine. Sections of the stomach were made at a thickness of 5 μ and stained with hematoxylin and eosin for histological evaluation.

Statistical analysis

All values were reported as mean ± S.E.M. The statistical significance of differences between groups was assessed using one-way ANOVA. A value of $p < 0.05$ was considered significant.

RESULTS

Acute toxicity study

Animals treated with GPELE at a dose of 2 and 5 g/kg were kept under observation for 14 days. All the animals remained alive and did not manifest any significant sign of toxicity at these doses. There were no abnormal signs, behavioral changes, body weight changes, or macroscopic finding at any time of observation. There was no mortality in the above-mentioned doses at the end of 14 days of observation. Histological examination of liver and kidney, hematology and serum biochemistry revealed no significant differences between the different groups. From these results it is concluded that the extract is quite safe even at these higher doses and has no acute toxicity and the oral lethal dose (LD₅₀) for the male and female rats were greater than 5 g/kg body weight.

Gross evaluation of gastric lesions

The anti-ulcer activity of GPELE in ethanol-induced gastric lesion model is shown in Table 1. Results showed that rats pre-treated with GPELE extracts before being given absolute alcohol had significantly reduced areas of gastric ulcer formation compared to rats pre-treated with only CMC (ulcer control group) (Figures 1a, b and c). Moreover, the GPELE significantly suppressed the formation of the ulcers and it was interesting to note the flattening of gastric mucosal folds in rats pretreated with GPELE. It was also observed that protection of gastric mucosa was more prominent in rats pre-treated with 400 mg/kg rhizome extract (Table 1). Furthermore, ethanol-

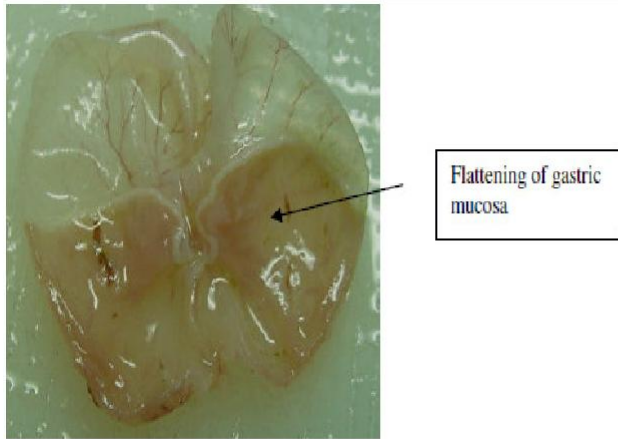


Figure 1c. Gross appearance of the gastric mucosa in a rat pre-treated with 5 ml/kg of GPELE (400 mg/kg). No injuries to the gastric mucosa are seen, instead flattening of gastric mucosa is seen.

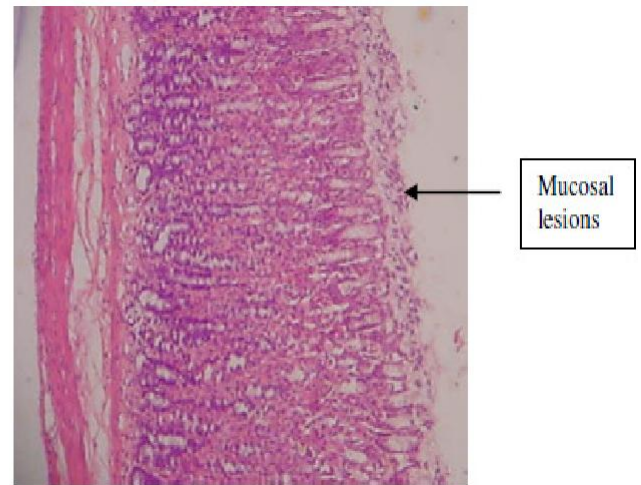


Figure 1e. Histological section of gastric mucosa in a rat pre-treated with 5 ml/kg of omeprazole (20 mg/kg). There is mild disruption to the surface epithelium mucosa with no edema and no leucocytes infiltration of the submucosal layer (H and E stain 10x).

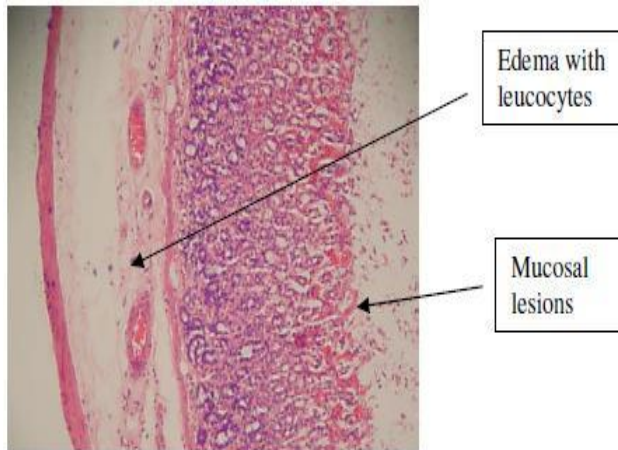


Figure 1d. Histological section of gastric mucosa in a rat pre-treated with 5 ml/kg of CMC only. There is severe disruption to the surface epithelium, and edema of the submucosa layer with leucocyte infiltration (H and E stain, 10x).

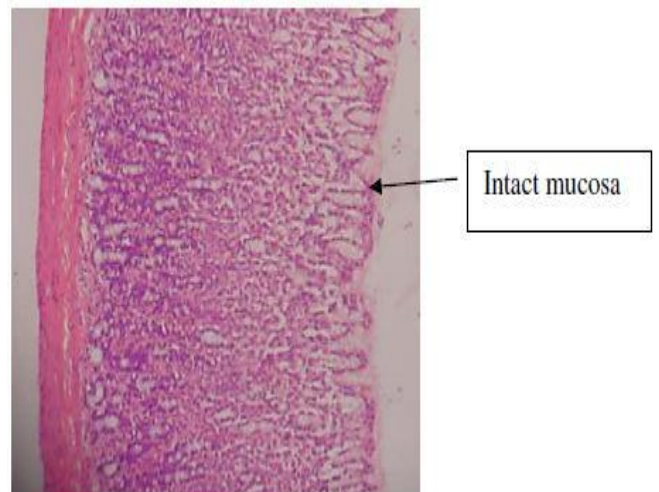


Figure 1f. Histological section of gastric mucosa in a rat pre-treated with 5 ml/kg of GPELE (40 mg/kg). There is no disruption to the surface epithelium with no edema and no leucocytes infiltration of the submucosal layer (H and E stain 10x).

induced mucosal damage was significantly and dose dependently reduced in the size and severity by pretreatment of the animals with GPELE. The significant inhibition of gastric ulcer in pretreatment with GPELE was comparable with omeprazole which is a standard drug used for curing gastric ulcer.

Histological evaluation of gastric lesions

Histological observation of ethanol induced gastric lesions in ulcer control group pre-treated with CMC only, showed comparatively extensive damage to the gastric mucosa, and oedema and leucocytes infiltration of the submucosal layer (Figure 1d). Rats that received pre-

treatment with GPELE had comparatively better protection of the gastric mucosa as seen by reduction in ulcer area, reduced or absent submucosal edema and leucocytes infiltration (Figure 1e and f). The GPELE has been shown to exert the cytoprotective effects in a dose-dependent manner.

DISCUSSION

Peptic ulcers are caused when the natural balances

between the aggressive factors of acid and pepsin and defensive mechanisms of mucus, bicarbonate, mucosal turnover and blood supply (mucosal barrier) are disturbed (Piper and Stiel, 1986). Baron et al., (1980) have suggested that acid and pepsin are relatively less important as causative agents and that a defect in the defensive mechanism of gastric mucosa is the first step toward ulcer formation. Although in most cases the etiology of ulcer is unknown, it is generally accepted that it is the result of an imbalance between aggressive factors and maintenance of the mucosal integrity through the endogenous defense mechanism (Piper and Stiel, 1986).

It is known that gastric lesions produced by ethanol administration appear as multiple-hemorrhagic red bands of different sizes along the glandular stomach. Ethanol is commonly used for inducing ulcer in experimental rats; it leads to intense gastric mucosal damage. Studies suggest that the ethanol-induced damage to the gastrointestinal mucosa starts with microvascular injury, namely disruption of the vascular endothelium resulting in increased vascular permeability, edema formation and epithelial lifting (Szabo et al., 1995). Ethanol produces necrotic lesions in the gastric mucosa by its direct toxic effect, reducing the secretion of bicarbonates and production of mucus (Marhuenda et al., 1993). Exposure to ethanol increases the extension of cellular damage in a dose-dependent way (Mutoh et al., 1990).

Omeprazole is a proton pump inhibitor which has been widely used as an acid inhibitor agent for the treatment of disorders related to gastric acid secretion for about 15 years (Li et al., 2004). Omeprazole has substituted benzimidazoles; it inhibits acid secretion by acting on the hydrogen-potassium exchanger (H^+ , K^+ -ATPase) for the apical plasma membrane of the gastric mucosa (Satoh et al., 1989). Omeprazole is highly selective for the proton pump and undergoes catalyzed conversion into active form within the acid forming space. The active inhibitors react with SH (thiol) group of the proton pump, resulting in inhibition of acid formation (Nagaya et al., 1991).

Oxidative stress plays an important role in the pathogenesis of various diseases including gastric ulcer, with antioxidants being reported to play a significant role in the protection of gastric mucosa against various necrotic agents (Trivedi and Rawal, 2001). Administration of antioxidants inhibits ethanol-induced gastric injury in rat (Ligumsky et al., 1995). GPELE possesses a broad spectrum of biological activities, and the plant extract has been shown to contain pharmaceutically active chemical constituents, such as flavonoids, saponins, tannins, and terpenoids (Akowuah et al., 2002) and it is speculated that the gastroprotective effect exerted by GPELE could be attributed to its antioxidant property. Antioxidant property of the GBELE may possibly counteract oxidative damage caused by absolute ethanol toxicity. The observed anti-ulcerogenic activity may be due to its antioxidant effects and appears to strengthen the mucosal barrier, which is the first line of defense against

endogenous and exogenous ulcerogenic agents. Previous studies have shown that flavonoids may be related to the antiulcer activity (Hiruma-Lima et al., 2006), and play a major role in the mechanism of gastroprotection (La Casa et al 2000). GPELE has been reported to contain flavonoids (Akowuah et al., 2002) and it could be conceivable that the anti-ulcer activity of this plant could be linked to the flavonoids since flavonoids are reported to protect the mucosa by preventing the formation of lesions by various necrotic agents (Saurez et al., 1996). It is well known that many flavonoids display anti-secretory and cytoprotective properties in different experimental models of gastric ulcer (Zayachkivska et al., 2005). Flavonoids possess anti-oxidant properties in addition to strengthening the mucosal defense system through stimulation of gastric mucus secretion (Martin et al., 1994) and flavonoids can scavenge for the reactive oxygen species (super-oxide anions) and free radicals produced by ethanol. These reactive intermediates are potentially implicated in ulcerogenicity (Lewis and Hanson, 1991).

The result of the present study also revealed protection of gastric mucosa and inhibition of leucocytes infiltration of gastric wall in rats pretreated with GPELE. Similarly, Kobayashi et al. (2001) reported that teprenone exerts a protective effect against mucosal lesions through inhibition of neutrophil infiltration in the ulcerated gastric tissue and Shimizu et al. (2000) demonstrated that the reduction of neutrophil infiltration into ulcerated gastric tissue promotes the healing of gastric ulcers in rats. Cheng and Koo (2000) showed that oral administration of plant extract before ethanol administration significantly decreased neutrophil infiltration of gastric mucosa and Fujita et al. (1998) observed that an increase in neutrophil infiltration into ulcerated gastric tissue delayed the healing of gastric ulcers in rats. Absolute alcohol would extensively damage the gastric mucosa leading to increased neutrophil infiltration into the gastric mucosa. Oxygen-free radicals derived from infiltrated neutrophils in ulcerated gastric tissues have inhibitory effect on gastric ulcers healing in rats (Suzuki et al., 1998). Neutrophils mediate lipid peroxidation through the production of superoxide anions (Zimmerman et al., 1997). Neutrophils are a major source of inflammatory mediators and can release potent reactive oxygen species such as superoxide, hydrogen peroxide and myeloperoxidase derived oxidants. These reactive oxygen species are highly cytotoxic and can induce tissue damage (Cheng and Koo, 2000). Furthermore, neutrophil accumulation in gastric mucosa has been shown to induce microcirculatory abnormalities (Bou-Abboud et al., 1988). Suppression of neutrophil infiltration during inflammation was found to enhance gastric ulcer healing (Tsukimi et al., 1996). GPELE have been shown to contain anti-inflammatory activity ((Iskander et al., 2002) and it is speculated that the gastroprotective effect exerted by this plant extract could be attributed to its anti-inflammatory activity. This anti-

inflammatory activity could also be a key factor in the prevention of gastric ulcer as reported by Swanker et al., (2005).

In the present study, we observed flattening of the mucosal folds which suggests that gastroprotective effect of GPELE might be due to a decrease in gastric motility. It is reported that the changes in the gastric motility may play a role in the development and prevention of experimental gastric lesions (Garrick et al., 1986; Takeuchi et al., 1987). Relaxation of circular muscles may protect the gastric mucosa through flattening of the folds. This will increase the mucosal area exposed to necrotizing agents and reduce the volume of the gastric irritants on rugal crest (Takeuchi and Nobuhara, 1985). Ethanol produces a marked contraction of the circular muscles of rat fundic strip. Such a contraction can lead to mucosal compression at the site of the greatest mechanical stress, at the crests of mucosal folds leading to necrosis and ulceration (Mersereau and Hinchey, 1982). The acute toxicity profile of GPELE could be considered favorable, judging from the absence of adverse clinical manifestations in experimental animals after 14 days of observation. It is concluded that the extract has no acute toxicity and that the oral lethal dose for male and female rats is in excess of 5 g/kg.

In conclusion, GPELE could significantly protect the gastric mucosa against ethanol-induced injury. Such protection was shown to be dose dependent as ascertained by the reduction of ulcer areas in the gastric wall as well as the reduction or inhibition of edema and leucocytes infiltration of submucosal layers, and protection was most prominent at a dose of 400 mg/kg rhizome extract. The data obtained confirm the traditional indications for this herb and present a new therapeutic option for the treatment of gastric ailments. The exact mechanism (s) underlying this anti-ulcerogenic effect remain unknown, but it seems that this extract contains pharmacologically active substances with potent antioxidant and anti-inflammatory activity.

ACKNOWLEDGMENTS

The authors express gratitude to the staff of the Faculty of Medicine Animal House for the care and supply of rats, and to the University of Malaya for the financial support UMRG (RG102/09HTM).

REFERENCES

- Akowuah GA, Sadikun A, Mariam A (2002). Flavonoid identification and hypoglycemic studies of butanol fraction from *Gynura procumbens*. *Pharmaceut. Biol.* 40: 405-410.
- Al-Mofleh IA, Alhaider AA, Mossa JS, AlSohaibani MO, Al-Yahya MA, Rafatulla S, Shaik SA (2008). Gastroprotective effect of an aqueous suspension of black cummin *Nigella sativa* on necrotizing agents-induced gastric injury in experimental animals. *Saudi J. Gastroenterol.* 14: 128-134.
- Al-Mofleh IA, Alhaider AA, Mossa JS, Al-Soohaibani MO, Rafatullah S (2007). Aqueous suspension of anise "*Pimpinella anisum*" protects rats against chemically induced gastric ulcers. *World J. Gastroenterol.* 13: 1112-1118.
- Baron TH, Langman MTS, Wastell C (1980). Stomach and duodenum. In: I.A.D/ Bouchier (Ed.), *Recent Advances in Gastroenterology*. Churehill Livingstone, London pp. 23-29.
- Bergmeyer HU (1980). IFCC method for the measurement of catalytic concentrations of enzymes. Part 3. IFCC method for alanine aminotransferase. *Clinica Chimica Acta* 105: 147-154.
- Bou-Abboud CF, Wayland H, Panlsen G, Guth PH (1988). Microcirculatory stasis precedes tissue necrosis in ethanol-induced gastric mucosal injury in rat. *Dig. Dis. Sci.* 33: 872-877.
- Cheng CL, Koo MWL (2000). Effect of *Centella asiatica* on ethanol induced gastric mucosal lesions in rats. *Life Sci.* 67: 2647-2653.
- Coelho RG, Gonzalez FG, Sannomiya M, Di Stasi LC, Vilegas W (2009). Gastric anti-ulcer activity of leaf fractions obtained of polar extract from *Wilbrandia ebracteata* in mice. *Nat. Prod. Res.* 23(1): 51-59.
- De Pasquale R, Germano MP, Keita A, Sanogo R, Lauk L (1995). Antiulcer activity of *Pteleopsis suberosa*. *J. Ethnopharmacol.* 47: 55-58.
- Devi RS, Kist M, Vani G, Devi CS (2008). Effect of methanolic extract of *Terminalia arjuna* against *Helicobacter pylori* 26695 lipopolysaccharide-induced gastric ulcer in rats. *J. Pharm. Pharmacol.* 60(4): 505-514.
- Fujita H, Takahashi S, Okabe S (1998). Mechanism by which indomethacin delays the healing of acetic acid-induced ulcers in rats. Role of neutrophil antichemotactic and chemotactic activities. *J. Physiol. Pharmacol.* 49: 71-82.
- Garg GP, Nigam SK, Ogle CW (1993). The gastric antiulcer effects of the leaves of the neem tree. *Planta Medica* 59: 215-217.
- Garrick T, Buack S, Bass P (1986). Gastric motility is major factor in cold, restraint induced lesion formation in rats. *Am. J. Physiol.* 250: 6191-6199.
- Hiruma-Lima CA, Calvo TR, Rodrigues CM, Andrade FD, Vilegas W, Brito AR (2006). Antiulcerogenic activity of *Alchornea castaneafolia*: effects on somatostatin, gastrin and prostaglandin. *J. ethnopharmacol.* 104: 215-224.
- Iskander MN, Song Y, Coupar IM, Iratchariyakul W (2002). Anti-inflammatory screening of the medicinal plant *Gynura procumbens*. *Plant Foods Human Nutr.* 57: 233-244.
- Kauffman GL, Grossman MI (1978). Prostaglandin and cimetidine inhibit the formation of ulcers produced by parenteral salicylates. *Gastroenterology* 75: 1099-2102.
- Khazaei M, Salehi H (2006). Protective effect of *Falcaria vulgaris* extract on ethanol induced gastric ulcer in rats. *Iran J. Pharmacol. Ther.* 5: 43-46.
- Kim M, Lee HL, Wiryowidagdo S, Kim HK (2006). Antihypertensive effects of *Gynura procumbens* extract in spontaneously hypertensive rats. *J. Med. Food* 9: 587-590.
- Kobayashi T, Ohta Y, Yoshino J, Nakazawa S (2001). Teprenone promotes the healing of acetic acid-induced chronic gastric ulcers in rats by inhibiting neutrophil infiltration and lipid peroxidation in ulcerated gastric tissues. *Pharmacol. Res.* 43: 23-30.
- La Casa C, Villegas I, Alarcon de la Lastra C, Motilva V, Martin Calero MJ (2000). Evidence for protective and antioxidant properties in rutin, a natural flavone, against ethanol induced gastric lesions. *J. Ethnopharmacol.* 71: 45-53.
- Lewis DA, Hanson PJ (1991). Antiulcer drugs of plant origin. *Progress Med. Chem.* 28: 210-229.
- Li X, Andersson TB, Ahlstrom M, Weidolf L (2004). Comparison of inhibitory effects of proton pump inhibiting drugs omeprazole, esomeprazole, lansoprazole, pantoprazole and rabeprazole on human cytochrome P450 activities. *Drug Metab. Dispos.* 32: 821-827.
- Ligumsky M, Sestieri M, Okon F, Ginsburg I (1995). Antioxidants inhibit ethanol-induced gastric injury in the rat. Role of manganese, glycin and carotene. *Scandinavian J. Gastroenterol.* 30: 854-860.
- Marhuenda E, Martin MJ, Alarcon de la Lastra C (1993). Antiulcerogenic activity of aescine in different experimental models. *Phytother. Res.* 7: 13-16.
- Martin MJ, Marhuenda E, Perez-Guerrero C, Franco JM (1994). Antiulcer effect of naringin on gastric lesion induced by ethanol in

- rats. *Pharmacology* 49: 144-150.
- Mersereau AW, Hinchey EJ (1982). Role of gastric mucosal folds in formation of focal ulcer in rats. *Surgery* 91: 150-155.
- Mizui T, Sato H, Hirose F, Doteuchi M (1987). Effect of antiperoxidative drugs on gastric damage induced by ethanol in rats. *Life Sci.* 41: 755-763.
- Mutoh H, Hiraishi H, Ota S, Ivey KJ, Terano A, Sugimoto T (1990). Role of oxygen radicals in ethanol-induced damage to cultured gastric mucosal cells. *Am. J. Physiol.* 258: G603-G609.
- Nagaya H, Inatomi N, Ohara A, Satoh H (1991). Effects of the enantiomers of lansoprazole (AG-1749) on H⁺/K⁺-ATPase activity in canine gastric microsomes and acid formation in isolated canine parietal cells. *Biochem. Pharmacol.* 42: 1875-1878.
- Nawawi A, Nakamura N, Hattori M, Kurokawa M, Shiraki K (1999). Inhibitory effects of Indonesian medicinal plants on the infection of herpes simplex virus type-1. *Phytother. Res.* 13: 37-41.
- Njar VCO, Adesanwo JK, Raji Y (1995). Methyl angolensate: the antiulcer agent of the stem bark of *Entandrophragma angolense*. *Planta Medica* 61: 91-92.
- Paiva LAF, Rao VSN, Gramosa NV, Silveira FR (1998). Gastroprotective effect of *Copaifera langsdorffii* oleo-resin on experimental gastric ulcer models in rats. *J. Ethnopharmacol.* 62: 73-78.
- Pedernera AM, Guardia T, Caleron CG, Rotelli AF, de la Rocha NF, di Genaro S, Pelze LF (2006). Antiulcerogenic and anti-inflammatory activity of the methanolic extract of *Larrea divaricata* Cav. in rat. *J. Ethnopharmacol.* 105: 415-420.
- Perry LM (1980). *Medicinal Plants of East and Southeast Asia: Attributed Properties and Uses*, MIT Press, Cambridge, M.A. pp. 94-95.
- Piper DW, Stiel D (1986). Pathogenesis of chronic peptic ulcer, current thinking and clinical implications. *Med. Prog.* 2: 7-10.
- Rosidah YMF, Sadikun A, Ahmad M, Akowuah GA, Asmawi MZ (2009). Toxicology evaluation of standardized methanol extract of *G. procumens*. *J. Ethnopharmacol.* 123: 244-249.
- Satoh H, Inatomi N, Nagaya H, Ianda I, Nohara A, Nakamura H (1989). Antisecretory and antiulcer activities of novel proton pump inhibitor AG-1749 in dogs and rats. *J. Pharmacol. Exp. Ther.* 248: 806-815.
- Saurez J, Herreta, M.D, Marhuenda E (1996). Hesperidin and neohesperidin dihydrochalcone on different experimental models of induced gastric ulcer. *Phytother. Res.* 10: 616-618.
- Shimizu N, Watanabe T, Arakawa T, Fujiwara Y, Higuchi K, Kuroki T (2000). Pentoxifylline accelerates gastric ulcer healing in rats: roles of tumor necrosis factor alpha and neutrophils during the early phase of ulcer healing. *Digestion* 6: 157-164.
- Suzuki Y, Ishihara M, Ito M (1998). Anti-ulcer effects of antioxidants, quercetin, α -tocopherol, nifedipine and tetracycline in rats. *Japanese J. Pharmacol.* 78: 435-441.
- Szabo S, Kusstatscher S, Sakoulas G, Sandor Z, Vincze AA, Jadus M (1995). 'Growth factors: New "endogeneous drug" for ulcer healing', *Scandinavian J. Gastroenterol.* 210: 15-18.
- Takeuch K, Nobuhara Y (1985). Inhibition of gastric motor activity by 16, 16-dimethyl-prostaglandin E₂; a probable explanation of cycloprotection. *Dig. Dis. Sci.* 30: 1181-1188.
- Takeuchi K, Nishiwakki K, Okabe S (1987). Effect of dopamine on gastric mucosal lesion induced by ethanol in rats—possible involvement of antigestric motor activity mediated with alpha 2 adrenoreceptors. *Dig. Dis. Sci.* 31: 1100-1107.
- Tietz NW, Rinker AD, Shaw LM (1983). IFCC methods for the measurement of catalytic concentration of enzymes. Part 5. IFCC method for alkaline phosphatase. *J. Clin. Chem. Clin. Biochem.* 21: 731-748.
- Trivedi NP, Rawal UM (2001). Hepatoprotective and antioxidant property of *Andrographis paniculata* Nees in BHC induced liver damage in mice. *Indian J. Exp. Biol.* 39: 41-46.
- Tsukimi Y, Nozue C, Okabe S (1996). Effects of teminoprazole, omeprazole and sucralfate on indomethacin-induced delayed healing of kissing gastric ulcers in rats. *J. Gastroenterol. Hepatol.* 11: 335-340.
- Zayachkivska OS, Konturek SJ, Drozdowicz D, Konturek PC, Brzozowski T, Ghegotsky MR (2005). Gastroprotective effects of flavonoids in plant extracts. *J. Physiol. Pharmacol.* 56: 219-231.
- Zhang XF, Tan BK (2000). Effects of an ethanolic extract of *G. procumbens* on serum glucose, cholesterol and triglyceride levels in normal and streptozotocin-induced diabetic rats. *Singapore Med. J.* 41: 9-13.
- Zimmerman JJ, Ciesielski W, Lewandoski J (1997). Neutrophil-mediated phospholipids peroxidation assessed by gas chromatography-mass spectroscopy. *Am. J. Physiol.* 273: 653-661.