

Full Length Research

A case report of anti-parathyroid hormone immunotherapy for parathyroid carcinoma

Jianbo Zhang, Feng Tong, Weixia Zhong and Sheng Li*

Department of Surgery, Shandong Tumor Hospital, Jinan 250117, China.

Accepted 30 March, 2019

Parathyroid carcinoma is a unique malignant tumor, the primary clinical manifestations of which are hyperfunction of the parathyroid gland, various metabolic disorders secondary to hypercalcemia and corresponding impairment of tissues and organs. A complete laboratory examination, accurate imaging, and reliable histopathologic findings are critical to the diagnosis of parathyroid carcinoma. Parathyroid carcinoma is insensitive to chemotherapy and radiotherapy. Immunotherapy is a technology developed in recent years that provides a novel pathway to treat hypercalcemia that is resistant to traditional therapeutic methods. In this study, an anti-parathyroid hormone (PTH) autoantibody produced by the immunization of artificially synthesized human and bovine PTH peptide was used. We aimed to report the efficacy of this therapy in the treatment of parathyroid carcinoma.

Key words: Parathyroid carcinoma, immunotherapy, anti-parathyroid hormone.

INTRODUCTION

Parathyroid carcinoma (PTC) is a distinct endocrine disease originating from parathyroid parenchymal cells, and it was first reported by Armstrong (1938). PTC is rare, and the majority of patients have primary hyperparathyroidism (PHPT). Non-functional PTC is very rare and accounts for 0.1 to 0.5% in PHPT (Stephenson, 2006). However, Montenegro et al. (2006) reported that incidence of non-functional PTC was only 6.1%, and accounts for 3.5% of Chinese PHPT in recent years (Zhou and Tian, 2007).

The most difficult challenge of treating advanced parathyroid carcinoma is the resultant severe hypercalcemia that induces a parathyroid crisis. Moreover, the tumor is difficult to resect and current chemotherapies do not prevent tumor growth. Therefore, many drugs target the inhibition of calcium release from bone and activation of urinary calcium excretion. In this case, a patient was initially misdiagnosed as having an osseous lung cancer metastasis at an outside hospital. Apparently, although the primary lesion was surgically resected, the outside hospital continued to target a metastatic focus-induced hyperparathyroidism, hypercalcemia crisis, osteoporosis,

pulmonary infection, and cardiovascular system abnormalities. These were extremely difficult to treat, but the application of calcitonin, zoledronic acid, and sensipar did help regulate blood calcium for some time.

In recent years, immunotherapy has come to provide new therapeutic methods for hypercalcemia that is intractable to traditional treatments. Bradwell and Harvey (1999) applied human and bovine PTH-34 polypeptide (N-terminal sequence with biological activity), PTH33-52, and PTH5-84 as immunogen to immune PTC patients and successfully reduced serum PTH and hypercalcemia. This was the first evidence to demonstrate that immunotherapy using PTH can not only improve clinical symptoms (measured objectively with hormone and biochemical indicators), but it also has anti-tumor effects. Nevertheless, this method has only been applied in a few cases worldwide, and no large-scale studies have been conducted. Moreover, there are some case reports of patients who died after PTH immunotherapy. Therefore, the therapeutic benefits versus the adverse effects of this method remain to be defined.

CASE INTRODUCTION

A 41-year old female patient was admitted in our hospital. She was suffering from nephrolithiasis, and was recovering

*Corresponding author. E-mail: drlisheng@sohu.com. Tel: +86-13705311949. Fax: +86-531-87984079.

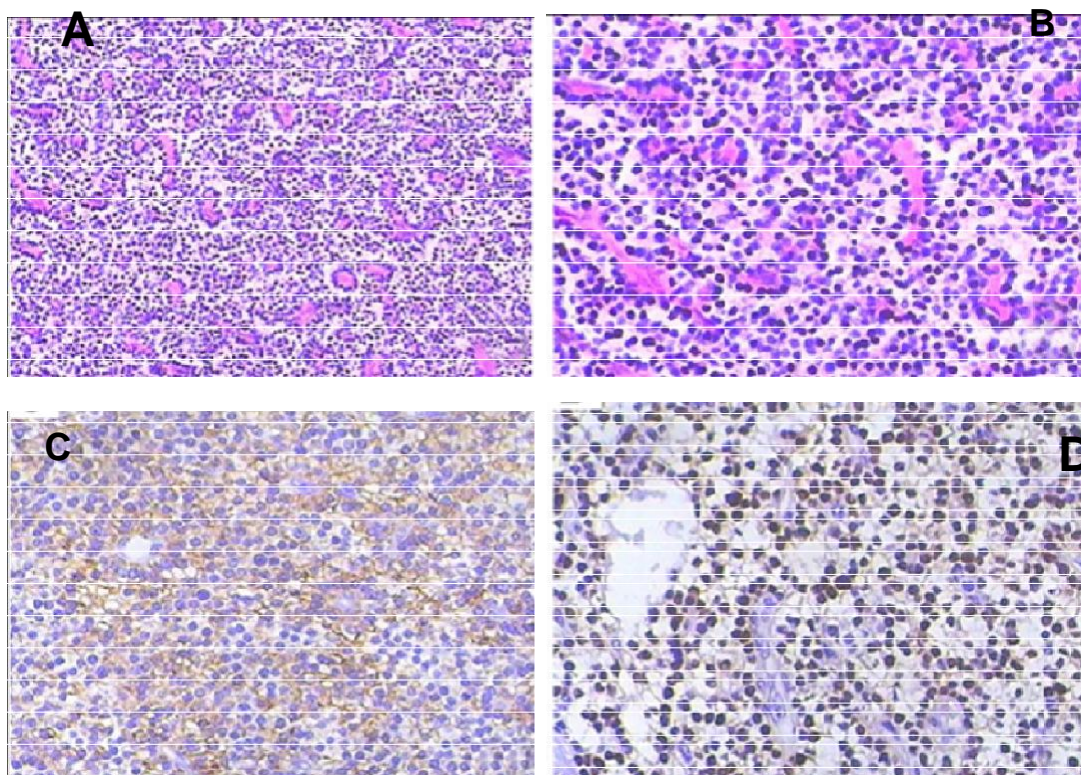


Figure 1. Parathyroid carcinoma, invading the capsule and peripheral fat; (A) HE staining (x 100); (B) HE staining (x 200); (C) CgA staining (x 200); (D) cyclin D1 staining (x 200).

recovering well after urinary calculus removal. Since October 14, 2006, she had weakness and systemic bone and joint pain of a nonspecific cause that gradually worsened. At that time, the patient was not treated, and she had no evidence of limitations of mobility, joint malformations, joint stiffness, psychiatric or neurological symptoms, nausea or vomiting, or progressing myalgias. After physical examination on April 3, 2007, an anterior cervical mass was detected. A chest x-ray revealed extensive pulmonary mottling. Then, PET-CT revealed the following results: 1) evidence of bone destruction, as evidenced by increased fluorodeoxyglucose uptake, in the bilateral scapula, bilateral clavicle, 5th, 7th and 10th, costal bone in the left side, bilateral ileum and pubis, and left patella, 2) multiple nodules in both lungs, and 3) increased lymphadenopathy under the right lobe of the thyroid gland and low FDG metabolism. Importantly, tumor cells were not found during bone marrow cytology. The patient was diagnosed with osseous metastasis of lung cancer. An EP chemotherapy regimen (PDD and VP16) was subsequently started. Three days later, the patient presented with spasm of the limbs and an explosive headache; however, these were not known side effects of the chemotherapy regimen that she was prescribed. A laboratory assay revealed that the PTH level was 4800 pg/ml and blood calcium was 3.7 mmol/l. With this information, the clinical diagnosis was revised to PTC complicated by pulmonary metastasis. A right

parathyroidectomy and partial left parathyroidectomy were performed on May 8, 2007. The pathological results indicated that the right PTC invaded the capsule and peripheral fat. Immunohistochemistry revealed CgA (++) , cyclinD1 (+), PCNA-positive cell numbers <1%, Syn (-), NF (-), TG (-), bcl-2 (-), p53 (-), Ki67 (-), TTF-1 (-), CEA (-), and calcitonin (-) tumor cells (Figure 1). The biochemistry examination was obtained after the surgery on May 22, 2007, and revealed that blood calcium was reduced to 3.1 mmol/l and PTH levels were reduced to 2246 pg/ml. After 2 months of treatment with diphosphonate and calcitonin, blood calcium was reduced to 3.06 mmol/l, and PTH was reduced to 1980 pg/ml. At this time, the patient desired to be treated at home, and she was discharged.

The patient stopped using other therapies after discharge, and only the inhibitive calcium agent sensipar (cinacalcet hydrochloride) was administered. The patient's blood calcium was comparatively steady during the administration of sensipar, and was maintained around 3.0 mmol/l. PTH was maintained around 2800 pg/ml. In September 2008, the patient presented with nausea, vomiting, reduction of food intake, and hallucinations, and severe weight loss over 20 days. At this point, treatment with sensipar was stopped. The patient had systemic skeletal and joint pain after drug withdrawal, especially in the lumbar vertebrae, left hip, and thigh. The pain progressed and affected her mobility. On May 2, 2009, the patient presented with difficulty

ambulating and gradually became bed-bound. Treatment with diphosphonate drugs and calcitonin was tried for 1 month, but the therapeutic effect was not satisfying.

Unfortunately, the patient fractured her left forearm on June 17, 2009. A few months later, on September 10, oral morphine was used for analgesia, and the patient's appetite and sleep habits were poor. She was readmitted for therapy on September 28, 2009. The blood chemistries revealed blood calcium 3.75 mmol/l, blood phosphorous 0.61 mmol/l, AKP 607.8 U/l, and PTH >5000 pg/ml. The patient was diagnosed with pulmonary metastases of PTC, primary hyperfunction of the parathyroid gland, hypercalcemia crisis, and osteoporosis. During hospitalization, treatment of hypokalemia and hypomagnesemia were well treated. Zoledronic acid was administered to inhibit osteoclast activity, and calcitonin was used to reduce blood calcium. Moreover, anti-pulmonary infection antibiotics were given. Also, after treatment was administered to improve heart function and targeted supportive therapy was started, the patient's condition was steady. Her blood calcium was reduced to 3.71 mmol/l, and her blood potassium rose to within normal range. She was then discharged on December 14, 2009. However, on January 3, 2010, the patient presented with respiratory depression, chest distress, and altered mental status of unknown cause. Her symptoms did not improve with supplemental oxygen. The biochemical examination indicated blood calcium of 2.45 mmol/l. It was subsequently discovered that the patient had received an injection of artificial synthesized PTH mixed peptide for immunotherapy to regulate PTH one week before this episode. According to the method reported by Bradwell and Harvey (1999), the patient used 200 µg human and bovine PTH synthesized peptide (1-34 PTH peptide sequences of human and bovine PTH) and 50 µg human PTH for the treatment. In response, her blood calcium fell significantly to 2.45 mmol/l. Interestingly though, the patient's previous blood calcium had been maintained at comparatively high levels for a long time (maximum value of 3.75 mmol/l); therefore, the evident reduction of blood calcium caused her to be effectively hypocalcemic. This, in turn, reduced her resistance to pulmonary infection, and also resulted in decreased appetite and diarrhea. Secondly, she also had clinical manifestation of hypoglycemia and respiratory failure. Although the patient received treatment, including anti-infection and nutritional support, fluids and electrolytes, mechanical ventilation, and symptomatic treatment, the patient still developed multiple organ failure, respiratory failure, heart failure, and septic shock. Finally, the patient and her family members decided to stop all interventions, and patient expired shortly thereafter.

DISCUSSION

PTC is a unique endocrine disease with low morbidity,

which mostly occurs equally in middle-aged and young men and women. Although many researchers have performed systematic studies on PTH, its etiological factors are still unknown. The mean age of onset is 44 to 54 years old (DeLellis, 2005). Some previous studies (Kebebew, 2008; Iihara et al., 2007) considered that predisposing factors for this disease may include a history of head and neck radiotherapy, chronic renal failure, familial hyperparathyroidism, and hyperparathyroidism-jaw tumor syndrome (HPT-JT). The serological results mainly reflect refractory hypercalcemia and hyperparathyroidemia. The blood calcium was usually higher than 3.2 mmol/l, whereas blood serum PTH was often more than 2-fold above the normal value. The majority of the cells that was involved in PTC have a secretory function and generate a large amount of PTH. The blood PTH in PTC patient is typically 2 to 4 folds higher than normal but can be up to 10-fold higher than normal (normal reference value: 1.6 to 6.9 mmol/l). The concentration of blood calcium was over 3.2 mmol/l (normal reference value: 2.1 to 2.7 mmol/l). Serum alkaline phosphatase also increased (normal reference value: 47 to 138 IU/l). Further, hypophosphatemia was also present (normal reference value: 0.81 to 1.45 mmol/l). Lastly, a urinary calcium greater than 7.5 mmol/24 h also had diagnostic significance.

The clinical manifestation of PTC includes secondary osteoporosis and pathological fracture. Accompanying the change in blood calcium metabolism, urolithiasis may occur and renal colic may result. Pancreatic lithiasis causing pancreatitis may develop. As it increases in size, a tumor can be palpable in the neck, but a few tumors will be present retrosternally. The texture of the tumor is often solid. It can invade the recurrent laryngeal nerve resulting in hoarseness and vocal cord paralysis. Moreover, some patients may develop severe metabolic disorders, psychiatric symptoms, and parathyroid crisis as the tumor grows and metastasizes. Metastases can occur anywhere but tend to be located mainly in the cervical lymph nodes, lungs, liver, and bones. Diagnosis of parathyroid crisis must include three conditions (Asagoe et al., 1995): 1) it can be confirmed as primary hyperparathyroidism (PHPT) by final diagnosis; 2) the serum calcium concentration must be > 3.5mmol/l; 3) symptoms of clinical crisis such as gastrointestinal, cardiovascular, and neuromuscular symptoms will be present. Once a parathyroid crisis occurs, without active treatment, mortality is extremely high.

Smith and Castleman (1993) considered the pathological characteristics of PTC as follows: 1) the texture of the tumor is rigid, 2) there is evidence of fibrous envelopes and/or trabeculae, 3) there is a rose style cellular pattern within the tumor, and 4) active mitosis is observed.

The treatment of PTC is aimed to cure cancer and control severe impairment of the hyperparathyroid. Because the primary damage caused by PTC consists of

metabolic complications resulting from hyperparathyroidism rather than the growth of tumor itself, only targeted medicine can treat inoperable or incompletely resected PTC-induced hypercalcemia. This patient had used calcitonin, zoledronic acid and Sensipar to control blood calcium for some time. Sensipar (cinacalcet hydrochloride) (Figure 2) can bind to calcium sensitive receptors in the parathyroid gland and reduce the secretion of PTH, thereby inducing the reduction of products of serum calcium and calcium acid phosphate. The drug was taken orally and dosed at 30 mg/ tablet. The tablet can be swallowed whole and taken with food, and a single dose of the tablet was prescribed every 2 to 4 weeks (increase progressively at a dose of 60, 90, 120 and 180 mg/day) according to the response of the patient. This was done until the patient's PTH level achieved the recommended value suggested by the American Kidney Foundation Clinical Guide (150 to 300 pg/ml). During the administration of the drug, iatrogenic hypocalcemia should be prevented. Therefore, both blood calcium and phosphorous need to be detected regularly after starting medication. The most common adverse events of this drug in the clinical trial were nausea, vomiting and diarrhea. Our patient stopped using the drug ultimately due to severe and intolerable nausea and vomiting.

In recent years, immunotherapy has provided novel therapeutic approaches to the treatment of hypercalcemic patients who showed no response to traditional methods. Schott et al. (2000) applied tumor lysates *in vitro* and that successfully induced dendritic cells to produce specific anti-tumor immunity. Additionally, the *in vivo* experiment also showed that dendritic cells, after a successful induction, can reduce a patient's parathyroid hormone level.

Specifically, Bradwell and Harvey (1999) applied PTH1-34 polypeptide sequence (N-terminal sequence with biological activity), PTH33 – 52 and PTH51 - 84 from human and bovine parathyroid hormone as an immunogen. The modification of fragments of human parathyroid hormone was achieved by substituting and inserting monoamino acids in each peptide fragment. The human polypeptide was modified in position 2; in this location, random amino acids were inserted. For the bovine polypeptide, however, no changes were made. The fragments of PTH peptide synthesized with lysine were a multiple antigen peptide (octamer) associated with a lysine core (provided by Alta Bioscience of Birmingham University in UK); this increased immunogenicity. Subsequently, these immunogens were mixed with commercially produced integrated molecules of human parathyroid hormone (Mount St. Helens Merseyside of United Kingdom, European Peninsula Inc). This kind of mixture was then dialyzed with sterile normal saline and mixed with Freund's complete adjuvant at a proportion of 40 to 60. Specific formulations are shown as follows. First, 200 µg synthetic peptides from human and bovine PTH (1-34PTH from human and bovine PTH) and 50 µg human

PTH were used for the immunity treatment of the patients. Then, the identical antigen was injected in the 4th and 11th weeks. Subsequently, another synthetic peptide (human PTH51-84 and PTH51-86) was used in the 14th and 17th week. The injection contained the aforementioned four different kinds of peptide sequences at the 18th week. In the 27th week, the injection containing human and bovine PTH1-34, 32-53 and carboxyl-terminal peptide was performed in order to achieve full PTH sequential immunity. The immunity of patients with parathyroid carcinoma successfully reduced the patients' serum parathyroid hormone level and hypercalcemia. This is the first evidence demonstrating that PTH immunotherapy not only can improve clinical symptoms measured by objective hormone and biochemical indicators, but it can also have anti-tumor activity. Yamada et al. (2009) used anti-PTH immunotherapy for patients with pulmonary metastases of parathyroid carcinoma and successfully improved the patients' serum calcium and PTH levels. Meanwhile, they also found that pulmonary metastases were reduced. Basically, the goal of immunotherapy is to increase the patients' own natural antibodies to fight the cancer. However, worldwide and large-scale studies are needed. Furthermore, some patients have died after receiving this type of immunotherapy, which also suggests that the efficacy and safety of this therapy should be more thoroughly researched.

Successful immunotherapy depends on a series of variables including cellular uptake of the antigen, effective expression of T and B lymphocyte antigens, successful T-B mutual effect, and, ultimately, production of a sufficient immune response. All of this requires that the endogenously-produced antibody should have a high degree of affinity and sufficient concentration to reduce PTH to levels undetectable by endogenous receptors. The application of peptide fragments of PTH 1-34 with biological activity may better generate antibodies rather than cytotoxic T lymphocytes. In addition, application of Freund's complete adjuvant can provide high-titer and high-affinity antibodies as well as destroy self antigen. The excessive anti-PTH antibody neutralized serum PTH, which effectively downregulated the receptors, and consequently the absorption of intestinal calcium decreased and osteolysis was inhibited. Thus, metastasis was reduced and normal PTH function ensued.

According to the method reported by Bradwell and Harvey (1999), their patients received 200 µg of synthetic peptides from human and bovine PTH (The 1-34 PTH peptide sequence of human PTH was SXSEIQLMHNLGKHLNSMERVEWLRKKLQDVHNF– (octomeric MAP), and the sequence of Bovine PTH 1-34 was VSEIQFMHNLGKHLSSMERVEWLRKKLQDVHNF– (octomeric MAP)) and 50 µg human PTH. After the injection of artificial synthetic PTH mixed peptide fragments, the patient's blood calcium was significantly decreased as compared to pre-treatment levels; therefore, we considered that the reduction was correlated with the

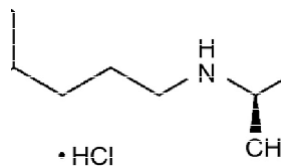


Figure 2. Sensipar (cinacalcet hydrochloride).

application of the treatment. Nevertheless, this reduced serum calcium to a relatively hypocalcemic level in our patient who had sustained serum calcium levels of up to 3.75mmol/l for a sustained period of time. Thus, the patient had a severe pulmonary infection that led to pulmonary failure. Therefore, simply lowering a patient's calcium is not a solution.

Calcium ions can promote the biological activity of cells in the body and are involved in complement activation. Moreover, calcium can enhance the efficacy of lymphocyte transformation. Therefore, calcium plays a critical role in the immune function in the body. The patients with hypocalcemia showed disturbances of body fluid and cellular immune function. This resulted in the down regulation of immune function. Currently, we think that the patient's immune dysfunction was induced by hypocalcemia and, thus, the application of PTH peptide immunotherapy might have directly induced humoral and cellular immune dysfunction. Further studies are needed to confirm this idea. As the patient's immune function was very low, and she had increased susceptibility to pulmonary infections. She also had severe diarrhea and hyponatremia, hypoglycemia and, finally, respiratory failure. Therefore, we still need to be cautious when applying immunotherapy.

This case demonstrates that immunotherapy can control the non-metastatic complications of malignant tumors, block the reactivity of B cells toward human PTH when PTH peptide immunotherapy is given, and can stimulate the body to generate anti-PTH autoantibodies.

This therapy can be used to treat various endocrine tumors so as to control the excessive production of hormones, and it can potentially treat other diseases, too. However, the long-term efficacy of PTH immunotherapy still needs further observation. Moreover, the ratio of risks to benefits should be weighed before performing similar immunotherapy on patients with parathyroid carcinoma.

REFERENCES

- Arm strong HG (1938). Primary carcinoma of parathyroid gland with report of case. *Bull. Acad. Med. Toronto*, 11: 105-110.
- Stephenson TJ (2006). Prognostic and predictive factors in endocrine tumours. *Histopathology*, 48: 629-643.
- Montenegro FL, Tavares MR, Durazzo MD, Cernea CR, Cordeiro AC, Ferraz AR (2006). Clinical suspicion and parathyroid carcinoma management. *Sao. Paulo. Med. J.* 124: 42-44.
- Zhou JP, Tian YL (2007). Surgical treatment for patients with primary hyperparathyroidism. *Chin. J. Surg.*, 16: 78-80.
- Bradwell AR, Harvey TC (1999). Control of hypercalcaemia of parathyroid carcinoma by immunisation. *Lancet*, 353: 370-373.
- DeLellis RA (2005). Parathyroid carcinoma: an overview. *Adv. Anat. Pathol.*, 12: 53-61.
- Kebebew E (2008). Parathyroid carcinoma, a rare but important disorder for endocrinologists, primary care physicians, and endocrine surgeons. *Thyroid*, 18: 385-386.
- Iihara M, Okamoto T, Suzuki R, Kawamata A, Nishikawa T, Kobayashi M, Obara T (2007). Functional parathyroid carcinoma: Long-term treatment outcome and risk factor analysis. *Surgery Discussion*, 142: 936-943, 943-931.
- Asagoe T, Takami H, Hanatani Y, Kodaira S (1995). Parathyroid crisis. *Nippon Rinsho*, 53: 925-929.
- Smith JF, Castleman B (1993). Pathologic diagnosis of parathyroid carcinoma. *Clin. Endocrinol.*, 38: 662.
- Schott M, Feldkamp J, Schattenberg D, Krueger T, Dotzenrath C, Seissler J, Scherbaum WA (2000). Induction of cellular immunity in a parathyroid carcinoma treated with tumor lysate-pulsed dendritic cells. *Eur. J. Endocrinol.*, 142: 300-306.
- Yamada T, Muguruma H, Yano S (2009). Intensification therapy with anti-parathyroid hormone-related protein antibody plus zoledronic acid for bone metastases of small cell lung cancer cells in severe combined immunodeficient mice. *Mol. Cancer Ther.*, 8: 119-126.