

Full Length Research Paper

Analysis of predictors of root resorption in orthodontic treatment

Oliveira, Antônio Geraldo de^{1*}, Consolaro, Alberto², Junqueira, José Luiz Cintra¹
Martins-Ortiz, Maria Fernanda³ and Franzolin, Solange de Oliveira Braga³

¹São Leopoldo Mandic, Campinas, SP, Brazil.

²University of São Paulo, Bauru and Ribeirão Preto, SP, Brazil.

³University of Sagrado Coração, SP, Brazil.

Accepted 14 April, 2019

To study predictors of root resorption in orthodontic treatment from 407 records, 377 pre- and post-treatment periapical radiographs of permanent maxillary central incisors of 199 patients treated with fixed appliances were divided according to overjet, overbite, age, gender and endodontic treatment. Changes in root length between the onset and completion of orthodontic treatment were measured in digitized images and statistically compared using student t, one-way ANOVA and Tukey tests. There was no correlation between increased overjet, overbite and root resorption or with anterior open bite (0.924 and 0.5772). Root resorption was significantly lower in children younger than 10 years when compared to adults ($P = 0.0017$) and even lower in adolescents when compared to adults ($P = 0.0003$). There was higher prevalence of root resorption in males simultaneously with higher number of pipette-shaped and dilacerated apical root morphology ($P = 0.034$). Endodontically treated teeth were not more susceptible to root resorption ($P = 0.208$). Increased overjet and overbite did not present positive relation with root resorption. There was no difference in root resorption between vital and endodontically treated teeth. Age and gender presented positive relation with root resorption. Susceptibility to root resorption during orthodontic treatment may be related to apical morphology.

Key words: Root resorption, orthodontic treatment, tooth movement.

INTRODUCTION

The literature reveals different opinions on the correlation between age and external apical root resorption after orthodontic treatment, with positive correlation for some authors (Linge and Linge, 1983; Brezniak and Wasserstein, 1993; Mirabella and Artun, 1995a; Mavragani et al., 2000; Sameshima and Sinclair, 2001; Ren et al., 2008), and no correlation for others (Phillips, 1955; McFadden et al., 1989; Baumrind et al., 1996; root resorption between genders (Beck and Harris, 1994). However, most studies (Linge and Linge, 1983; McFadden et al., 1989; Parker and Harris, 1998; Nigul and Jagomagi, 2006). According to Consolaro (2005), with regard to orthodontic treatment in adults, the difference is not related to normal tissues. When the adult

patient presents chronic inflammatory periodontal disease, there are sequels such as reduced height of the alveolar bone crest and increased clinical crown, altering the crown/root ratio. These differences should modify the orthodontic treatment planning. Periodontally healthy adults do not present higher occurrence of root resorption when compared to equally healthy young individuals.

The considerable difference in hormone levels between genders has led to the empirical assumption formerly, that there would be some differences in susceptibility to Sameshima and Sinclair, 2001; Nigul and Jagomagi, 2006; Santamaria, 2009) did not reveal any difference re-garding gender in the occurrence of apical root resorption after orthodontic treatment with fixed appliances. As mentioned by Consolaro (2005) and Consolaro et al. (2009), female patients are not more predisposed to root resorption as presumed in the past.

Some studies reported smaller occurrence of root resorption in endodontically treated teeth when compared to vital teeth (Spurrier et al., 1990; Mirabella and Artun,

*Corresponding author. E-mail: antoniogeraldooliveira@gmail.com.
Tel/Fax: 55 (35) 3221-5376, (35) 8843-5376.

Table 1. Data on root resorption in published studies addressing the characteristics of the patients and malocclusions.

Author	Overjet	Overbite	Age	Gender	Endo
Santamaria Jr (2009)	NS	NS	NS	-	NS
Consolaro et al. (2009)	NS	NS	NS	-	NS
Ren et al. (2008)	NS	NS	+	NS	NS
Esteves et al. (2007)	NS	NS	NS	NS	-
Mohandesan et al. (2007)	NS	NS	NS	+	NS
Nigul, Jagomagi (2006)	-	-	-	-	NS
Consolaro (2005)	NS	NS	-	-	-
Brin et al. (2003)	+	NS	NS	NS	NS
Consolaro (2002)	NS	NS	NS	NS	-
Sameshima, Sinclair (2001)	+	-	+	-	NS
Mavragani et al. (2000)	NS	NS	+	NS	NS
Taner et al. (1999)	+	NS	NS	NS	NS
Parker, Harris (1998)	-	-	NS	-	NS
Bender et al. (1997)	NS	NS	NS	NS	--
Drysdale et al. (1997)	NS	NS	NS	NS	-
Kurol et al. (1997)	-	-	-	+	NS
Baumrind et al. (1996)	-	-	-	++	NS
Kjaer (1995)	NS	NS	NS	+	NS
Mirabela, Artun (1995)	NS	NS	+	NS	--
Mirabela, Artun (1995)	NS	NS	NS	NS	--
Brezniak, Wasserstein (1993)	NS	NS	+	NS	NS
Linge, Linge (1991)	+	-	-	-	NS
Spurrier et al., 1990	NS	NS	NS	++	--
McFadden et al. (1989)	NS	NS	-	-	NS
Levander, Malmgren (1988)	NS	NS	-	-	NS
Linge, Linge (1983)	-	-	+	-	NS
Phillips (1955)	NS	NS	-	-	NS
Total	+ = 4 - = 5	+ = 0 - = 7	+ = 6 - = 8	+ = 3 - = 11 ++ = 2	- = 4 -- = 4

+ = related with root resorption; - = not related with root resorption; ++ = greater resorption in males; -- = less resorption in endodontically treated teeth; NS = non-specified; endo = endodontic treatment.

1995a, b; Bender et al., 1997). Conversely, other studies did not reveal such differences (Drysdale et al., 1997; Consolaro, 2005; Esteves et al., 2007). The interruption or dissipation of the excessive force is enough to interrupt the periodontal alterations, especially of the cementoblast layer. The endodontic treatment does not significantly alter this situation, even with utilization of calcium hydroxide (Consolaro, 2002). Table 1 presents published studies that correlated the characteristics of patients and malocclusions with the external apical root resorption and the methodology applied.

More important than to relate the type of malocclusion of root resorption after orthodontic treatment is to define the extent of tooth movement and investigate its relationship with apical root resorption. Several studies assume that in comparison with Class I, most Class II individuals

might present greater overjet and consequently greater extent of dental movement due to large retraction of incisors (Linge and Linge, 1991; Brin et al., 2003). It would be relevant however, to compare differences in overjet and overbite concerning external apical root resorption after orthodontic treatment.

In addition to the overjet and overbite, this study analyzed the correlation between the occurrence of root resorption after orthodontic treatment with age, gender and presence or not of endodontic treatment.

MATERIALS AND METHODS

The study was approved by the Institutional Review Board of the Postgraduate Center at São Leopoldo Mandic College (protocol n. 2008/0374). The study sample was obtained after detailed analysis

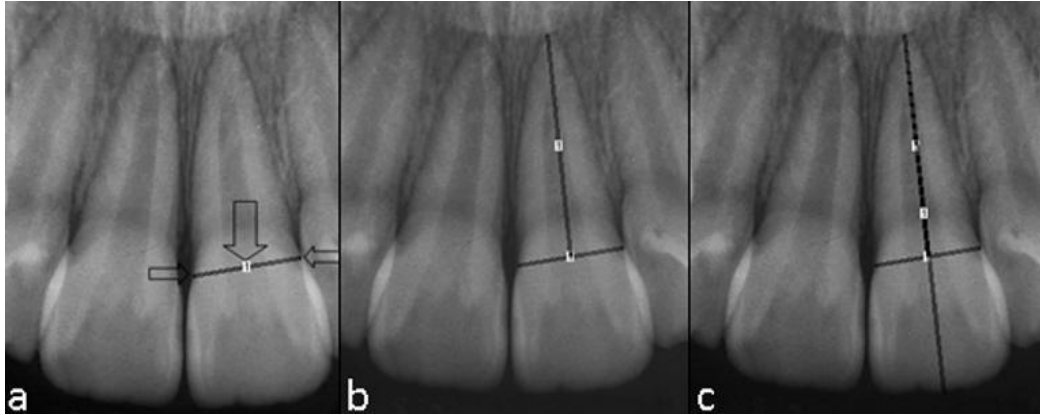


Figure 1. a, CEJ (cemento-enamel junction) line, formed by the union of the mesial and distal CEJ points (small arrows), with the large arrow indicating the median CEJ point that corresponds to the midpoint between the mesial and distal CEJ points; b, Root length measurement, corresponding to the distance from the median CEJ point to the root apex; c, The line indicating the total tooth length (superimposed to the line indicating the root length) runs from the root apex to the incisal edge, passing through the median CEJ point.

of 407 patient records of the Specialization Course in Orthodontics at Lavras Educational Center, Minas Gerais. All patients had been treated with fixed appliances by postgraduate orthodontic students by the same technique adopted by the department (conventional edgewise and pre-adjusted edgewise).

Among the 407 records, 208 were excluded because they did not meet the inclusion criteria, which was, patients voluntarily registering at the Triage Center of the Specialization Course in Orthodontics at Lavras Educational Center and signed an informed consent form agreeing to participate in the study. The exclusion criteria comprised patients who interrupted the treatment or were referred to other professionals; incomplete initial or final orthodontic records; periapical radiographs of poor quality (elongated, shortened or distorted images or not exhibiting part of the central incisors; rotated teeth; inadequately developed radiographs; etc); maxillary central incisors with incompletely formed roots; maxillary central incisors with fracture or restoration on the incisal edge during orthodontic treatment; or any other reasons that did not allow perfect measurement of the maxillary central incisors.

Therefore, the final sample comprised 199 records. The initial and final periapical radiographs of these patients, obtained by the paralleling technique, were digitized (scanner model "Perfection V700", Epson®), summing up to 377 maxillary central incisors that were evaluated and measured.

Measurement technique

The digitized radiographic images were stored and edited using the Photoshop® software (Adobe®, Photoshop® Cs3 version 10.0, USA), maintaining their original dimensions, and analyzed on a microcomputer. Thereafter, the images were analyzed on the "Image j" software (designed by the U.S. National Institutes of Health - Image J 1.41 - public domain- <http://rsb.info.nih.gov/ij/>, downloaded on March 12th 2009) for the achievement of measurements. The root and tooth lengths were measured to the nearest 0.01 mm. In order to determine and calculate the changes in the tooth and root length on two different radiographs of the same patient, the study considered the premise that the crown size is not changed during orthodontic treatment (except in case of fracture or restoration). Therefore, the variation between the initial (C1) and final crown length (C2) determined the magnification

factor. If no change occurred in root length during treatment, the variation between the initial (R1) and final root length (R2) should be equal to the C1/C2 variation. If root shortening occurred during treatment, the amount of apical root resorption was calculated by the equation: $R1 - R2 \times (C1/C2)$ (Brezniak et al., 2004).

The software "Image J" was used for tooth length measurement, using a standard scale for all images analyzed. This procedure comprised measurement of the mesiodistal diameter of the crown of a maxillary central incisor on the initial dental cast of one patient in the sample, whose value was 8.5 mm in diameter. Thereafter, the digitized periapical radiograph of the same tooth was opened in the software "Image J" for measurement of the mesiodistal diameter using the tool "Straight line", followed by the steps "Analyze", "Set Scale", "Distance in Pixels" (107.000), "Known Distance" (8.5 mm), "Pixel Aspect Ratio" (1.0), "Unit of Length" (mm), and "Global". This revealed a final standard scale of 12.588 "Pixels/mm", which was employed for measurement of all images in this study. After achievement of the standard scale, the digitized radiographs of all patients were opened on the software and measured using the tools "Plugins", "Analyze", "Measure and Label". The values were entered on an Excel® worksheet to calculate the root shortening (Microsoft Office Excel version 97-2003®).

For the measurement of each radiographic image, the median cemento-enamel junction (CEJ) point was taken as reference, which corresponds to the midpoint between the mesial and distal points of the CEJ line. The root length was measured as the distance between the median CEJ point and the root apex. After achievement of the root length, the total tooth length was measured (between the root apex and the incisal edge) and the crown length was calculated as the difference between the total length and the root length, which represents the distance between the median CEJ point and the incisal edge (Figure 1).

Sample classification

The 377 maxillary central incisors were divided in groups according to the study objective, namely the overjet, as follows: G1- increased overjet (n = 146); G2- decreased overjet (n = 231); overbite: G3- increased overbite (n = 137); G4- decreased overbite (n = 209) and G5- negative overbite (n = 23); age range: G6- children (n = 9), G7- adolescents (n = 317) and G8- adults (n = 51); gender: G9- males

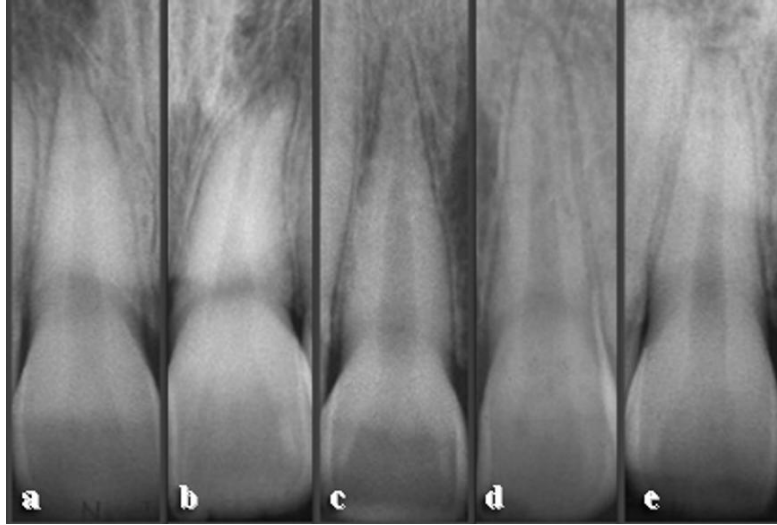


Figure 2. Sample classification according to apical morphology: (a) Pipette-shaped; (b) dilacerated; (c) pointed; (d) rounded; (e) rectangular.

Table 2. Calculation of method error intraexaminer. Difference between first and second mensuration (millimeters), casual error (Dahlberg) and systematic error ("t" test).

Length (mm)	Measures				Error		Significance
	1st		2nd		Casual (Dahlberg)	Systematic (P)	
	SD	SD	SD	SD			
Root	16.1	2.26	16.19	2.21	0.195	0.054	ns
Crown	8.67	0.68	8.62	0.66	0.179	0.314	ns

ns = Not significant; = average; SD = standard deviation.

(n = 167) and G10– females (n = 210); and finally endodontic treatment: G11– endodontically treated teeth (n = 8) and G12– vital teeth (n = 369). Among the total sample of 199 patients evaluated, it was not possible to collect some data from the patient records, such as overbite of four patients (8 teeth), leading to a final "n" of 369 for this topic.

Statistical analyses

Data were described as means and standard deviations. The Kolmogorov-Smirnov test was applied to check if the data presented normal distribution. Comparison between two groups was performed by the Student t test. Comparison between three or more groups was performed by one-way analysis of variance (ANOVA). If statistically significant difference was observed, the Tukey test for multiple comparisons was applied. All statistical tests were applied at a significance level of 5% ($p < 0.05$) and were run using the statistics software Past (Hammer et al., 2001).

Method error

The apical morphology was evaluated in the sample in order to verify if teeth with abnormal apical shapes might have an influence on the outcomes. Therefore, in addition to the division of teeth according to the aforementioned groups, all images of root apices

were classified according to the morphology. All radiographs were analyzed by a single examiner. To analyze the visual accuracy of the examiner when scoring the apical morphology, images of 50 randomly selected periapical radiographs of maxillary incisors were analyzed, adding up to 100 teeth, which were classified in five different apical morphologies: pipette-shaped, dilacerated, triangular, rounded and rectangular (Figure 2). After 30 days, the 100 teeth were once again evaluated and classified for calculation of the Kappa index in the intraexaminer evaluation, which revealed a value of 0.76, evidencing substantial agreement.

In order to determine the reliability of results, the method error was evaluated by analysis of casual and systematic errors. Images of 16 periapical radiographs were randomly selected, from which 32 measurements were obtained (of the two maxillary central incisors) in two different periods at a four-week interval. The error was calculated by the Dahlberg formula, revealing values of 0.195 and 0.179 for the casual error and 0.054 and 0.314 for the systematic error, the root and crown lengths, respectively. Analysis of the method error revealed that the identification of points and the achievement of measurements were reliable, since the accuracy of measurements was within acceptable parameters (Table 2).

RESULTS

The analysis of treatment of orthodontic patients presenting

Table 3. Relationship between root shortening after orthodontic treatment according to the overjet (in millimeters) and comparison between increased overjet (> 4 mm) and decreased overjet (\leq 3.5 mm).

Overjet	Groups	Patients (N)	Teeth (N)	SD	P value		
Increased	G1	78	146	1.48	1.29	G2	0.924
Decreased	G2	121	231	1.49	1.36		

= mean; SD = standard deviation.

Table 4. Relationship between root shortening after orthodontic treatment according to the overbite (in millimeters) and comparison between increased overbite (> 4 mm), decreased overbite (\leq 3.5 mm), and negative overbite (anterior open bite).

Overbite	Groups	Patients (N)	Teeth (N)	SD	P value		
Increased	G3	73	137	1.42	1.35	G4	0.460
Decreased	G4	110	209	1.52	1.31	G5	0.365
Negative	G5	12	23	1.70	1.59		

= mean; SD = standard deviation. Among the total sample of 199 patients evaluated, it was not possible to collect some data from four patient records (8 teeth), leading to a final "N" of 195 patients and 369 teeth for this topic. ANOVA P = 0.5772.

Table 5. Relationship between root shortening after orthodontic treatment according to the age (in millimeters) and comparison between children (< 10 years), adolescents (between 10 and 20 years) and adults (above 20 years).

Age range	Groups	Patients (N)	Teeth (N)	SD	P value		
Children	G6	5	9	0.57	0.67	G7	0.059
Adolescents	G7	168	317	1.41	1.31	G8	0.0017**
Adults	G8	26	51	2.12	1.38		0.00036***

= mean; SD = standard deviation; ** P < 0.01; *** P < 0.001.

Table 6. Relationship between root shortening after orthodontic treatment according to male and female genders (in millimeters).

Gender	Groups	Patients (N)	Teeth (N)	SD	P value	
Male	G9	88	167	1.65	1.44	
Female	G10	111	210	1.36	1.22	.034*

= mean; SD = standard deviation; *P < 0.05.

presenting increased overjet and overbite at treatment onset is presented in Tables 3 and 4, which reveal that there was no correlation between the increased overjet and overbite and the occurrence of root resorption (0.924). Moreover, there was also no correlation in the group of patients with anterior open bite (negative overbite) (0.5772).

Concerning the relationship between age and apical root resorption, it was observed that when orthodontic treatment was performed at younger ages, especially in children below ten years of age, there was statistically smaller occurrence of root resorption when compared to adults (P = 0.0017) and was also smaller in adolescents when compared to adults (P = 0.00036) (Table 5). With

regard to the variable gender, there was statistically significant greater occurrence of root resorption among males when compared to females (P = 0.034) (Table 6). The assumption that endodontically treated teeth would be less susceptible to root resorption was not confirmed in the present study, since there was no significant difference between groups (P = 0.208) (Table 7).

DISCUSSION

There was no correlation between the increased overjet and overbite and the occurrence of root resorption. Similarly, Nigul and Jagomagi (2006) did not find

Table 7. Relationship between root shortening after orthodontic treatment according to the accomplishment of endodontic treatment (in millimeters) and comparison between vital and endodontically treated teeth.

Endodontic treatment	Group	Patient (n)	Tooth (n)	SD	P value
Yes	G11	6	8	0.89	0.83
No	G12	196	369	1.50	1.34

= mean; SD = standard deviation. Three patients had only one endodontically treated central incisor and therefore were included in the two groups.

differences in the occurrence of root resorption between patients with increased or reduced overjet and overbite. However, the results reported by Brin et al. (2003) and Taner et al. (1999) correlated the occurrence of root resorption after treatment between patients with Class I and Class II division 1 malocclusion.

According to several investigators (Linge and Linge, 1983; Brezniak and Wasserstein, 1993; Mirabella and Artun, 1995a; Mavragani et al., 2000; Sameshima and Sinclair, 2001; Ren et al., 2008), the factor age is directly related to the greater occurrence of root resorption after orthodontic treatment, because adult patients are more susceptible to root resorption. However, other studies (Phillips, 1955; McFadden et al., 1989; Baumrind et al., 1996; Nigul and Jagomagi, 2006) did not find a higher frequency of root resorption in adults.

The greater occurrence of root resorption among males in relation to females, may be explained by the fact that the group of male patients exhibited a higher number of maxillary central incisors with pipette-shaped and dilacerated apical morphologies (18 teeth) when compared to the females, which presented only eight teeth with such apical morphologies. Even though some studies still report a greater tendency to apical root resorption after orthodontic treatment among the females (Kjaer, 1995; Kurol et al., 1997; Mohandesan et al., 2007), this statement should be revised based on the current knowledge. Despite the controversial reports, most studies indicate the lack of gender dimorphism in this aspect (Linge and Linge, 1983; Levander and Malmgren, 1988; Linge and Linge, 1991; Baumrind et al., 1996; Parker and Harris, 1998; Sameshima and Sinclair, 2001; Nigul and Jagomagi, 2006; Santamaria, 2009).

Some investigators agree with this reduced susceptibility of endodontically treated teeth to root resorption after orthodontic treatment (Spurrier et al., 1990; Mirabela and Artun, 1995a, b; Bender et al., 1997) despite some discordant reports (Drysdale et al., 1997; Consolaro, 2002; 2005; Esteves et al., 2007). Based on the present results and considering the inherent limitations of any methodology, it was concluded that the increased overjet and overbite (greater than 4 mm) did not increase the occurrence of root resorption; children (below ten years of age) presented smaller occurrence of root resorption, while adults (older than 20 years) demonstrated greater occurrence of root resorption after orthodontic treatment;

there was greater occurrence of root resorption among males, yet this was simultaneously related to the higher number of teeth with pipette-shape and dilacerated apical morphology in this gender; also, there was no difference in the occurrence of root resorption between vital and endodontically treated teeth. The susceptibility or individual predisposition to tooth resorptions during orthodontic treatment may be related to the apical morphology.

REFERENCES

- Baumrind S, Korn EL, Boyd RL (1996). Apical root resorption in orthodontically treated adults. *Am. J. Orthod. Dentofac. Orthop.*, 110: 311-20.
- Beck BW, Harris EF (1994). Apical root resorption in orthodontically treated subjects: analysis of edgewise and light wire mechanics. *Am. J. Orthod. Dentofacial Orthop.*, 105: 350-361.
- Bender IB, Byers MR, Mori K (1997). Periapical replacement resorption of permanent, vital, endodontically treated incisors after orthodontic movement: report of two cases. *J. Endod.*, 2: 768-73.
- Brezniak N, Wasserstein A (1993). Root resorption after orthodontic treatment: part 2. literature review. *Am. J. Orthod. Dentofac. Orthop.*, 103: 138-46.
- Brezniak N, Goren S, Zoizner R, Dinbar A, Arad A, Wasserstein A, Et Al (2004). A comparison of three methods to accurately measure root length. *Angle Orthod.*, 74: 86-91.
- Brin I, Tulloch JF, Koroluk L, Philips C (2003). External apical root resorption in Class II malocclusion: a retrospective review of 1- versus 2 - phase treatment. *Am. J. Orthod. Dentofac. Orthop.*, 124: 151-56.
- Consolaro A (2002). A endodontia resolve as reabsorções ortodônticas? *Rev. Clin. Ortop. Dental Press.*, 1: 100.
- Consolaro A (2005). Reabsorções dentárias nas especialidades clínicas. 2a ed. Maringá: Dental Press., 615p.
- Consolaro A, Santamaria Jr M, Consolaro MFM-O, Fracalossi ACC (2009). As mulheres não apresentam maior probabilidade de reabsorções radiculares no tratamento ortodôntico. *Rev. Clin. Ortop. Dental Press.*, 8: 107-109.
- Drysdale C, Gibbs SL, Pitt Ford TR (1997). Controle ortodôntico de dentes tratados endodônticamente. *R Dental Press Orthodon. Orthop. Facial.*, 2: 62-3.
- Esteves T, Ramos AL, Pereira CM, Hidalgo MM (2007). Orthodontic root resorption of endodontically treated teeth. *J. Endod.*, 33: 119-122.
- Hammer Ø, Harper DAT, Ryan PD (2001). PAST: Paleontological Statistics Software Package for Education and Data Analysis. *Palaeontologia Electronica*, 4: 9. http://palaeo-electronica.org/2001_1/past/issue1_01.htm.
- Kjaer I (1995). Morphological characteristics of dentitions developing excessive root resorption during orthodontic treatment. *Eur. J. Orthod.*, 16: 25-34.
- Kurol J, Owman-Moll P, Lundgren D (1997). Reabsorção radicular apical em adultos tratados ortodônticamente. *R. Dental Press Orthodon. Orthop. Facial.*, 2: 46-7.
- Levander E, Malmgren O (1988). Evaluation of the risk of root resorption during orthodontic treatment: a study of upper incisors. *Eur.*

- J. Orthodon., 10: 30-8.
- Linge BO, Linge L (1983). Apical root resorption in upper anterior teeth. Eur. J. Orthodon., 5: 173-83.
- Linge L, Linge BO (1991). Patient characteristics and treatment variables associated with apical root resorption during orthodontic treatment. Am. J. Orthod. Dentofac. Orthop., 99: 35-43.
- Mavragani M, Vergari A, Selliseth NJ, Boe OE, Wisth PJ (2000). A radiographic comparison of apical root resorption after orthodontic treatment with a standard edgewise and a straight wire edgewise technique. Eur. J. Orthod., 22: 665-74.
- McFadden WM, Engstrom C, Engstrom H, Anholm JM (1989). A study of the relationship between incisor intrusion and root shortening. Am. J. Orthod. Dentofac. Orthop., 96: 390-96.
- Mirabella AD, Artun J (1995a). Risk factors for apical root resorption of maxillary anterior teeth in adult orthodontic patients. Am. J. Orthod. Dentofac. Orthop., 108: 48-55.
- Mirabella AD, Artun J (1995b). Prevalence and severity of apical root resorption of maxillary anterior teeth in adult orthodontic patients. Eur. J. Orthod., 17: 93-99.
- Mohandesan H, Ravanmehr H, Valaeil N (2007). A radiographic analysis of external apical root resorption of maxillary incisors during active orthodontic treatment. Eur. J. Orthod., 29: 134-39.
- Nigul K, Jagomagi T (2006). Factors related to apical root resorption of maxillary incisors in orthodontic patients. Stomatologija., 8: 76-9.
- Parker RJ, Harris EF (1998). Directions of orthodontic tooth movements associated with external apical root resorption of the maxillary central incisor. Am. J. Orthod. Dentofac. Orthop., 114: 677-83.
- Phillips JR (1955). Apical root resorption under orthodontic therapy. Angle Orthod., 25: 1-22.
- Ren Y, Maltha JC, Liem RSB, Stokroos I, Kuijpers-Jagtman AM (2008). Age-dependent external root resorption during tooth movement in rats. Acta Odont. Scand., 66: 93-8.
- Sameshima GT, Sinclair PM (2001). Predicting and preventing root resorption: Part I. diagnostic factors. Am. J. Orthod. Dentofac. Orthop., 119: 505-10.
- Santamaria Jr M (2009). Biologia da movimentação dentária induzida e das reabsorções radiculares associadas – influência do gênero e dos bifosfonatos [tese]. Bauru: Faculdade de Odontologia de Bauru, Universidade de São Paulo.
- Spurrier SW, Hall SH, Joondeph DR, Shapiro PA, Riedel RA (1990). A comparison of apical root resorption during orthodontic treatment in endodontically treated and vital teeth. Am. J. Orthod. Dentofac. Orthop., 97: 130-34.
- Taner T, Ciger S, Sencift Y (1999). Evolution of apical root resorption following extraction therapy in subjects with class I and class II malocclusions. Eur. J. Orthod., 21: 491-496.