

Full Length Research Paper

Effects of carotenoid on the spleen of adult wistar rats following low and high administration

Ovigwe S. Micheal*, Ovedge D. A. and Ejike O. Felix

Department of Anatomy, College of Health Sciences, Nnamdi Azikiwe University, Nnewi Campus, Anambra State, Nigeria.

Accepted 22 July, 2015

Carotenoids are hypothesized to play a preventive role in a variety of diseases; however, little is known about their biodistribution and metabolism in humans and tissue specific bioactivity. This study is aimed at investigating the effects of carotenoid on the spleen of adult wistar rats following low and high administration. Twenty healthy wistar rats weighing between 150-210 kg were used. They were designated as groups A, B, C and D. Group A served as the control and received 0.35 ml of distilled water; the experimental groups B, C and D received 0.4 ml, 0.5 ml and 0.6 ml of carotenoid respectively for twenty-one days. Twenty four hours after the last administration, the animals were weighed, anaesthetized under the influence of chloroform vapour and dissected. Spleen tissues were removed, weighed and trimmed down to a size of 3 mm × 3 mm and fixed in 10% formaldehyde for histological studies. There was significant weight gain of experimental groups related to the control. The relative spleen weight of the experimental groups was statistically similar with that of the control. Histological finding showed that there was no destruction of the cytoarchitecture of the spleen tissues. These findings suggest that low and high consumption of carotenoid may not put the spleen at risk of adverse histopathological conditions.

Key words: Spleen weight, body weight, carotenoid, antioxidant, hepatoprotective.

INTRODUCTION

Carotenoids are naturally occurring, fat soluble pigments that give many whole, natural foods their distinct yellow and orange colors (Fielding et al., 2003). The best studied and famous of the carotenoid is beta-carotene, but hundreds of carotenoids have been identified by scientists and many are also important to our health. Some of the other well researched carotenoids include alpha-carotene, lycopene, lutein, zeaxanthin, beta-cryptoxanthin and canthaxanthin (Institute of Medicine, Food and Nutrition Board, 2000: 325-400).

The results of some but not all observational studies suggest that a diet high in these carotenoids can reduce the risk of developing various illnesses, including cardiovascular disease, age related vision loss, and

various types of cancer (Cooper et al., 1999; Epstein, 2003; Hak et al., 2003). These findings led to large scale studies of synthetic beta-carotene for preventing cancer, heart disease, cataracts, strokes and macular degeneration (Cooper et al., 1999; Epstein, 2003; Hak et al., 2003; Albanes et al., 1995; Lee et al., 1999; Fielding et al., 2000).

In plants, carotenoids have the important antioxidant function of quenching (deactivating) singlet oxygen, an oxidant formed during photosynthesis (Halliwell and Gutteridge, 1999). Test tube studies indicate that lycopene is one of the most effective quenchers of singlet oxygen among carotenoids (Mascio et al., 1989). Although important for plants, the relevance of singlet oxygen quenching to human health is less clear. Test tube studies indicated that carotenoids can also inhibit the oxidation of fats under certain conditions but their actions in humans appear to be more complex (Young and Lowe, 2001).

*Corresponding author. E-mail: ovigwe.mich@yahoo.com.

Table 1. Comparison of mean initial body weight, final body weight and weight changes in all groups (A, B, C and D) (Mean \pm SEM was given for each measurement).

Variable	GP. A	GP. B	GP. C	GP. D	F-RATIO	PROB OF SIG
Initial body weight	190.10 \pm 3.60	192.80 \pm 4.60	195.60 \pm 6.60	198.40 \pm 7.20	64.230	<0.001
Final body weight	200.40 \pm 5.50	209.30 \pm 2.70	212.30 \pm 4.20	215.20 \pm 2.50	40.240	<0.001
Weight change	10.10 \pm 2.20	17.10 \pm 6.20	17.70 \pm 6.20	17.60 \pm 6.50	7.280	<0.001

The final body weight for the experimental groups B, C and D increased significantly ($P < 0.001$) relative to the control A.

Carotenoids have many physiological functions. Given their structure, carotenoids are efficient free radical scavengers and they enhance the vertebrate immune system. There are several dozens of carotenoids in foods people consume and most of these carotenoids have antioxidant activity (Palva and Russell 2008).

Epidemiological studies have shown that people with high beta carotene intake and high plasma levels of Beta-carotene have a significantly reduced risk of lung cancer. However, studies of supplementation with large doses of beta carotene in smokers have shown an increase in cancer risk possibly because Beta-carotene under intense oxidative stress, for example, induced by heavy smoking, allow the breakdown of products that reduce plasma Vitamin A and worsen the lung cell proliferation induced by smoke (Alija et al., 2004).

More than 900 drugs, toxins and herbs have been reported to cause liver and kidney diseases. The kidney being the primary organ of drug and xenobiotics excretion is therefore liable to damage. This scenario provides a necessity to carry out research on the effects of carotenoids on the kidney of wistar rats. Therefore there is need to investigate the effects of carotenoids on the spleen of adult wistar rats.

MATERIALS AND METHODS

Breeding of animals

Twenty wistar rats weighing between 150-210 kg were procured from the animal house of Anatomy Department, University of Calabar, Cross River State, Nigeria. They were allowed to acclimatize under normal temperature (27 - 30°C). They were fed *ad libitum* with water and guinea feed pallets from Agro Feed Mill Nigeria Limited.

Drug preparation

Commercial carotenoid was procured from Golden Neo-life Diamite (GNLD) Int. Spartan by pharmaceutical Contractors Isando Road, Isando, South Africa and purchased from No. 6 Itu Road Uyo retail outlet, Akwa Ibom State, Nigeria. One capsule of carotenoid containing 900 mg was dissolved in 10 ml of distilled water and administered to the animals.

Experimental protocols

The twenty adult wistar rats weighing between 150-

210kg were assigned into four groups of five animals each. Group A served as the control and received 0.35 ml of distilled water; the experiment groups B, C and D received 0.4 ml, 0.5 ml and 0.6 ml of carotenoid respectively for a period of twenty-one days. Twenty four hours after the last administration, the animals were sacrificed using chloroform inhalation method. Spleen tissues were removed, weighed and trimmed down to a size of 3 mm x 3 mm thickness and fixed in zenkers fluid for four hours for historical studies.

Tissues processing

For easy study of sections under microscope, the tissues passed through several processes of fixation, dehydration, clearing, infiltration, embedding, sectioning and staining. Fixation was carried out in 10% formaldehyde. The tissues remained in the fluid for four hours. After fixation, the tissues were washed overnight under a stream tap water. Dehydration of the fixed tissues was carried out in different percentages of alcohol 50%, 90% absolute. After dehydration, tissues were cleared in xylene for two hours after which infiltration was done in molten paraffin wax at a temperature of 60°C for two hours each in two changes and then sectioned. Haematoxyline and eosine method was used.

RESULTS

Morphometric analysis of body weight

The body weight of the wistar rats were analyzed in Table 1 and Figure 1. Table 1 shows a comparison of the mean initial body weight, final body weight and weight changes in all the groups, while Figure 1 shows the bar chart representation of the mean initial body weight and final body weight.

Morphometric analysis of organ (spleen) weight

The organ weight of the wistar rats were analyzed in Table 2 and Figure 2. Table 2 shows a comparison of the mean relative organ [spleen] of all the groups, while Figure 2 shows the bar chart representation of the relative spleen weight of the various groups.

Histopathological findings

The histological structure of the spleen of the wistar rats

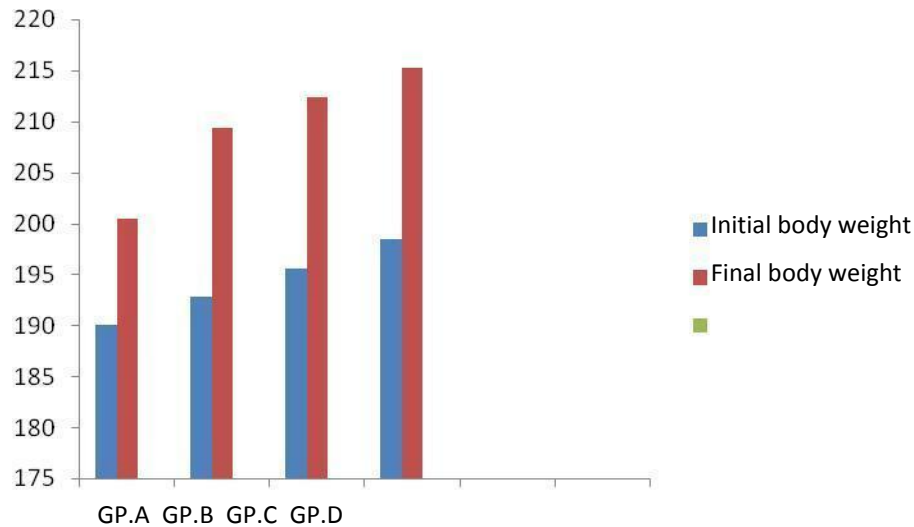


Figure 1. The bar chart representation of the mean initial and final body weight.

Table 2. Comparison of mean relative organ [spleen] of all the groups (A, B, C and D) (Mean \pm SEM was given for each measurement).

Variable	GP. A	GP. B	GP. C	GP. D	F-RATIO	PROB OF SIG
Spleen weight	4.30	4.34	4.37	4.39	4	

The relative spleen weight for the experimental groups increased significantly ($P < 0.001$) relative to the control.



Figure 2. The bar chart representation of the relative spleen weight of the various groups.

with their different treatments in the four groups was shown in Micrographs 1 to 4.

DISCUSSION

Carotenoids are a type of photonutrient whose

consumption has been associated with reduced risk of cancers, cataracts and age-related macular degeneration (Halliwell and Gutteridge, 1999).

Studies conducted by the United States Department of Agriculture Scientists showed that a carotenoid deficient diet compromises immune power and that the broad

spectrum of carotenoid in carotenoid complex could enhance the immune response of otherwise healthy people. The studies showed that carotenoid complex dramatically enhanced both immune cell level and overall immune cell responsiveness (Mascio et al., 1989). A study conducted by researchers from the USDA and University of California showed that carotenoid complex protected bad cholesterol from oxidation (Young and Lowe, 2001).

In the study where healthy women were fed with a low carotenoid diet for 100 days, and in the remaining 20 days of the study, this diet was supplemented daily with three capsules of carotenoid. The carotenoid content of the LDL rose dramatically. The result indicated that increased carotene consumption may have a protective effect against oxidative stress *in vivo*, suggesting that a low carotene intake may increase the oxidative susceptibility of body lipids (Young and Lowe, 2001).

Another study conducted by USDA demonstrated that carotenoid complex, a whole food dietary supplement made from fruits and vegetables protected cells from oxidation (U.S National Library of Medicine, 2008; Alija et al., 2004).

There is ability to function as antioxidant has been known for many years. They are not just "another group of natural pigments", they are substances with very special and remarkable properties that no other group of substances possesses and that form the basics of their many varied functions and actions in all kinds of living organisms. The conjugated double bond structure is primarily responsible for the ability of beta carotenoid to quench singlet oxygen physically without degradation, and for the chemical reactivity of Beta carotene with free radicals such as the peroxy, hydroxyl, and superoxide radicals.

Carotenoids have been shown to be able to prevent or decrease oxidation damage to DNA, lipid and proteins (Palozza and Krinsky, 1992; Krinsky, 1993). Oxidative stress and free radical attack on biological structure are believed to be the major factors in the initiation and propagation of the development of many degenerative diseases. In general, carotenoids behave as effective antioxidants *in vitro* (Ziegler et al., 1993; Peto et al., 1981) and clear evidence exists from a majority of epidemiological studies on the incidence of CVD indicating an inverse relationship with dietary carotenoids (Volumeters et al., 2006) and circulating carotenoid levels. Carotenoids may function as chain breaking antioxidant reducing lipid peroxidation of such vulnerable membrane. The antioxidant properties of carotenoids are primarily associated with their ability to quench singlet oxygen (Conn et al., 1991) and scavengers of free radicals (Burton and Ingold, 1984; Mortensen and Skibsted, 1996).

In the present study, there was significant weight gain of the experimental animals compared with the control. The relative organ [spleen] weight of the experimental

groups was statistically similar with the control, and histological findings showed no distortion of the cytoarchitecture of the spleen. These findings suggest and agree with previous researches that carotenoids act as a source of nutrition and possess antioxidant and hepatoprotective properties.

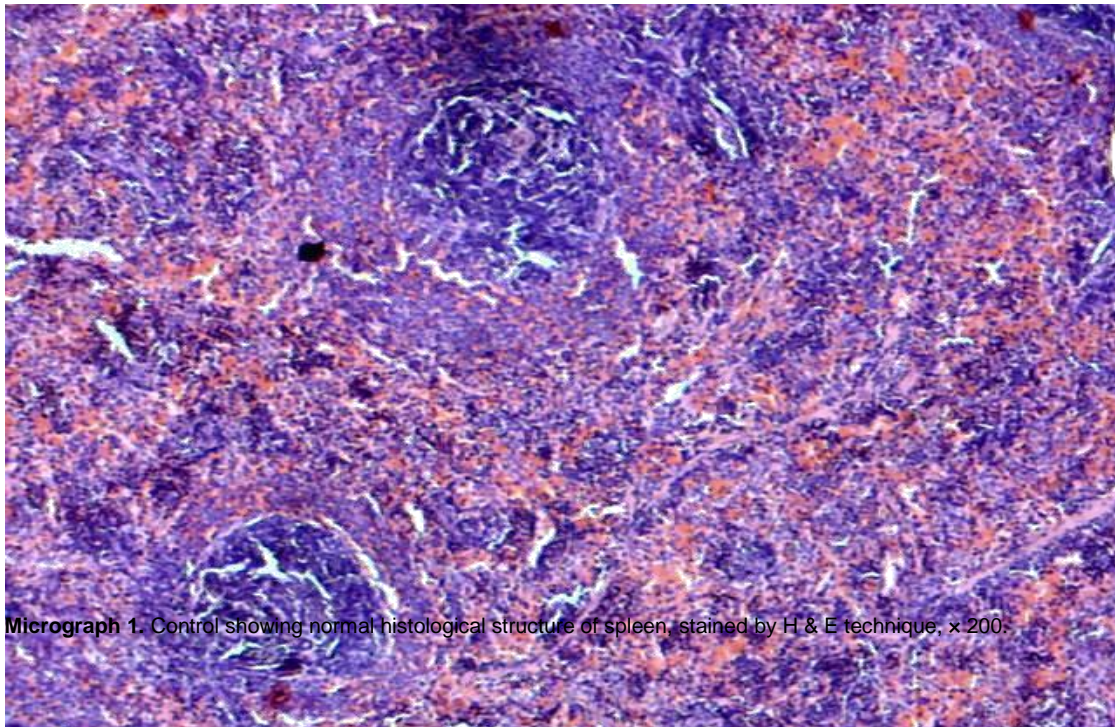
Conclusion

From the present study, it can be concluded that carotenoid intake in low and high doses may not put the spleen at risks of adverse histopathological conditions.

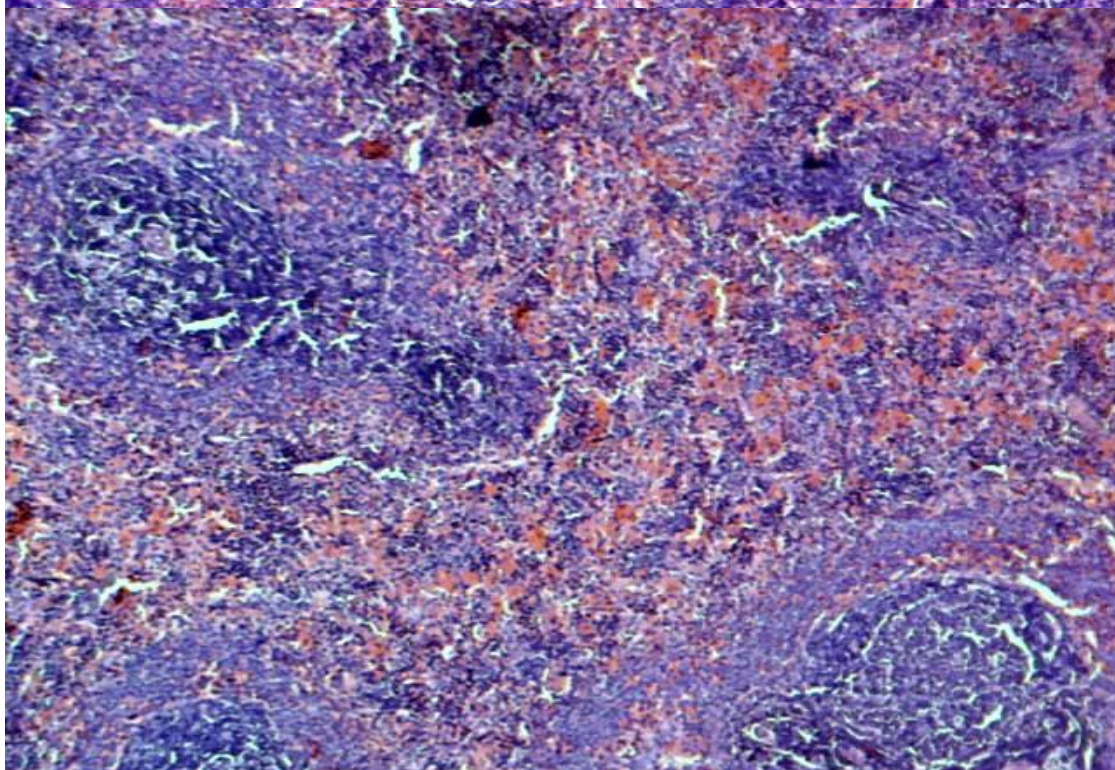
REFERENCES

- Albanes D, Heinonen OP, Huttunen JK et al (1995). Effects of alpha-tocopherol and beta-carotene supplements on cancer incidence in the Alpha-Tocopherol Beta-carotene cancer prevention study. *Am. J. Clin. Nutr.*, 62(6):14275-14305.
- Alija AJ, bresgen N, Sommerbury O, Siems W, Ecki PM (2004). Cytotoxic and products an primary rat hepatocytes. *Carcinogenesis*, 25 (5): 827-31.
- Burton GW, Ingold KU (1984). An unusual type of lipid antioxidant. *Science* 224:1569-73,.
- Conn pf, schalch w, Trescot TG (1991). The singlet oxygen and beta carotene interaction. *Photobiol*, 111:41-47.
- Cooper DA, Eldridge AL, Peters JC (1999). Dietary carotenoids and certain cancers, heart disease, and age related macular degeneration. A review of recent research. *Nutria Rev.* 57:201-14.
- Epstern KR (2003). The role of carotenoids on the risk of lung cancer. *Semin. Oncol.*, 30:86-93.
- Fielding JM, Sinclair AJ, DiGregorio G, Joveski M, Stockman R (2003). Relationship between color and aroma of olive oil and nutritional content. *Asia Pac. J. Clin. Nutri.*, 12.p 23
- Fielding UM, Schaumberg DA, kupper TS et al (2000). A randomized 12years primary prevention triat of beta carotene supplementation for nonmelanoma skin cancer in the physicians Health study. *Arch Dermatol* 36:179-184.
- Hak AE, Stampfer MJ Camprs H, et al (2003). Plasma carotenoids and tocopherols and risk of myocardial infection in a low-risk population of US male physicians of US male physicians. *Circulation* 108-802-7.
- Halliwell B, Gutteridge JMC (1999). *Free Radicals in Biology and Medicine*. Third ed. New York, NY: Oxford University Press,.
- Institute of Medicine, Food and Nutrition Board Beta-Carotene and other carotenoids. Dietary reference intakes for vitamin C, vitamin E, selenium, and carotenoids. Washington DC. National Academy Press, 2000:325-400.
- Krinsky NI (1993). Actions of Carotenoids in biological systems. *Ann Rev. Nutri* , 13. 561-588.

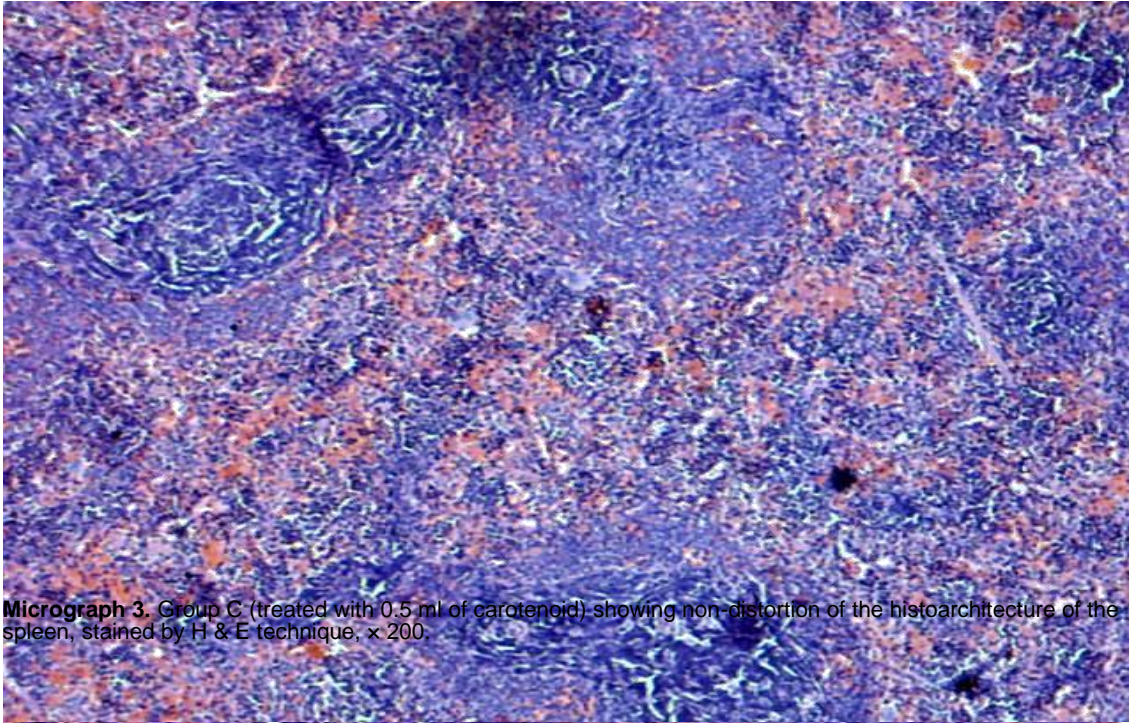
- Lee IM, Cook NR, Manson JE et al (1999). Beta carotene supplementation and incidence of cancer and cardiovascular disease; the women's health study. *J. Natl. Cancer Inst.*, 91:2102-2106.
- Mascio DI, P, Karsner S, Sies H, (1989). Lycopene as the most efficient biological carotenoid singlet oxygen quencher. *Arch Biochem biophys.*, 4 (2): 532-538.
- Mortensen A, Skibsted LH (1996). Kinetics of parallel electron transfer from beta carotene to phenoxyl radical and adduct formation between phenoxyl radical and beta carotens. *Free Res.*, S 25, 515-523.
- Palozza P, Krinsky NI (1992). Antioxidant effects of carotenoids invitro and invitro and invivo: An overview methods *Enzymol*, 213, 403-420.
- Palva SA, Russell RM (2008). B-Carotene and other carotenoids as antioxidants from U.S National library of Medicine November.
- Peto R, Doll R, Buckley JD, Sporn MB, (1981). Can dietary beta carotene materially reduce human cancer rates. *Nature*, 290, 201.
- Volumeters S, Nature T, Mersu J, Rissamen TH (2006). Carotenoid and cardiovascular Health. *J. Clin. Nutr.*, 83, 1265.
- Young AJ, Lowe GM (2001). Antioxidant and Proxidant properties of carotenoids *Arch. Biochem. Biophys.*, 385(1): 20-27.
- Ziegler RG, Mayne ST, Swanson CA (1993). Nutrition and lung cancer causes control, 7: 157-177.



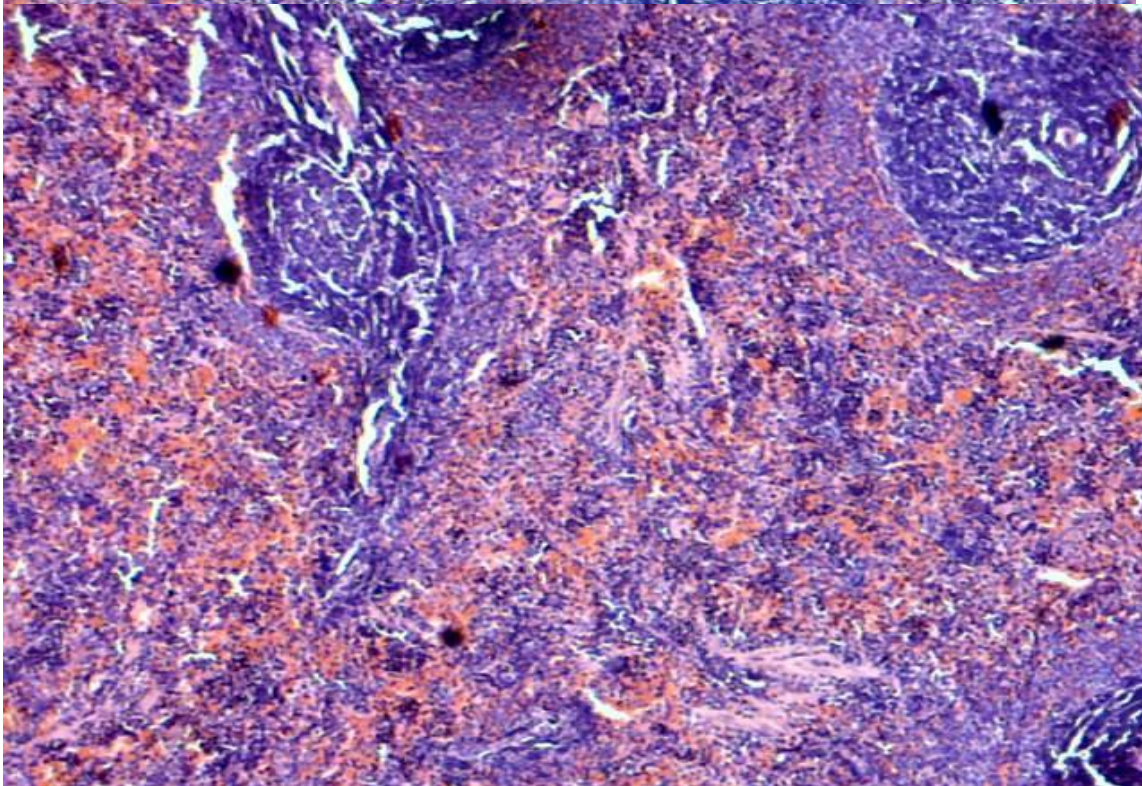
Micrograph 1. Control showing normal histological structure of spleen, stained by H & E technique, x 200.



Micrograph 2. Group B (treated with 0.4 ml of carotenoid) showing normal histoarchitecture of the spleen, stained by H & E technique, x 200.



Micrograph 3. Group C (treated with 0.5 ml of carotenoid) showing non-distortion of the histoarchitecture of the spleen, stained by H & E technique, $\times 200$.



Micrograph 4. Group D (treated with 0.6 ml of carotenoid) showing normal histological structure of the spleen, stained by H & E technique, $\times 200$.