

## Case Report

# Non articular synovial sarcoma of the back, a hairy nevus: An uncommon association!

Arcot Rekha\* and Ravi Annamalai

Sri Ramachandra Medical College and Research Institute, Sri Ramachandra University, India.

Accepted 19 May, 2020

**Giant hairy nevus is an uncommon malformation often associated with cutaneous malignancies. Synovial sarcomas are soft tissue sarcomas that occur in the lower limb. We present our case of synovial sarcoma of the posterior trunk, its association with a hairy nevus and review literature.**

**Key words:** Synovial sarcoma, back, chromosomal translocation, hairy nevus.

## INTRODUCTION

Synovial sarcoma (SS) is an uncommon soft tissue sarcoma (accounts for 5 to 8% of all sarcomas) that occurs in young adults. 50% of SS occur in the lower limb, the head and neck is involved in 10% of cases, the thoracic and abdominal wall in less than 10% and intra thoracic sites in a few cases often in non-articular locations. Giant congenital hairy nevus is associated with skin cancers and neuro-cutaneous melanosis. There is no previous report of these two lesions co existing.

## CASE REPORT

A 40 year old male presented with complaints of a swelling in the back, dull aching pain and mild restriction of flexion (all for 6 months duration). On examination there was a large mass (28 x 18 x 6 cm) extending from the right infra scapular area to the iliac crest posteriorly, with extension into the right flank. There were distended veins and the overlying skin was stretched and shiny (Figure 1). It was firm with areas of softening at the summit of the swelling. The plane of the swelling was superficial to the muscle. There was no spine involvement and there was no neurological deficit. The patient also had a large hairy cell nevus occupying the entire left anterior chest wall, extending on to the neck (Figure 2). The hair over the nevus was fine compared

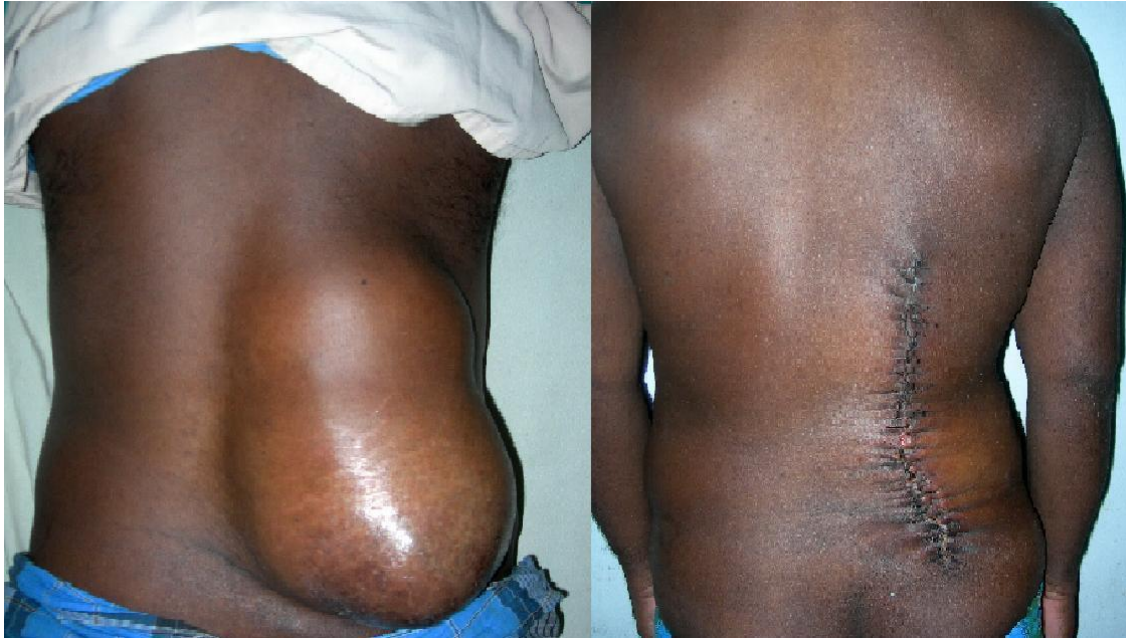with the curly stiff hair over the pectoral region.

The MRI scan (Figure 3) showed a well defined lesion, superficial to the muscle with varying areas of attenuation and large areas of hemorrhage and cystic change. Fine needle aspiration cytology was attempted twice and was hemorrhagic and non diagnostic. Wide excision was done for the soft tissue sarcoma (Figure 1). Histopathology showed morphologically two distinct populations of cells with a characteristic biphasic pattern. Plump round cells with spindle shaped fibroblasts alternating with glandular like areas lined with synovial like cells with mucin were seen. CD 99, keratin and EMA (epithelial membrane antigen) were positive. A diagnosis of synovial sarcoma was made. However, the resected margins were positive and patient was referred for radio therapy. He was lost to follow up.

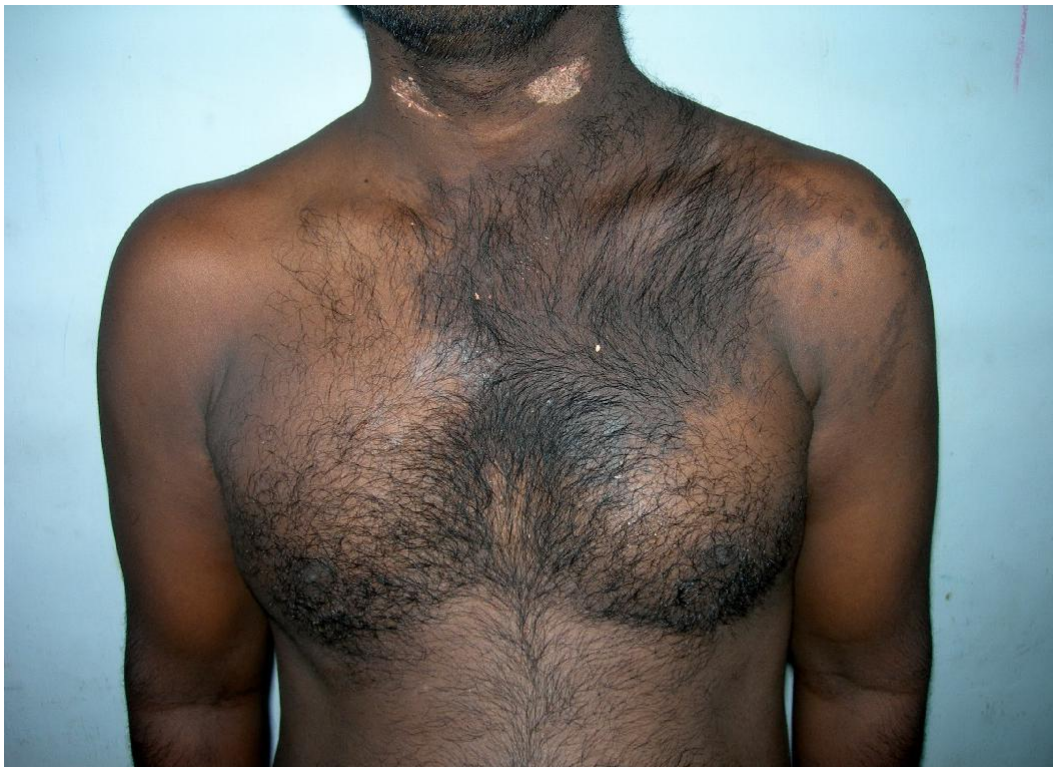
## DISCUSSION

The giant pigmented nevus is also known the bathing trunk nevus, congenital nevomelanocytic nevus, giant hairy nevus and is characterized by the presence of large, darkly pigmented hairy patches (Stojanovic et al., 2000). Synovial sarcoma accounts for 5 to 8% of all STS and is the fourth most common STS (Kransdorf, 1995). It occurs in young adults, in the particular regions in relation to joints (within 5 cm), tendon sheaths, tendons and mesenchymal membranes or in areas where there is no synovium such as the abdominal wall, retro-peritoneum, back, lung and heart. Synovial sarcoma is named for its

\*Corresponding author. E-mail: rekha\_a@yahoo.com.



**Figure 1.** Distended veins and the overlying skin which was stretched and shiny.



**Figure 2.** Large hairy cell nevus occupying the entire left anterior chest wall, extending on to the neck.

resemblance to developing synovial tissue under light microscopy. It arises from the pluripotential mesenchymal cells near joint surfaces, tendons, tendon sheaths, juxta-articular membranes, and fascial aponeuroses. It

resembles the synovium and hence the name, even though less than 10% are intra-articular (Kransdorf, 1995; Spillane et al., 2000). They present as deep seated slow growing masses or occasionally as lung metastases.

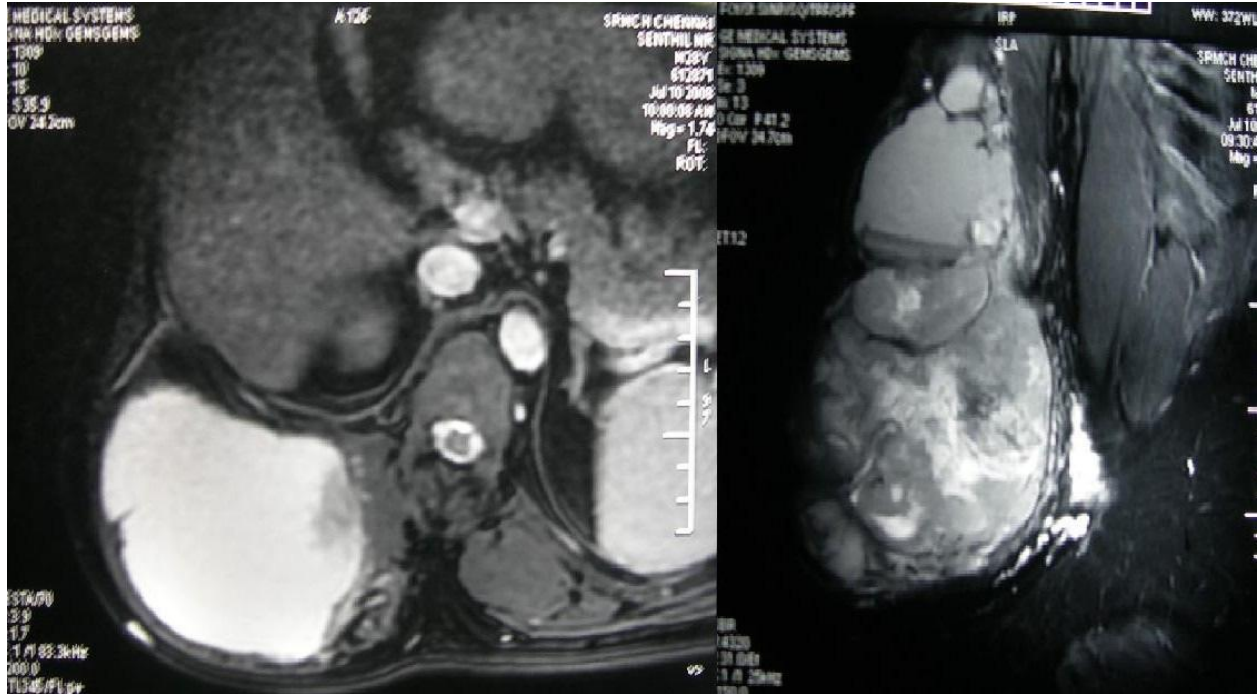


Figure 3. CT scan.

## Pathology

Microscopy shows two populations of cells biphasic (epithelioid and spindle cell) and monophasic spindle cell or mono phasic epithelioid (Spillane et al., 2000). A t(X; 18) (p11.2; q11.2) translocation is found in almost all synovial sarcomas (80%) regardless of the histologic type - t(X; 18) (p11.2; q11.2) seems to be specific. It is not found in other spindle cell sarcomas, and very rarely detected in other tumors as malignant fibrous histiocytoma or fibro sarcomas (Ladanyi, 2001; Klijanienko et al., 2002). There is a correlation between biphasic type and SYT/SSX1 variant (where SSX2 involvement is never detected), SYT/SSX2 is more common than SYT/SSX1 in monophasic one. SYT/SSX1 variant might be less favorable, associated with higher tumor proliferating rate and reduced overall survival (metastasis free survival 42 vs. 80%). These genes appear to be transcription regulators, whose functions occur primarily through protein-protein interactions. The tumor cells stain for CD 99 keratin and EMA (epithelial membrane antigen) (Miettinen et al., 2001).

## Imaging

MRI is the imaging of choice as it delineates the vessels, their relationship with the tumor and any joint involvement (van Rijswijk et al., 2001). A heterogenous intermediate signal on T1 and a hyper-dense signal on T2 weighted images are seen. Very often the nearby joint shows

osteoporosis which is non specific. A plain X-ray may show fine, stippled calcification in 30% of patients.

## Treatment

Surgical excision with negative margins at resection is the treatment of choice. (Younger age, biphasic histological type, distal tumor location, a smaller tumor size (<5 cm), negative margins at resection and adjuvant radiotherapy are associated with better prognosis, while invasion of bone and neurovascular structures and cellular atypia are bad prognostic indicators) (Lewis et al., 2000). Post-operative radiotherapy in the dose of 40 to 60 gray improves the prognosis (Ferrari et al., 2004), but a neuro vascular bundle or an open physis makes radiotherapy difficult. Improved survival is reported by some with the use of doxorubicin, cyclophosphamide based regimens and immunotherapy with autologous dendritic cells (Matsuzaki et al., 2002). Post operative radiotherapy and chemotherapy permit limb preservation, limit local recurrence and micro metastases in the lung.

## CONCLUSION

The prognosis of SS is poor whether they are monophasic or biphasic. Overall, survival rates are 36 to 76% at 5 years and 20 to 63% at 10 years. Synovial sarcoma of the head and neck region has a better prognosis than that of sarcoma involving the extremities,

with 5 year survival rates of 47 to 82%. There have been reports of synovial sarcoma from non articular surfaces but there is no report of its occurrence with a hairy nevus. The hairy cell nevus is associated with melanoma and other skin cancers. They can occur in the brain and the spinal cord and cause hydrocephalus, developmental delays and seizures. Till further studies shed more light, this will remain a co- incidental association.

## REFERENCES

- Ferrari A, Gronchi A, Casanova M (2004). Synovial sarcoma: a retrospective analysis of 271 patients of all ages treated at a single institution. *Cancer*, 101(3): 627-634. (Aug 1)
- Klijanienko J, Caillaud JM, Lagacé R, Vielh P (2002) Cytohistologic correlations in 56 synovial sarcomas in 36 patients: the Institut Curie experience. *Diagn Cytopathol.*, 27(2):96-102.
- Kransdorf MJ (1995). Malignant soft-tissue tumors in a large referral population: distribution of diagnoses by age, sex, and location. *AJR Am. J. Roentgenol.*, 164 (1):129-34. Jan
- Ladanyi M (2001) Fusions of the SYT and SSX genes in synovial sarcoma. *Oncogene.*, 20(40): 5755-5762.
- Lewis JJ, Antonescu CR, Leung DH(2000) Synovial sarcoma: a multivariate analysis of prognostic factors in 112 patients with primary localized tumors of the extremity. *J. Clin. Oncol.*, 18(10): 2087-2094.
- Matsuzaki A, Suminoe A, Hattori H, Hoshina T, Hara T (2002) Immunotherapy with autologous dendritic cells and tumor-specific synthetic peptides for synovial sarcoma. *J. Pediatr. Hematol. Oncol.*, 24(3): 220-223.
- Miettinen M, Limon J, Niezabitowski A (2001) Calretinin and other mesothelioma markers in synovial sarcoma. *Am. J. Surg. Pathol.*, 25(5): 610-617.
- Spillane AJ, A'Hern R, Judson IR (2000) Synovial sarcoma: a clinicopathologic, staging, and prognostic assessment. *J. Clin. Oncol.*, 18(22): 3794-3803.
- Stojanovic S, Poljacki M, Tasic S (2000). Congenital giant pigmented hairy nevus — case report. *Med. Pregl.*, 53: 305-308.
- van Rijswijk CS, Hogendoorn PC, Taminiau AH, Bloem JL (2001) Synovial sarcoma: dynamic contrast-enhanced MR imaging features. *Skeletal Radiol.*, 30(1):25-30.