

Full Length Research Paper

A study on the determinants of the effects of *Aloe vera* on indomethacin induced ulcers in rats

Borris N.K*, Arriel J.S and Roa B.S

Department of Pharmacy, Faculty of Medical Sciences, Guru Gobind Singh Indraprastha University, Delhi, India.

Accepted 13 July, 2019

This study was performed to determine the effects of *Aloe vera* on indomethacin induced ulcers in rats. Albino rats (Wister strain) of either sex weighing between 150 and 200 gms were randomly allotted into four groups with six animals each. Indomethacin was administered orally in the dose of 20 mg/kg body weight and kept fasting for 6 h. *A. vera* powder was mixed with gum acacia, the solution was administered orally through the oral gavage to rats in the dose of 200 mg/kg. Omeprazole (20 mg/kg) was administered intraperitoneally as a standard drug for present study. At the end of the study, rats were sacrificed and stomachs were opened and stored in 5% formalin solution, ulcer index and histological changes were studied. Student-‘t’ test analysis was used for the present study. It was found that *A. vera* showed statistically significant anti-ulcer activity comparable to standard drug omeprazole. The mean ulcer indexes of two drugs were statistically significant (P value is < 0.001). Therefore, the results were suggestive of anti ulcerogenic activity of *A. vera*.

Key words: *Aloe vera*, gastric ulcer, indomethacin, omeprazole.

INTRODUCTION

Peptic ulcer is a chronic disease which impairs the quality of life and is associated with increased morbidity and mortality. Peptic ulcer disease is a worldwide problem. Statistics from all sources indicate 10% or more of adult population are affected within their life time and 50% of healthy individuals complain of dyspepsia (Laurence, 1996). Peptic ulcer affects individuals from 20 to 60 years of age with males being predominantly affected. The incidence of duodenal ulcer is more frequent than gastric ulcer (ratio 4:1). Considering the etiology of peptic ulcers, there are two prime factors responsible: the “aggressive” factors and the “defensive” factors. Ulcers are caused by and they persist as a result of imbalance between aggressive and defensive factors. The aggressive factors include acid, pepsin, free radicals, infectious agents as *Helicobacter pylori*, chemicals and to a lesser extent bile salts and pancreatic enzymes. While the defensive factors include the adherent mucin, bicarbonate, prostaglandins and mucosa blood flow. Due

to any cause, an increase in aggressive factors or a decrease in defensive factors will lead to loss of mucosal integrity resulting in ulceration (Alan, 1985). Etiological factors include: diet (Lewis, 1978), tobacco smoking (Doll, 1958), alcohol consumption (Hagnell, 1957), non-steroidal anti-inflammatory drugs (Kevin et al., 1985), corticosteroids (Green, 1976), psychological stress (Pfeffer, 1982), *H. pylori* infection (Blaser, 1987) and genetic factors (Doll and Kelloff, 1951).

Considering the present status, the antacids provide symptomatic relief without inhibiting the gastric secretion or efficiently promoting healing. The H₂ receptor blockers and proton pump inhibitors although decrease the acid secretion and promote healing of ulcer, but have not proved their worth in preventing relapse and recurrence. Also “acid rebound” after cessation of therapy and long term adverse effects limit their utility. The anticholinergics, prostaglandin analogs and ulcer protective agents are not very effective antiulcer agents. Ulcer healing drugs like carbenoxolone is associated with increased mineralocorticoid activity (Laurence, 1996). Therefore the present therapy is not satisfactory. *Aloe vera* derives from the Arabic word “Alloeh” meaning “shining bitter substance,” while “vera” in Latin means

*Corresponding author. E-mail:borris.manuscript@gmail.com.

"true." 2000 years ago, the Greek scientists regarded *A. vera* as the universal panacea. The Egyptians called *Aloe* "the plant of immortality." *Aloe* plants have been used medicinally for centuries. Among them, *Aloe barbadensis* (1,8-Dihydroxy-3-hydroxymethyl-10-(6-hydroxymethyl-3,4,5-trihydroxy-2-pyranyl anthrone) commonly called *A. vera*, is one of the most widely used healing plants in the history of mankind.

Two distinct preparations of *Aloe* plants are most used medicinally. The leaf exudate (*Aloe*) is used as a laxative and the mucilaginous gel (*A. vera*) extracted from the leaf parenchyma is used as a remedy against a variety of skin disorders (Capasso and Gagarella, 1997). *Aloe* leaf exudate also possesses anti diabetic (Ghannam et al., 1986) and cardiac stimulatory activity (Yagi et al., 1982). *A. vera* also has anti ulcer effect. Anti-ulcer activity may due to its anti-oxidant activity, anti-inflammatory, mucus secreting, cyto protective or healing activities.

Therefore, this study was conducted to evaluate the "anti-ulcer effects of *A. vera* in non-steroidal anti-inflammatory drug induced peptic ulcers in albino rats".

MATERIALS AND METHODS

Albino rats (Wister strain) of either sex weighing between 150 to 200 gms were used for the study. The study was performed in the experimental laboratory in the Department of Pharmacology after obtaining approval from the Institutional Animal Ethics Committee. Rats were purchased from National Institute of Nutrition, Hyderabad. The animals were acclimatized for two weeks before experimentation, they were maintained on synthetic pellet feed (Pranav Agro Industries Ltd. Sangli, Maharashtra) and clean water *ad libitum*. Animals were housed in controlled conditions with temperature of $25 \pm 2^\circ\text{C}$ and 12/12 h light-dark cycle environment; they were randomly allocated to different experimental groups and placed in cages with mesh bottom to prevent coprophagy.

Four groups of albino Wister rats six per each group were selected for the present study. First group was taken as a normal control group while second group was taken as an indomethacin induced gastric ulcer control group. In this group, rats were fasted 24 h and then indomethacin was administered orally through the gastric gavages (20 mg/kg). The rats were killed 6 h after indomethacin administration. The stomachs were opened along the lesser curvature and the stomach were isolated and washed in normal saline. Then, the stomachs were observed with the help of magnifying lens, and its external and internal surface was studied and observed hemorrhage, dilation of blood vessels, ulceration, perforation, size and number of ulcers and ulcer index was evaluated according to the severity of ulcers. The stomachs were stored in the 5% formalin (Vananenn et al., 1991).

Third group was taken as a test (*A. vera*) group. *A. vera* powder was purchased from Madvik Research laboratory Pvt. Ltd. *A. vera* powder was mixed with gum acacia and diluted with distilled water. The prepared solution was administered orally through the gavage to rats. The pretreatment of *A. vera* powder was gavaged in the dose of 200 mg/kg to albino rats (Subramanian et al., 2007). The treatment schedule was once a day and it was continued for five days. After completing the five days, rats were kept 24 h fasting and then indomethacin was given orally, and after 6 h rats were sacrificed, stomachs were opened and washed with normal saline and fixed in 5% formalin.

Fourth group was taken as a standard (omeprazole) group; it was the standard drug for the present study. Propylene glycol was

served as vehicle for omeprazole (20 mg/kg) administered intraperitoneally (Jagruthi et al., 1997). This treatment was continued for five days, at the end of the last day rats were kept fasting for 24 h, after which indomethacin was administered orally, rats were killed after 6 h, stomachs were opened and washed with normal saline and stored in 5% formalin solution.

Ulcer indexing (UI)

The dissected stomachs were cut open along the lesser curvature and the inner surface was examined for ulceration. The open stomachs were studied by individuals who were blinded for test drugs and control animals (Adami et al., 1997).

Ulcer number

Total numbers of ulcers in each stomach were noted and petechial hemorrhage congestion, etc. was also noted.

Ulcer size

With the help of magnifying lens the size of each ulcer measured along the length of any lesion within 1 mm was taken as pin point.

In indomethacin induced gastric ulcer

Ulcer indexing was done according to the modified scoring system of adami et al. (1997) as follows: 0 = no lesions, 1 = hemorrhagic suffusions, 2 = from 1 to 5 small ulcers up to 3 mm size, 3 = many small ulcers more than 5 or 1 ulcer of more than 3 mm, 4 = many ulcers of more than 3 mm, 5 = perforated ulcers. The mean scores for each group were then calculated and the results were analyzed.

Histological studies

A portion of the ulcer region in the stomach was dissected out and fixed in 5% buffered neutral formalin solution for histological observations. After fixations, tissues were embedded in paraffin, solid sections were cut at 5 μm and stained with hematoxylin and eosin. The sections were examined with the help of a light microscope and photomicrographs were taken.

Statistical analysis

Data were expressed as mean \pm SEM. Statistical analysis was done using unpaired student "t"-test. P value 0.05 was considered statistically significant.

RESULTS

The gastric ulcer control group presented with features of ulceration. On gross examination, serosal surface of stomach showed marked indurations, dilated blood vessels, ecchymosis and hemorrhagic sites (Figure 3b) when compared with normal control group (Figure 3a). Mucosal surface presented with features of severe degree of hyperemia, congestion and large number of pin point ulcers of varying sizes with central clots and features of perforation in the stomach. The ulcer index was $U.I \pm SEM: 50 \pm 3.5$. Microscopic features were

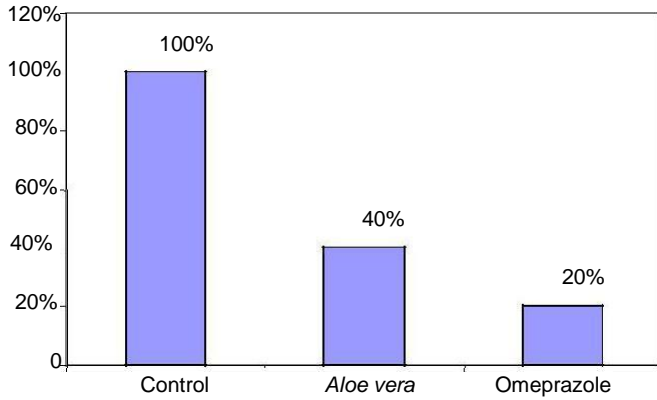
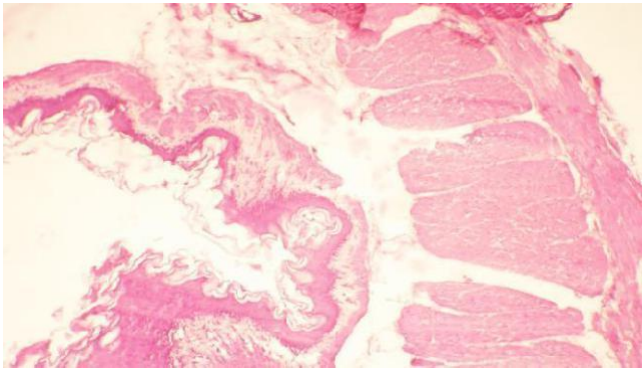
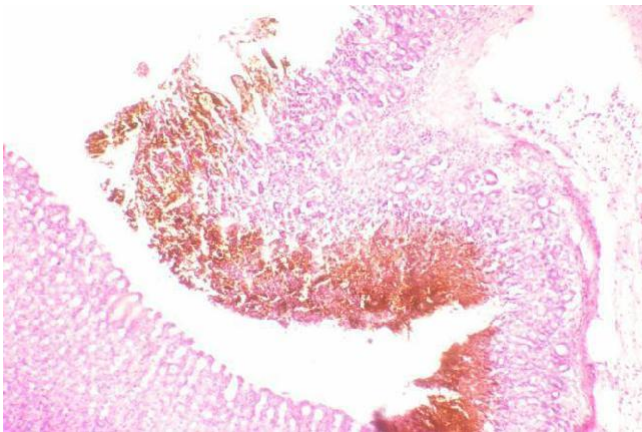


Figure 1. Bar diagram showing percentage of injury in indomethacin induced gastric ulceration. Percentage of injury in gastric ulcer control group is 100% and *Aloe vera* pretreated group is 40% and omeprazole treated group is 20%.



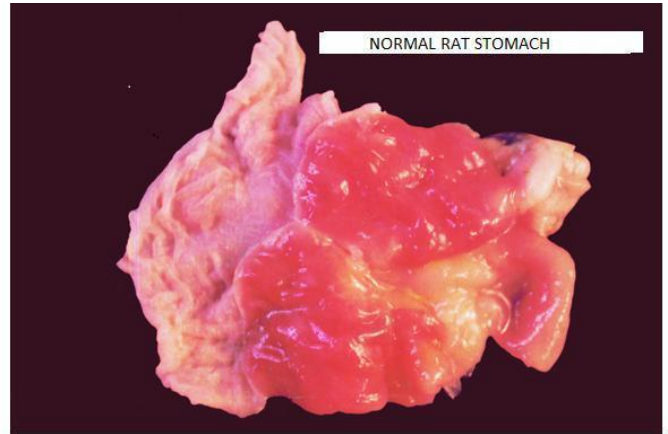
a. Showing the section of normal rat gastric mucosa



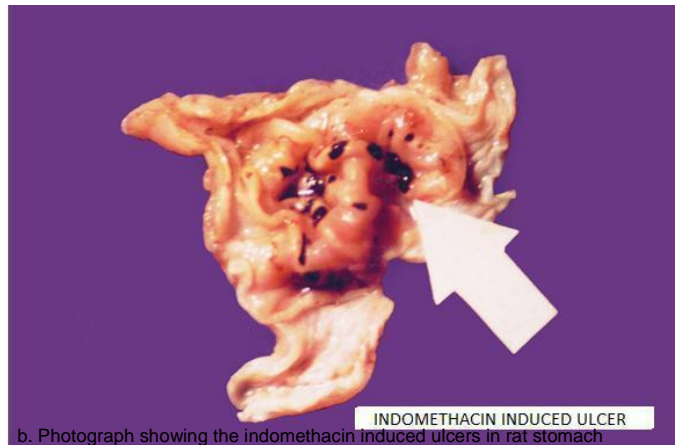
b. Showing the section of indomethacin induced rat gastric mucosal erosion

Figure 2. Histopathological sections of normal rat and indomethacin induced rat gastric mucosa.

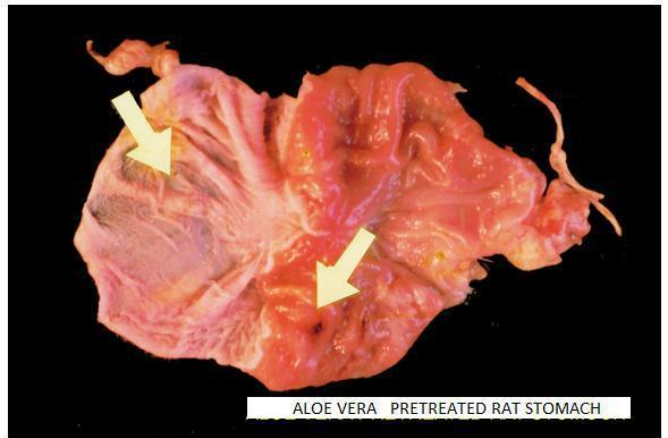suggestive of acute gastric ulceration with de-epithelialization (Figure 2b) when compared with normal control group (Figure 2a). Animals pretreated with *A. vera* showed few signs of mucosal injury (Figure 3c), but



a. Photograph showing normal rat stomach



b. Photograph showing the indomethacin induced ulcers in rat stomach



c. Photograph showing the *Aloe vera* pretreated rat stomach

Figure 3. Photographs of rat stomach: a; normal, b; indomethacin induced, c; *Aloe vera* pretreated.

the percentage of damage was less as compared to control group (Figures 1 and 3c). Serosal surface revealed very few dilated blood vessels and hemorrhages. Mucosal surface revealed few ulcers of varying sizes. Correspondingly, the ulcer index also was

reduced, U.I \pm SEM: 20 ± 1.79 .

Animals treated with omeprazole maintained near normal pattern. Serosal surface looked amber colour with few signs of dilated blood vessels and hemorrhagic suffusions. Mucosal surface retained the normal rugae pattern with minimal signs of mucosal injury. The ulcer index was markedly reduced, U.I \pm SEM: 10 ± 1.96 . Thus, animals treated with standard drug omeprazole showed antiulcer activity.

DISCUSSION

In the present study, the anti ulcer effect of *A. vera* in non-steroidal anti-inflammatory drug (indomethacin) induced peptic ulcer was observed. The mean ulcer index of control group was 50 ± 3.5 . In test (*A. vera*) group, mean ulcer index was 20 ± 1.79 and the standard omeprazole treated group mean ulcer index was 10 ± 1.96 . The results were statistically significant ($P < 0.001$).

In most of the cases, non-steroidal anti-inflammatory drugs like indomethacin and aspirin are known to induce numerous punctiform and filiform gastric ulcers during the course of anti-inflammatory therapy and hence, indomethacin induced model was used in the present study. Although, the mechanisms underlying the ulcerogenicity of indomethacin are not completely, but inhibition of prostaglandin synthesis may be important (Vane, 1971). This is supported by Ferreira et al. (1974) study, stating prostaglandins normally have protective function in the stomach by maintaining gastric microcirculation. Magri et al. (2007) reported that prostaglandin promotes mucus and bicarbonate secretions. Indomethacin induced gastric damage to rat gastric is markedly dependent on luminal pH (Elliott et al., 1996). Gastric damage may potentially facilitate the indomethacin induced mucosal damage by two mechanisms: (1) by enhancing gastric absorption of these drugs or (2) by amplifying mucosal injury (Yeomans et al., 1992).

The antiulcer activity of *A. vera* is due to its anti-inflammatory (Robert et al., 1979), cytoprotective (Mahattanadul, 1995), healing (Teradaira et al., 1993) anti oxidant activity and mucus stimulatory effects (Visuthipanich, 1988). *A. vera* has anti-inflammatory effects of leukocyte-endothelium interaction in the gastric microcirculation of *H. pylori* infected rats (Prabjone et al., 2006). The observation that *A. vera* extract inhibits acid secretion may be due to the presence of lectins in the plant (Blitz et al., 1963). Lectins are proteins/glycoproteins which are capable of recognizing and binding to carbohydrate moieties (Bardocz et al., 1995). It has been shown that lectins inhibit aminopyrine uptake by parietal cells (Healey et al., 1998). Thus, the ability of the extract to inhibit gastric acid output maybe as a result of direct action on the acid producing cells. Administration of *A. vera* enhance mucous resistance and resulted in decrease of ulcer index and ulcerated

surface. *Aloe buettneri* extract increased gastric mucus production (Kossi et al., 2011). According to Hiruma-Lima et al. (2006) gastric mucus is a viscous, elastic, adherent and transparent gel formed by water and glycoproteins covering the entire gastrointestinal mucosa. These authors reported that the protective properties of the mucus barrier depends not only on its gel-like structure, but are also related to the amount or thickness of the layer covering the mucosal surface. Mucus protects the gastric mucosa against irritants, such as ethanol, HCl and acetyl acid. The cytoprotective action of *A. vera* may be due to its active ingredients like tannins, saponins and flavonoids (Rajasekaran et al., 2005a). The proton pump inhibitor, omeprazole is having a mechanism of action on the development of acute ulcers and accelerate the healing of preexisting ulcers appears to be mainly due to its potent and long lasting antisecretory activities (Osamu, 1984). This study suggest that *A. vera* possess cytoprotective effects and acid reducing effects like omeprazole.

Conclusion

A. vera showed statistically significant anti ulcer activity comparable to standard drug omeprazole. The mean ulcer indexes of two drugs are formed to be statistically significant (P value is < 0.001). Therefore, the results were suggestive of anti ulcerogenic activity of *A. vera*. However, the cellular mechanisms for these actions remain to be established.

REFERENCES

- Adami R, Maraggi Uberty E, Turba C (1997). Pharmacological research on gefenate, a new synthetic isoprenoid with anti ulcer activity. *Br J. Pharmacol.*, 120: 581-586.
- Alan B, Thomson R, Mahachai v (1985). "Medical management of complicated peptic ulcer disease"; In : *Bokus Gasroenterology* : 4 ed ; (William s Haubrich, Martin h Kalsler, Fenton Schaffer eds.); W.B Sander Company; Tokyo, p. 116.
- Bardocz S, Grant G, Ewen SWD, Dunguid TJ, Brown DS, Englyst K, Pusztai A (1995). Reversible effect of phytohaemagglutinins on the growth and metabolism of rat gastrointestinal tract. *Gut*.37: 353-360.
- Blaser MJ (1987). Gastric *Campylobacter* like organisms, gastritis and peptic ulcer disease, *Gastroenterology*, 93: 371-383.
- Blitz J, Smith J, Gerard J (1963). *Aloe vera* gel in peptic ulcer therapy: preliminary report. *J. Am. Osteopathic Asso.*, 62: 731-735.
- Capasso F, Gaginella TS (1997). *Laxatives: a practice guide*. Milan: Springer Italia.
- Doll R, Kellock TD (1951). The separate inheritance of gastric and duodenal ulcers, *Ann Eugenics*. 16: 231-40.
- Doll R, Jones FA, Pygolt F (1958). Effect of smoking on the production and maintance of gatric and duodenal ulcers. *Lancet*, 1: 657-62.
- Elliott SL, Ferris RJ, Giraud AS, Cook GA, Skeljo MV, Yeomans ND (1996). Indomethacin damage to rat gastric mucosa is markedly dependent on luminal pH. *Clin. Exp. Pharmacol. physiol*. 23:432-434.
- Ferriera SH, Moncada S, Vane JR (1974). Proceedings: Potentiation dog knee joint, Brazilian J. *Pharmacol.*, 50: 461.
- Ghannam N, Kingston M, Meshaal IA, Tariq M, Parman NS, Woodhouse N (1986). The antidiabetic activity of *aloes*:

- preliminary clinical and experimental observations. *Horm. Res.* 24: 288-294.
- Green SB, Gail MH (1976). Steroids and peptic ulcer. *New Engl. J. Med.*, 294 :473.
- Hagnell O, Wretmark G (1957). Peptic ulcer and alcoholism. *J Psychosom Res.*, 2: 35-44.
- Healey ZV, Jordinsm M, Bliss PW, Arebi N, Calan J (1998). Broad bean and concavalin A lectins inhibit 14C-aminopyrine accumulation by rabbit parietal cells. *Gastroenterology*, 113: 654.
- Hiruma-Lima CA, Calvo TR, Rodrigues C M, Andrade FDP and Vilegas W, Souza Brito ARM ((2006)). Antiulcerogenic activity of *Alchornea castaneaeifolia*: Effects on somatostatin, gastrin and prostaglandin. *J. Ethnopharmacol.*, 1004: 215-224.
- Jagruthi K Desai, Ramesh K Goyal, Narayan S Parmar, 1997. Pathogenesis of peptic ulcer disease and current trends in therapy. *Indian J. Physiol. Pharmacol.*, 41(1): 3-15.
- Kevin JL, James RLA (1985). Drug and chemical induced Injuries of the stomach, *Bokus Gastroenterology*; 4th ed; (Haubrich WS, Kalser MH Roth LA, Schaffener F eds), 2: 976-1003.
- Kossi M, Kwashie E, Amégnona A, Kodjo A, Aklkokou MG (2011). Gastro protective Effect of Hydro alcoholic Extract of *Aloe buettneri*. *IJPR*, 10(1): 69-74.
- Laurence LB (1996). Agents for control gastric acidity and treatment of pepticulcer. Goodman and Gilman's The pharmacological basis of Therapeutics; 9th edn : (Joel G Hardman, Alfred Goodman Gilman; Lee E Limbird . eds) The Mcraw- Hill Companies, New York. pp. 901-14.
- Lewis EA, Aderoju EA (1978). Factors in the aetiology of Chronic duodenal ulcer in Ibadan. *Trop Geogr Med.*, 30: 75-9.
- Mahattanadul S (1995). Antigastric ulcer properties of *Aloe vera*. *Songklanakarinn J. Sci. Technol.*, 18: 49-57.
- Magri LDP, Batista LM, Almeida ABA, la Farias-Silva E, Areas MA, Souza Brito ARM ((2007). Dietary fibres prevent ethanol and nonsteroidal anti-inflammatory drug –induced gastric mucosal damage in rats. *Nutr. Res.*, 7: 109-112.
- Osamu V (1984). Effects of a proton pump inhibitor, omeprazole on gastric secretion and gastric and duodenal ulcers or erosions in rats. *Digestive Diseases Sci.*, 29: 394-401.
- Pfeffer CJ (1982). Drugs and peptic ulcer; (bocca Ratan, Florida eds), CRC Press Inc: p. 215.
- Prabjone R, Thong-Ngam D, Wisedopas N (2006). Antiinflammatory effects of *Aloe vera* on leukocyte-endothelium interaction in the gastric microcirculation of *Helicobacter pylori*- infected rats. *Clin. Hemorheol. Microcirc.*, 35: 359-66.
- Rajasekaran SK, Sivagnanam S, Subramaniam (2005a). Anti oxidant effect *Aloe vera* gel extraction streptozotocin induced diabetes in rats. *Pharmacol. Rep.*, 57: 90-96.
- Robert A, Nezamis JE, Lancaster C. and Hanchar AJ (1979). Cytoprotection by prostaglandins in Rats. *Gastroenterology*, 77: 433-443.
- Subramanian S, Satishkumar D, Aruselvan, Senthil kumar GP, Mahadevarao US (2007). Evaluation of Anti-ulcerogenic potential of *Aloe vera* leaf gel extract studied in experimental rats. *J. Pharmacol. Toxicol.*, 2(1): 85-97.
- Teradaira R, Shinzato M, Bepp UH, Fujita K (1993). Antigastric ulcer effects in rats of *Aloe arborescens* Miller var. natalensis Berger extract. *Phytother Res.*, 7: 34-36.
- Vananeenn PM, Medding JB, Wallace JL (1991). Role of oxygen derived free radicals in indomethacin- induced gastric injury. *Am. J. Physiol.*, 261: 470- 475.
- Vane JR (1971). Inhibition of prostaglandin synthesis as a mechanism of action for aspirin like drugs . *Natl. New Biol.*, 231: 232-235.
- Yagi A, Shibata S, Nishioka I, Iwadare S, Ishida Y (1982). Cardiac stimulant action of constituents of *Aloe saponaria*. *J Pharm Sci.*, 71: 739-741.
- Yeomans ND, Skeljo MV, Giraud AS (1992). The role of acid regulation in the treatment of NSAID –induced mucosal damage. *Digestion*, 51: 3-10.