

Full Length Research Paper

An investigation of the effects of aqueous extract of *Azadirachta indica* leaf and concomitant administration of chloroquine sulphate on the weight and liver cells of rabbit

*Ayi T. Amah, Offiong James Aboh and Abotsi Ariba

Department of Otolaryngology, Faculty of Medicine, University of Calabar, Calabar, Nigeria.

Accepted 17 October 2015

Recently herbal medications have been introduced into modern health scheme for the treatment of diseases. Aqueous extract of *Azadirachta indica* is commonly used in treatment of malaria in combination with chloroquine, especially now that a combined therapy is said to be more effective. This study is designed to investigate the effects of aqueous extract of *A. indica* leaf, and concomitant administration of chloroquine sulphate + aqueous extract of *A. indica* leaf on the weight and liver cells of rabbit. Eight adult male rabbits with average weight range between 1.29 to 1.52 kg obtained from Department of Zoology Ambrose Ali University, Ekpoma, Edo state, Nigeria, were used for this study. They were weighed at intervals of five days before and after the experiment. They were randomly divided into four groups (A - D) of two rabbits each. The chloroquine and aqueous extract of *A. indica* leaf was administered to the animals orally via a cannula inserted through the oral cavity. They were treated as follows, group A received (15 mg kg⁻¹ dry extract solution of aqueous extract of *A. indica*), Group B received (15 mg kg⁻¹ of chloroquine sulphate), group C received (10 0mg ml⁻¹ dry extract solution of aqueous extract of *A. indica* + 15 mg kg⁻¹ of chloroquine sulphate, and the control animals (group D) were given normal saline. Both treatment and control animals were sacrificed at the end of the experiment. The liver was carefully dissected out and immediately fixed in Bouin's fluid for histological studies. Groups A to D animals showed normal liver histoarchitecture and increase in weight: 2.1% (group A), 1.4% (group B), 0.7%, (group C) and 1.4% (group D) respectively. The average weight of the treated animal shows non-significant (P<0.05) increase compared with the weight of the animals in the control group. Our findings revealed that aqueous extract of *A. indica* leaf has no effect on the histology of the liver and weight of adult male rabbits, even when it is administered synergically with chloroquine sulphate at a reported and recommended safe dose.

Key words: Aqueous extract, *Azadirachta indica* leaf, chloroquine sulphate, weight, liver, rabbits.

INTRODUCTION

The use of herbal medications in the treatment of malaria is popular in many parts of Africa and Asia where malarial infestation is endemic, *Azadirachta indica*, in many

countries referred to as the neem tree (Dogonyaro in some part of Nigeria) has been extensively reported as being effective in the treatment of malaria caused by

various strains of plasmodium parasite even those resistant to traditional antimalarial drugs. Nwafor et al. (2003), Iwu et al. (1986), Okpanyi et al. (1981), Obaseki and Fadunson (1982), Khalid et al. (1986) and Nokov et al. (1982) reported that serious phytochemical constituents have been isolated from the neem plant and demonstrated to possess antimalarial properties. The use of chloroquine as a single first line drug treatment is now increasingly limited following the evolution of chloroquine – resistant Plasmodium *Falciparum*. Nevertheless, the low cost and easy availability makes chloroquine the choice for most patients in Africa (Nwafor et al., 2003).

The neem tree, a member of the Meliaceae family, appears to have originated in India and Southeast Asia and been spread throughout drier lowland tropical and subtropical regions of Africa, the Middle East, the America, Australia, and South Pacific islands. The leaves, used as medicine, are generally available year-round as the tree is ever green except during severe droughts or if exposed to frost. In these ancient texts, neem is mentioned in almost 100 entries for treating a wide range of diseases and symptoms (Schmutterer, 1995). Neem came close to providing a cradle-to-grave health care programme and was a part of almost every aspect of life in many parts of Indian subcontinent up to and including the modern era (Malanei, 2003). The major active constituents in neem are terpenoids such as azadirachtin, which are considered to be antimicrobial and insect repellent amongst many other actions, and fatty acids and possibly other compounds in neem oil (Rembold 1983; Schmutter et al., 1995).

Historical or traditional use (may or may not be supported by scientific studies); it has a long history of use in the traditional medical systems of India (Schmutterer, 1995). Neem leaf and bark extracts are most consistently recommended in ancient medical texts and by herbal practitioners for treatment of diseases such as gastrointestinal upsets, diarrheal, intestinal infections, Skin ulcers infections, and malaria (Schmutterer, 1995). Neem twigs are the most regularly used toothbrush for a large portion of the population of India and Nigeria and other countries where the tree is common (Ad Hoc Panel of the Board on Science and Technology for International Development, National Research Council, 1992). The claimed contraceptive effects of neem have been confirmed in some animal studies showing that seed extracts of neem are spermicidal (Garg et al., 1993).

The effectiveness of many of the uses of aqueous extract of neem leaf have been confirmed in modern research studies, for example, leaf extracts can combat

scabies infections (Bandyopadhyay et al., 2004; Pai et al., 2004; Charles and Charles, 1992). The potential adverse effects, and its safety on some human vital organs have been reported; Ucheya and Ochei (2011) in their extensive research work on the use of aqueous extract of neem leaf as antimalarial agent reported that

“the administration of *A. indica* at a high dose beyond 350 mg/kg/day of aqueous extract of *A. indica* leaf should be avoided especially in pregnant state in order to prevent low birth weight. Ucheya and Ochei (2011) reported that aqueous extract of *A. indica* leaf at a dose greater than 350 mg/kg/day is capable of inducing teratogenic effects on the liver histology, liver weight and body weight of neonatal rats, therefore the use of aqueous extract of *A. indica* leaf during pregnancy in the treatment of malaria and other diseases at a dose >350 mg/kg/day should be avoided. In their investigation, titled “is a safe dose of aqueous extract of *A. indica* toxic on the histology of the rabbit liver?” They reported that a safe dose (\leq 350 mg/kg body weight of rabbit) of aqueous extract of *A. indica* should be administered when used as a curative agent for any disease”. In their findings on “is a combine therapy of aqueous extract of *A. indica* leaf (neem) leaf and chloroquine sulphate toxic to the histology of the rabbit cerebellum? They reported that though a concomitant administration of chloroquine and aqueous extract of *A. indica* is capable of altering the pharmacokinetic properties of serum level and chloroquine in blood plasma, it has no effect on the histology of the cerebellum when administered at a recommended safe dose, despite the fact that it has been previously reported by several authors (Nwafor et al., 2003; Malanei, 2003; Nokov et al., 1982; Pant et al., 1986) to consist of biologically active substances. They also investigated the histological changes in rabbit kidney following a concomitant administration of aqueous extract of neem leaf and chloroquine sulphate, they reported that if *A. indica* is given at a safe concentration /dose, it is safe on the histology of the kidney and can be administered concomitantly with chloroquine sulphate if further research is carried out to prevent its ability to induce the reduction of the pharmacokinetic properties of chloroquine in the plasma when administered concomitantly (Ucheya and Ochei, 2011).

Acetone – water extract of neem leaf has been reported to have antimalarial and antiretroviral potentials (Udeinya et al., 2007). Traditionally, application of neem Leaf extract gel at a dose of 1 g (1/5 of a teaspoon) in the morning and at bed time, then thoroughly brushed all over the mouth, has been shown helpful for people with stomach ulcers (Bandyopadhyay, 2004). Creams containing 5% or more of neem oil or neem leaf extracts are typically applied at least twice per day for skin or vaginal infections, and Neem oil mixed in coconut or mustard oil base in a concentration of 1 to 4%, is used for repelling insects (Mishra et al., 1995). Water extracts

*Corresponding author. E-mail:ayi.amah@yahoo.com

of neem leaf have been shown to decrease blood levels of chloroquine in rats (Nwafor et al., 2003).

Malaria is a tropical disease that poses serious problems on human well-being especially in tropical countries where the environs provides conducive ground for the parasite to thrive well. This disease is a global problem because of migration and the mutant potential of the parasite in living organisms (Ucheya and Anibeze, 2011), with legal introduction of herbal medications into national health scheme, scientist have embarked on several researches as to investigate the possibilities of using neem extracts to cure some tropical diseases such as malaria, trypanosomiasis, leishimiasis, cholera, dysentary, stroke, hypertension, cough, mouth odour, bleeding, diabetes amongst others.

Irrespective of all reports on curative potential of neem extracts, Nwafor et al. (2003) reported that water extracts of neem leaf have been shown to decrease blood levels of chloroquine in rats, so these should not be combined until their safety can be demonstrated in humans (Nwafor et al., 2003). However, he emphasized that at the time of his research there was no well known drug interactions with neem. Anatomically, we intend to investigate the hepatic histo – architecture, since it is an organ commonly affected by malarial parasites. Secondly, neem has been documented to be a universal plant, and though undocumented; it is widely used in Nigeria especially by the villagers without knowledge of neither the accurate dosage nor the adverse effects. Thirdly, researchers who have worked on neem leaf extracts have suggested that the safety of the dose and extract employed should be checked and confirmed (Udeinye et al., 2007; Nwafor et al., 2003).

The reports of adverse effects of unconvictional medications have stimulated researchers to investigate on plants parts commonly use as herbal medications. However, this has formed the basis for this research work since the liver is the major organ for detoxification of drugs and toxins.

MATERIALS AND METHODS

Soxhlet extractor (50ml capacity), Matttler weighing balance, dissecting instruments-set, tissue processing materials (Xylene, Formaline, Alcohol, Rotary microtome, Knife, Slides, Cover slips, Paraffin, and embedding mould. Microscope with digital camera, film mountant. Test chemical– aqueous extract of neem. Chloroquine sulphate (May and Baker, Products, UK), Nivaquine Fort®, a brand of chloroquine sulphate (May and Baker Pharmaceutical PLC, Nigeria), fresh leaves of *A. indica* (collected from neem trees at the campus of the University of Nigeria, Enugu campus). Digital pH meter (P107, Consort, Belgium), ultraviolet-visible spectrophotometer (SP 8–100, Pye Unicam, UK), centrifuge (Beckman GS-15, UK), were used.

Exclusion criteria

The biochemical parameter for hepatotoxicity tests was not within the purview of this study.

Animals

A total of eight healthy adult male rabbits weighing between 1.29 to 1.52 kg, bought from Zoology Department Ambrose Ali university, Ekpoma, Edo-state Nigeria, were used for this study. They were randomly divided into four groups of two Rabbits each. Group A was administered aqueous extract of *A. indica* only, group B was administered Chloroquine Sulphate only, group C was given a combination of chloroquine and aqueous extract of *A. indica* leaf, while group D was the control and was given feed and saline water *ad libitum*. They were allowed to acclimatization for two weeks. Ethical standards of the University were adhered to in the course of the study.

Extract preparation

The method used for the extraction was according to the method described by Nwafor et al. (2003). The leaves were cut fresh from the Vicinity of the Staff quarters, University of Nigeria, Enugu Campus, and allowed to air dry under room temperature. The extract was prepared as follows: fresh leaves of *A. indica* (580 g) were thoroughly mashed in distilled water (2 L). The decoction was filtered using a clean sieve cloth. Its concentration was determined by evaporating the extract to dryness. Freshly prepared extracts were used. Concentration of the aqueous extract was found to be 15.25 mg mL⁻¹ dry extract and pH was 5.2, indicating a weakly acidic extract. The extractive yield (expressed as dry mass of the extract relative to the mass weight of the leaves) was determined to be 4.2%. The extract was concentrated so as to prepare 100 mg mL⁻¹ dry extract solution.

Preparation of chloroquine sulphate

The Nivaquine Fort® (a brand of chloroquine sulphate was used for the preparation) was suspended in 3% Tween 85 to give 100 mg mL⁻¹ suspension, this method was according to the method used by Nwafor et al. (2003).

Administration of the chloroquine sulphate and aqueous extract of *A. indica* leaf

The animals were given between 0.16 and 0.21 ml of the chloroquine sulphate suspension depending on their body mass. Both chloroquine sulphate and the extract were administered to the animals orally via a cannula inserted through the oral cavity. The experiment commenced by

administration of 15 mg kg^{-1} of chloroquine sulphate to each rabbit orally. This dosing was based on the 15 mg kg^{-1} loading dose of chloroquine sulphate in humans (Emdex Desk Reference). The second part of the experiment commenced following the end of the 1st part by administration of 15 mg kg^{-1} of chloroquine sulphate (Nwafor et al., 2003) orally to each rabbit and 100 mg kg^{-1} of aqueous extract of *A. indica* was immediately administered orally to each rabbit, this was based on the report that aqueous extract of *A. indica* is safe at a concentration $\leq 350 \text{ mg/kg/bodyweight}$ of mice (Ucheya and Anibeze, 2009). The animals received between 1.1 and 1.4 ml of the aqueous extract relative to their body mass. The third group (c) was administered 15 mg kg^{-1} chloroquine phosphate concomitantly with 100 mg kg^{-1} of aqueous extract of *A. indica* leaf.

Result analysis

The histology of the liver structure was compared for the drug administered alone, with that administered concomitantly with the aqueous extract of *A. indica*. Finally, the animals for the drug administered alone with that administered concomitantly with the aqueous extract of *A. indica* leaf were compared with that of the control animals. The animals were then weighed and the mean weight for each group was noted. This was done for fifteen (15) days at interval of five (5) days from the time of acclimatization of animals" upto fifteen (15) days after drug administration. At the end of the fifteenth day after drug administration, the animals were sacrificed by inhalation of chloroform. The liver from each experimental and control animals were immediately extracted for histological processing and production of Photomicrograph.

The microscopic features of the liver in the Photomicrographs were assessed by comparing the cell architecture of the treated animals in groups A-C with the cell architecture of control animals in group D.

Statistical analysis

Significance difference between the control and test values was evaluated using Student's *t*-test. This was done using the computer programme „Statistical Package for Social Sciences (SPSS)“, version 15.0. $P < 0.05$ was taken as the significant level.

RESULTS

The effect of aqueous extract of *A. indica* leaf and chloroquine sulphate on the histology of the liver tissue

The control animals revealed a normal histoarchitecture as shown in the photomicrographs of the animals in

group D. This is evidenced in the photomicrograph of the liver tissue, which reveals a normal microscopic structure of the liver; this is presented in the photomicrographs by the presence of normal cell features such as: regularly arranged sinusoids without any lost of liver cells (Figure 4).

The histology of the liver of rabbit that was treated orally with aqueous extract of *A. indica* only, shows a normal architecture of the liver cell, with no injury or inflammatory reaction of the sinusoidal cells (Figure 1). The histology of the liver tissue of rabbit that was treated orally with chloroquine presented a normal architecture of the liver cells which is evidenced by the normal appearance of the liver sinusoids (Figure 2). Histology of the Liver tissue of rabbits treated concomitantly with chloroquine and aqueous extract of *A. indica* orally (group C) revealed a normal histoarchitecture of the liver tissue and was demonstrated by the normal appearance of the liver cells (Figure 3).

The effect of aqueous extract of *A. indica* leaf on the body weight of the adult male rabbits

Groups A, B, and C animals showed varying average percentage weight increase of 2.1% (group A), 1.4% (group B), 0.7% (group C), respectively. When the average percentage body weight increase by the treated animals in groups A, B and C was compared to the average percentage body weight increase by the control animals (group D), it was statistically not significant ($P > 0.06$) as shown in Table 1.

DISCUSSION

The analysis of results obtained from this study shows that the animals that received aqueous extract of *A. indica* orally in the treated group (A), revealed a normal histoarchitecture of the liver cells (Figure 1) and a weight increase of 2.1% (Table 1). This result is in consistence with the report by Ucheya and Anibeze (2009) on "Histological changes in mice organs administered with various concentrations of neem extracts (*Azadirachta indica*)" in which they reported that aqueous extract of *A. indica* leaf on the histology of liver at a concentration $\leq 350 \text{ mg/kg/body weight}$ is safe on the histology of mice organs including the liver. The animals in group (B) that were administered chloroquine sulphate also presented a normal liver cell architecture (Figure 2) and a percentage increase in body weight of 1.4% (Table 1). This is in consistence with the report that chloroquine is safe on the organ when used at a dose recommended to be safe but when administered indiscriminately without prescription through over the counter sales of drugs, it is capable of inducing derangement of the liver (Ngokere and Ngokere, 2003). The animals in group (C) that were administered with chloroquine sulphate + aqueous extract of *A. indica*

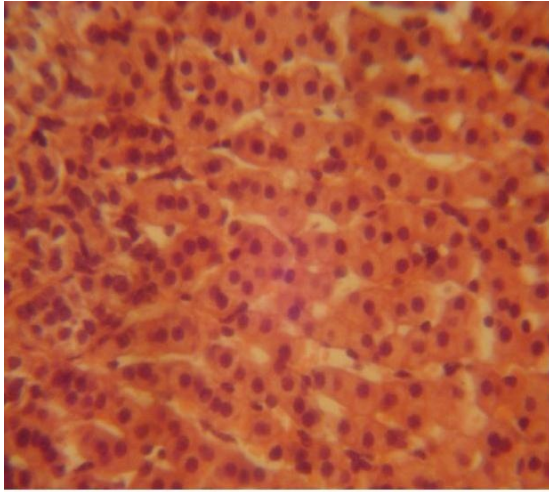


Figure 1. Histology of the liver of Rabbit treated orally with aqueous extract of *A. indica* only shows normal liver architecture, with no injury or Inflammatory reaction. Mag. X400 (H & E).

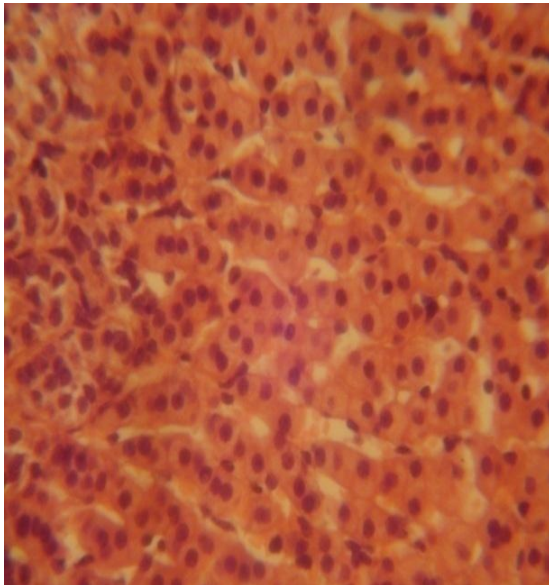


Figure 2. Histology of the liver tissue of Rabbit (control animals) treated orally with chloroquine sulphate Shows normal liver architecture with normal sinusoidal cells. X400 (H & E).

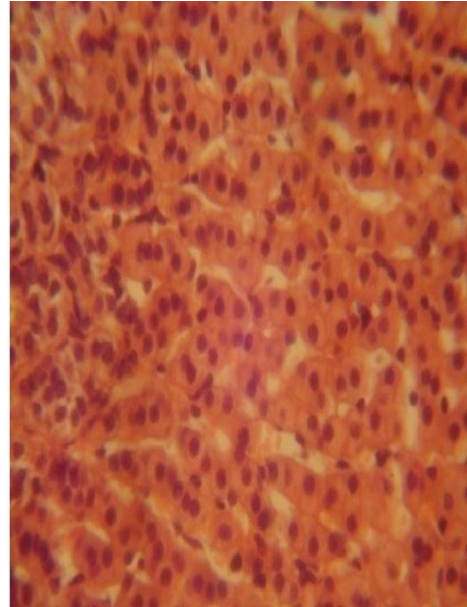


Figure 3. Histology of the liver tissue of Rabbit treated concomitantly with chloroquine and aqueous extract of *A. indica* orally shows the sinusoidal cells to be normal. Mag. X400 (H & E).

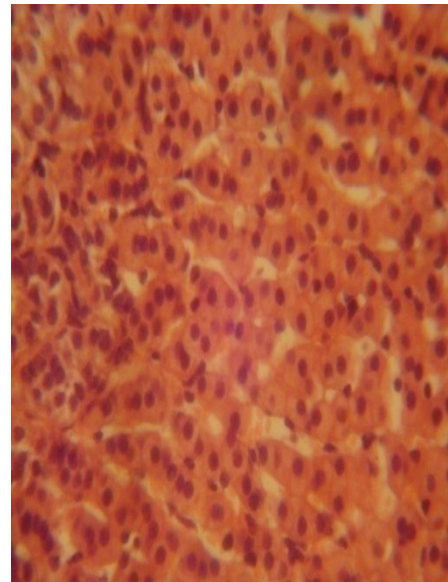


Figure 4. Histology of the liver of the control Animals shows normal liver architecture with normal. Mag. X400 (H & E).

leaf revealed normal hepato architecture (Figure 3), there was also an increase in body weight (Table 1). However, this contradicts the report by Nwafor et al. (2003) that a concomitant administration of chloroquine and aqueous extract of *A. indica* leaf caused changes in the pharmacokinetic properties “a significant decrease in the serum concentration, slower absorption and elimination

as well as longer half-life of chloroquine sulphate”. The group D animals (control) that were administered with saline water only also showed a normal hepato architecture which is presented by normal and regularly

Table 1. Effect of single and combined dose of aqueous extract of *A. indica* leaf and chloroquine on the weight of male Rabbits.

Animal group	Mean Weight before drug administration (kg)(a)	Mean Weight at 5days of drug administration (kg)	Mean Weight at 10days of drug administration (kg)	Mean Weight at 15days of drug administration (kg)	Mean weight administration (kg)(b)	Mean weight difference (kg) (b-a)	Percentage weight Gained (kg)
A	1.41 ± 1.3	1.42 ± 1.3	1.44 ± 1.1	1.44 ± 0.3	0.03	± 1.0	2.1%
B	1.43 ± 1.4	1.43 ± 1.4	1.44 ± 3.1	1.45 ± 2.1	0.02	± 0.7	1.4%
C	1.48 ± 0.4	1.48 ± 0.4	1.48 ± 0.4	1.49 ± 0.3	0.01	± 0.1	0.7%
D	1.43 ± 1.4	1.44 ± 2.2	1.44 ± 3.1	1.45 ± 2.4	0.02	± 3.4	1.40%

arranged sinusoidal cells.

The present investigation shows that even though a concomitant administration of chloroquine and aqueous extract of *A. indica* is capable of altering the pharmacokinetic properties of serum level and chloroquine in blood plasma, it has no effect on the histology of the liver when administered at a dose recommended safe. Though the effect of administration of a combine therapy of aqueous extract leaf + chloroquine sulphate on the hepato architecture is in contrast with the pharmacokinetics properties of chloroquine in the blood plasma as reported by Nwafor et al. (2003), but it is in consistence with the report that combine therapy of aqueous extract of *A. indica* leaf and chloroquine sulphate is safe on the histology of the cerebellum and Kidney when administered (Ucheya and Ochei, 2011; Ucheya and Ochei, 2011).

From our present findings, it is suggested that before a concomitant therapy of aqueous extract of *A. indica* leaf and chloroquine sulphate can be employed in the treatment of malaria, further research should be carried out to ascertain its possible effects on other organs and the pharmacokinetic properties of chloroquine sulphate in the serum.

Conclusively, even though *A. indica* leaf has been reported by Nwafor et al. (2003), Malanei et al. (2003), Nokov et al. (1982), Khosla et al. (2000) and Pant et al. (1986) to consist of biologically active substances, these substances apparently have no effect on the histology of the rabbit liver when administered at a dose recommended as safe by researchers. It is recommended that further studies be carried out to corroborate these findings.

REFERENCES

Ad Hoc Panel (1992). The Board on Science and

Technology for International Development, National Research Council on Neem. A Tree for solving Global Problems. Washington, DC: National Academy Press.

Bandyopadhyay U, Biswas K, Sengupta A. (2004). Clinical studies on the effect of Neem (*Azadirachta indica*) bark extract on gastric secretion and Gastroduodenal ulcer. Life Sci., 75: 2867-2878.

Charles V, Charles SX (1992). The use and efficacy of *Azadirachta indica* ADR („Neem“) and *Curcuma longa* („Turmeric“) in scabies. A pilot study. Trop. George Med., 44: 178-181.

Emdex Desk Reference: Index of essential medicines, physicians and pharmacists Desk Reference, Lindoz products limited, Lagos (2001), p. 330.

Garg S, Taluja V, Upadhyay SN, Talwar GP (1993). Studies on the contraceptive efficacy of Praneem polyherbal cream as contraception. J. Heb. Plant., 48: 591-596.

Iwu MM, Obidoa O, Anazodo M (1986). The antimalarial activity of *Azadirachta indica* – mode of action. Pharmacy World, 3: 16-20.

Khalid AA, Duddeck H, Gonzalez SM (1986). Potential antimalarial candidates from African plants: an *in vitro* approach using *Plasmodium falciparum*. J. Nat. Prod., 52: 201-209.

Khalid SA, Farouk A, Geary TG, Jensen JB (1986). Biological Activities and Medicinal Properties of Neem. J. Insect Physiol., 46: 201-209.

Khare CP (2004). Indian Herbal Remedies. Berlin: Springer.

Khosla P, Bhanwra S, Singh J, Seth S, Srivastava RK (2000). Antihyperglycaemic Effects of *A. indica* (Neem) in normal and Alloxan induced Diabetic Rabbits. Indian J. Physiol. Pharmacol., 44: 69-74.

Malanie C (2003). Defense of Plants through Regulation of insect feeding behaviour. Florida Entomologist, 74: 18-23.

- Mishra AK, Singh N, Sharma VP (1995). Use of neem oil as a mosquito repellent in tribal Villages of Mandla district, Madhya Pradesh. *Indian J. Malariol*, 32: 99-103.
- Ngokere AC, Ngokere EC (2005). Indiscriminate use of chloroquine is toxic on the Histoarchitecture of the liver. *Jobiomed*, 03(2): 6-12.
- Nokov N, Labode O, Akhtardzhieve KH (1982). Study of flavonoid composition of *Azadirachta indica*. *Farm Sofia*, 32: 24-28.
- Nwafor SV, Okoli CO, Oyirioha AC, Nworu CS (2003). Interaction between Chloroquine sulphate and aqueous extract of *Azadirachta A. Juss* (meliaceae) in Rabbits. *ACTA Pharm.*, 53(2): 305-311.
- Obaseki O, Fadunson HA (1982). Antimalarial activity of *Azadirachta indica*. *Farm. Sofia*, 32: 24-28.
- Okpanyi SN, Ayo JO, Audaudi AO (1981). Anti-inflammatory and antipyretic activities of *Azadirachta indica*. *Planta Med.*, 41: 34-39.
- Pai MR, Acharya LD, Udupa N (2004). The effect of two different dental gels and a Mouth wash on plaque and gingival scores: a six-week clinical study. *Int. Dent. J.*, 54: 219-23.
- Pant N, Garg HS, Madhusudanan KP, Bhakuni DS (1986). Sulphurous Compounds from *A. indica* Leaves. *Fitoterapia*, 57: 302-304.
- Remboid H (1989). The azadirachtins-their potential for insect control. *Econ. Med. Plant Res.*, 3:57-72.
- Schmutterer H, Ascher KRS, Isman MB (1995). *The Neem Tree: Azadirachta indica A Juss and Other Meliaceous Plants*. Weinheim, Germany: VCH.
- Ucheya RE, Anibeze CIP (2009). Histological changes in mice organs administered with various concentrations of neem leaf extracts (*Azadirachta indica* leaf). *Biomed. Pharmacol. J. Asia*, 07(1): 87-100.
- Ucheya RE, Igweh JC (2010). Is a safe dose of aqueous extract of *Azadirachta indica* toxic on the histology of the rabbit liver? *Biosci. Biotechnol. Res. Asia*, 7(2): 741-744.
- Ucheya RE, Ochei UM (2011). Effects of aqueous extract of *Azadirachta indica* leaf on the maternal and neonatal growth in adult wistar rats. *Niger. J. Pharm.*, 44(1): 52-55.
- Ucheya RE, Ochei UM (2011). Is a combine therapy of aqueous extract of *Azadirachta indica* leaf (neem leaf) toxic to the histology of the rabbit cerebellum?. *Ann. Med. Health Res.*, 01(2): 237-245.
- Ucheya RE, Ochei UM (2011). Teratogenic effects of aqueous extract of *Azadirachta indica* leaf on the histology of the liver of neonatal wistar rats. *Niger. J. Pharm.*, 44(2): 50-55.
- Ucheya RE, Ochei UM (2011). The histological changes in rabbit kidney following a concomitant administration of aqueous extract of neem leaf (*Azadirachta indica*) and chloroquine sulphate. *African journal of Applied Zoology and environmental Biology*. MS No. 2011/035. (in press).
- Udeinya IJ, Brown N, Shu EN, Udeinya FI, Quakeyie I (2007). Fractions of antimalarial Neem-leaf extract have activities superior to chloroquine, and are antiretroviral, 98(7): 435-437.