

Case Reports

Contusion of the abdomen by the shaft of an animal-drawn charette in rural areas: The value of ultrasound in the care.

BADIANE S.M.¹, DIA A.A.², MANYAKA P.¹, MBODJ M.² and NDOYE O.³

¹Faculty of Health Sciences, University Gaston Berger of Saint-Louis, Po Box 234 Saint-Louis, Senegal.

²Faculty of Health Sciences, University of Thies, Po Box: 22254 Dakar-Ponty, Senegal.

³Faculty of Medicine Pharmaceutics and Odonto-Stomatology, Université Cheikh Anta Diop (UCAD), Po Box: 22254 Dakar-Ponty Senegal.

Accepted 02 November, 2013

Contusions of the abdomen by the shaft of an animal-drawn charette are rare, have banal looks but are potentially serious. In our context of practice, ultrasonography is the most accessible imaging modality, hence the interest to get the maximum of information. This study reports two (02) cases of contusion of the abdomen by the shaft of a horse-drawn charette. For these two cases in the absence of scanner, the ultrasound coupled with the clinical data allowed to notice a rupture of hollow organ, confirmed with laparotomy. These cases should draw the attention of practitioners located in rural areas on this type of contusion of the abdomen which constitutes a real emergency. In addition, in our context of practice a strict clinical examination and a thorough ultrasonography are crucial in the care that must be multidisciplinary.

Key words: Contusion of the abdomen, shaft of charette, Circular bruise, ultrasonography, hemoperitoneum, rupture of hollow organs.

INTRODUCTION

Contusions of the abdomen by the shaft of an animal-drawn charette are rare, have banal looks but are potentially serious. In our context of practice ultrasonography is the most accessible imaging modality; hence the interest to get the maximum of information since the scanner is usually unavailable. This paper report deals with two (02) cases of contusion of the abdomen by the shaft of a horse-drawn charette and the value of ultrasonography in the care.

OBSERVATIONS

Case N° 1

A Motorcyclist of 31 years sent to the ultrasonography room by the emergency department of the regional hospital

of Saint-Louis, for an abdominopelvic exploration due to a contusion of the abdomen by the shaft of an animal-drawn charette (Figure 1). The accident happened 4 hours ago. The hemodynamic condition was stable. The examination of the abdomen revealed:

- A contused wound with superficial circular ulceration of about 7 cm diameter above umbilical, slightly to the left. (Figure 2)

- A renitent arch on right latero-umbilical.

- A flexible but sensitive abdomen with signs of defense.

The abdomino-pelvic ultrasonography was performed using with a 3.5 MHz convex probe and a 7.5 MHz linear probe. We found:

- A peritoneal effusion of moderate abundance without any injury of solid organ detected (**Figure 3**).

- The presence of intestinal loops in the right latero-umbilical renitent mass, compatible with a disembowelment.

- On the admission to the unit, the median laparotomy revealed a split of the fourth duodenum with a rupture of the pancreatic uncus and a hemo-peritoneum (Figure 4). The postoperative sequels were healthy with no complications.

*Corresponding author. E-mail: semobadiane@yahoo.fr



Figure 1. Shaft of charette.

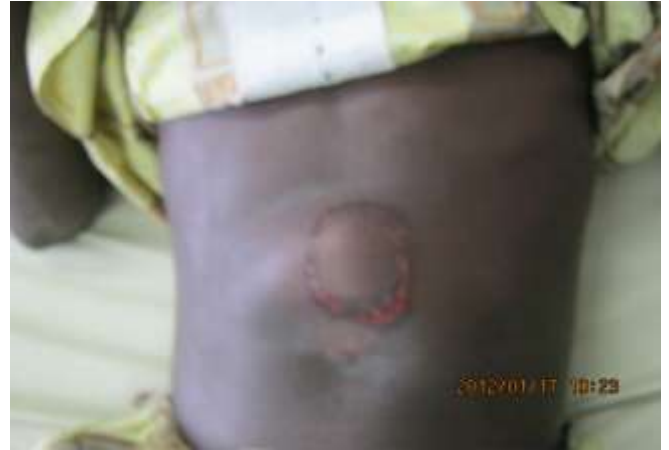

Figure 2. Superficial circular ulceration; case N°1

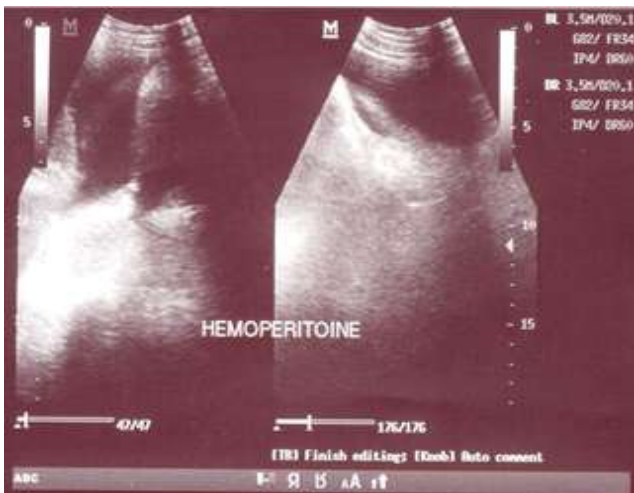


Figure 3. hemoperitoneum

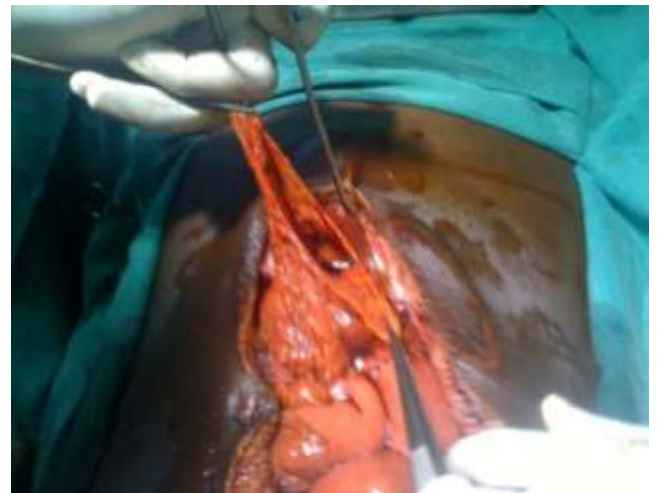

Figure 4. Preoperative image showing the duodenal wound

Case N° 2

A pedestrian of 26 years sent to the ultrasonography room by the emergency department of the regional hospital of Saint-Louis, for an abdomino-pelvic exploration due to a contusion of the abdomen by the shaft of an animal-drawn charette (Figure 1). The accident happened 24 hours ago.

The hemodynamic condition was unstable with a fall of tensional figures (80/50 mm Hg). The examination of the abdomen revealed: A blackish circular ecchymotic footprint of approximately 7 cm diameter on the left hypochondrium. (Figure 5) A sensitive and slightly distended abdomen with signs of defense. The abdomino-pelvic ultrasonography was performed using, with a 3.5 MHz convex probe and a 7.5 MHz linear probe. We found:

- A peritoneal effusion of moderate abundance without any injury of solid organ detected.

On the admission to the unit, the median laparotomy revealed a perforation of the jejunum and a hemoperitoneum. The patient died from postoperative sequels one day later.

DISCUSSION

As far as the contusions of the abdomen are concerned, the ruptures of hollow organs occupy the third position after the lesions of the spleen and liver. In order of frequency we can note the nuisance of the small intestine in 12% of the cases, the one of the stomach for 4% of the contusions and duodeno-pancreatic lesions in 3% of the cases. The lesions of the colon and the rectum occur in 4%

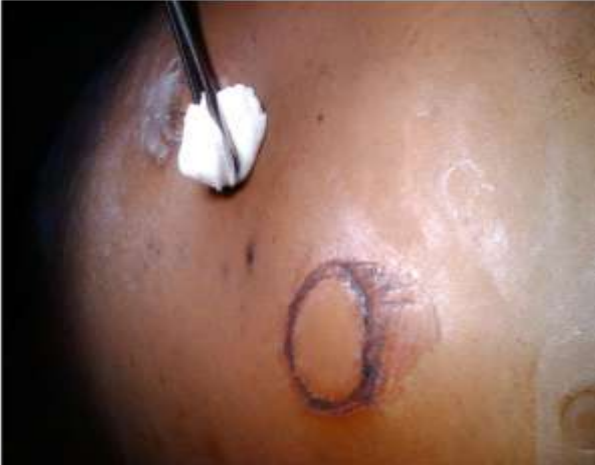

Figure 5. Circular bruise; case N°2

of the cases (Le Buquet, 1997; Flamming, 1997; Paillet, 1990). Their care must start early. Besides 30% of the ruptures of hollow organs are unknown and operated late (Barth et al., 2001) and the risk of mortality increases if the intervention is made beyond the 8th hour (Allen et al., 1998). This hypothesis is in perfect harmony with our observations.

In sub-Saharan Africa the lack of technical medico-surgical platform can probably impact on the care of these emergencies whose right management must be rigorous with ideally a multidisciplinary approach (Le Néel, 2001). About lesions of hollow organs, the scanner has a sensitivity of 84%, a specificity of 84% and a negative predictive value of 89% (Janzen et al., 1998). Thus it occupies an important place in the auscultation of the stable patient (Masso-Misse et al., 1996).

Ultrasonography is so far the most accessible method to explore an abdominal contusion. It has a sensitivity of 83% (IC 95 % of 36–100 %) for the search of an intraperitoneal effusion and a specificity of 98% (IC 95% of 93–100%) to eliminate it (Goodwin et al., 2001). The occurrence of these contusions by the shaft of charette can be seen as an accident of the public highway. However we found no similar cases reported in literature. This is a potentially serious trauma depending on the speed and the shape of the blunt object. The bruise and the circular ulceration in these two cases of perforation of hollow organ recalls the echymotic band- in crossbelt and belt during car accidents, present for 21% of the cases of intestinal lesion against 1.9% during its absence (Barth et al., 2001). Although the risk of lesion of hollow viscera in the mechanism of contusion that we report could not be discussed from two cases, it is a warning which should motivate a rigorous management of these types of accidents. Thus, our hypothesis is that: in front of these contusions when the scanner is not available, for a stable subject or not, ultrasonography is required. The arguments in favor of a rupture of hollow organ are:

- The bruise marked at the impact point
- Signs of peritoneal irritation
- The peritoneal effusion, without any lesion of solid organ detected on ultrasonography.

In this context, the surgical care must start early.

CONCLUSION

These cases should draw the attention of practitioners in sub-Saharan Africa on the contusions of the abdomen by the shaft of animal-drawn charette. These accidents of banal looks on the admission can be life-threatening. In front of the clinical and ultrasound arguments about hollow organ perforation, when the scanner is not available, the care should not have any delay. For this purpose ultrasonography is a significant contribution and its practice is to be popularized in rural Africa.

CONFLICTS OF INTEREST

Authors declare no conflicts of interest.

REFERENCES

- Allen GS, Moore FA, Cox CS, Wilson JT, Cohn JM, Duke JH (1998). Hollow visceral injury and blunt trauma. *J. Trauma Acute Care Surg.* 45 (1): 69-77.
- Barth X, Guillon F, Le Néel J-C (2001). Diagnostic methods in bruises. *Arnette*, 2001.
- Flaming J (1997). Abdominal trauma: diagnosis and what to do in an emergency to Rober Debré Hospital CHU de Reims. *Impact Int.* October, 287: 163-170.
- Goodwin H, Holmes J, Wisner D (2001). Abdominal ultrasound examination in pregnant blunt trauma patients. *J Trauma* 50: 689-94.
- Janzen DL, Zwirowich CV, Breen DJ, Nagy A (1998). Diagnostic accuracy of helical CT for detection of blunt bowel and mesenteric injuries. *Clinical radiology.* 53 (3): 193-7.
- The J Buquet, Letessier E, Grenier F, Armstrong O, Lasserre P. The lesions of the digestive tract in blunt abdominal trauma. *Ann. Med.* 57 (7): 811.
- The Néel JC (2001). Traumatismes the abdomen: report to the French 103rd Congress of Surgery, Paris, 4-6 October 2001. Reuil-Malmaison: Arnette, 2001 [cited 21 March 2013].
- Masso-Misse P, Essomba A, Takongmo S (1996). Hemoperitoneum and contusion of the abdomen: contribution of ultrasound in strategiedecisionnelle a stable hemodynamic status. *Black Médecined'Afrique.* 43 (2).
- Mulch HL, Brissiaud AD, Jancovici R, Vicq P (1990). Bruises and wounds of the abdomen. *Encyclical. Med. Chir.* (Paris), Stomach Intestine. 9007: A10.