

Full Length Research Paper

Anti-ulcerogenic properties of methanolic root extract of *Piliostigma reticulatum* (DC) Hoechst (Syn. *Bauhinia reticulata* DC) -Leguminosae in rats

Salawu, O. A.¹, Tijani, A. Y.^{1*}, Obidike, I. C.¹, Rafindadi, H. A.² and Emeje, M.³¹Department of Pharmacology and Toxicology, National Institute for Pharmaceutical Research and Development (NIPRD), Idu, Abuja, Nigeria.²Department of Pathology, Ahmadu Bello University, Zaria, Nigeria.³Department of Pharmaceutical Technology and Raw material, Development National Institute for Pharmaceutical Research and Development (NIPRD), Idu, Abuja, Nigeria.

Accepted 22 October, 2011

Piliostigma reticulatum (DC) Hoechst (Syn. *Bauhinia reticulata* DC) - Leguminosae is a medicinal plant used in folk medicine against peptic ulcer. Effects of its methanolic root extract on basal gastric acid secretion and on ethanol and piroxicam-induced ulceration in rats were evaluated in this study. The methanolic extract evoked a dose-dependent decrease in gastric secretion and significantly ($P < 0.05$) reduced ulcer index induced by ethanol (27.3 - 63.60%) and piroxicam (6.25 - 68.75%). Histopathological studies of rat stomach tissues from control and extract-treated groups at 100 mg/kg b.w extract showed inflammation characterized by eosinophil infiltration, while the extract treated groups at 200 and 400 mg/kg b.w showed no obvious lesions and this is comparable to misoprostol (400 mg/kg b.w) treated group. These findings indicate the cytoprotective effects of the extract against ulceration and thus justify the folkloric uses of the plant in the symptomatic management of peptic ulcer.

Key words: *Piliostigma reticulatum*, leguminosae, anti-ulcer activity, cytoprotective.

INTRODUCTION

Peptic ulcers develop due to excessive secretion of acid and pepsin, a diminished mucosal defence or a combination of these 2 abnormalities. Predisposing factors of gastric ulcer include *Helicobacter pylori* infection, non-steroidal anti-inflammatory drugs, cigarette smoking, stress, alcohol and chronic pancreatitis (Tariq et al., 1986). Symptoms of peptic ulcer disease include epigastric pain of a burning or gnawing nature (postprandial pain and pain relieved by food or antacids), nausea, vomiting, belching and bloating. Complications of protracted untreated cases include anaemia caused by Gastro-intestinal blood loss, weight loss attributed to a reduced appetite caused by fear of pain and vomiting associated with a gastric ulcer or pyloric stenosis and

mucosal perforation (Hunt et al., 2006). Current management of peptic ulcer disease involves the use of proton pump inhibitor (PPI), an antibiotic and metronidazole (triple therapy) (Malfertheiner, 2002). High cost of treatment and unbearable side effects of the conventional anti-ulcer drugs leads to poor compliance and resultant treatment failures. There is, therefore, the need to develop safe, effective and affordable alternatives in the symptomatic management of peptic ulcer disease. *Piliostigma reticulatum* (DC) Hoechst (Syn. *Bauhinia reticulata* DC) (Leguminosae) is an evergreen shrub or small tree common in the fallows. It is found mostly in the northern part of Nigeria (Le Hauerou, 1980). The bark decoction has been used traditionally to treat stomach pains and indigestion, while the powdered bark is applied as a dressing for wounds and skin ulcers (Burkill, 1995). The root and stem bark decoction are used for the management of diarrhea and stomach ulcer.

*Corresponding author. E-mail ade_dat@yahoo.com

Tea from the leaves is given to treat cold. Previous studies in our laboratory have shown that the methanolic extract of *P. reticulatum* has remarkable anti-diarrhoeal effect (Salawu et al., 2007). The aim of this study was to investigate the effects of the methanolic root extract of *P. reticulatum* against ethanol and piroxicam-induced ulceration in rats and on basal gastric acid secretion.

MATERIALS AND METHODS

Chemicals and Equipment

Ethanol (H.E. Chemicals, UK), cimetidine (Sigma, USA), piroxicam (Sigma, USA), misoprosol (Pfizer, UK), ketamine (Rotex Medica, Germany), analar grade sodium hydroxide (BDH, England), Beckman GS-15 centrifuge, corning pH meter (England), GFL shaker (No. 3017 Gesell Schafffur Labor technik MbH, Burgwedel, Germany).

Animals

Healthy adult male and female wistar albino rats weighing 250 - 300 g obtained from the animal facility centre of national institute for pharmaceutical research and development (NIPRD), Idu, Abuja were used. They were housed in stainless steel cages at a temperature of $23 \pm 2^\circ\text{C}$ and $55 \pm 15\%$ humidity, with a 12 h light/12 h dark cycle and fed standard rodent diet and water *ad libitum*. The rats were fasted overnight before the study. All experiments performed on laboratory animals in this study followed the "Principles of laboratory animal care" (NIH Publication No. 85, Rev, 1985).

Plant material

P. reticulatum roots were collected from Suleja, Niger state, Nigeria. It was identified by Mallam Muazzam of the medicinal plant research and traditional medicine (MPR&TM) department of national institute for pharmaceutical research and development (NIPRD), Idu, Abuja and voucher specimen (NIPRD/H/6181) was prepared and deposited at the department's herbarium for future reference.

Preparation of plant material (Extract)

The plant's root were cleaned, cut into pieces, air-dried for 10 days and crushed into a coarse powder. The powdered root (200 g) was cold macerated with 1.0 L of methanol for 18 h with constant shaking using a GFL shaker. The resultant mixture was filtered using Whatman filter paper No. 1 (Cat. No. 100125) and the filtrate concentrated by rotary evaporation at 45°C . The filtrate was dried on steam bath yielding 8.66% on dry weight basis. The dried sample was stored in specimen bottle and kept in refrigerator until required for use. Drugs and extract were administered orally throughout the study via stainless steel oral canula.

Ethanol-induced gastric ulceration

Twenty four hours fasted rats were randomized into 7 groups of 5 rats each. Group 1 rats served as the positive control and received

10 ml normal saline/kg body weight each. Group 2 rats served as the negative control and were pretreated with 10 ml normal saline/kg body weight while rats of Groups 3 to 6 were treated with methanolic extract of *P. reticulatum* root at doses of 50, 100, 200 and 400 mg /kg body weight orally respectively and Group 7 rats were each given 200 mg cimetidine/kg body weight. 30 min later, 1 ml of absolute ethanol was administered to all the rats except rats in group 1. One hour after ethanol administration, the rats were sacrificed under chloroform anaesthesia. The stomachs were removed, opened along the greater curvature and rinsed. They were then examined macroscopically with a hand lens and the ulcer lesions (elongated black- red lines parallel to the long axis of the stomach) observed were scored according to severity (Nwafor et al., 1996) as follows:

- 0 = No ulcer
- 1 = Haemorrhagic and slightly dispersed ulcers less than 2 mm length
- 2 = 1 ulcer, haemorrhagic and up to 5 mm length
- 3 = More than 1 ulcer, each up to 5 mm length
- 4 = 1 ulcer above 5 mm in length
- 5 = More than 1 ulcer above 5 mm in length.

Ulcer index (UI) defined as the severity of damage caused by an ulcer inducing agent was then calculated using the formula:

$$\text{UI} = \text{UA/TA} \times 100 \text{ where}$$

UA = Ulcer area of stomach mucosa

TA = Total area of stomach mucosa

Preventive ratio (PR) defined as the degree of protection offered by a treatment against ulcer causing agent was calculated using the formula:

$$\text{PR} = \left[\frac{(\text{MUI control} - \text{MUI treated})}{\text{MUI control}} \right] \times 100 \text{ where}$$

MUI = Mean ulcer index.

Piroxicam-induced gastric ulceration

The procedure used in inducing gastric ulceration in rats via ethanol administration was repeated using piroxicam (10 mg/kg) dissolved in 1% tragacanth solution as ulcerogen. Twenty four hours fasted rats were randomized into 7 groups of 5 rats each. Group 1 served as the normal control and received 10 ml normal saline/kg body weight while rats of Groups 2 to 5 rats were treated orally with 50, 100, 200 and 400 mg methanolic extracts of *P. reticulatum*/kg body weight orally respectively and Group 7 rats were given 200 mg misoprostol/kg body weight administered as a suspension in 0.2% w/v tragacanth solution. Thirty minutes later, all the rats were treated with piroxicam except rats in group 1. Six hours after piroxicam administration, the rats in all the groups were sacrificed under chloroform inhalation. The stomachs were excised, opened along the greater curvature and the ulcer lesions observed, scored and fixed in 10% formal saline solution.

Histopathological studies

The stomach tissues were removed from the rats and fixed in 10% formal saline for at least 48 h. These were then processed routinely and the tissues were embedded in paraffin wax. Histological sections were cut at 5 - 6 μm and stained with routine haematoxylin and eosin (HE). These were then examined by a consultant histopathologist. The lesions observed were assessed for the following, mucosal atrophy, the presence of inflammatory cells in the wall, oesinophils, lymphocytes and

Table 1. Effect of methanolic extracts of the roots of *P. reticulatum* on ethanol-induced lesions in rats.

Treatment	Dose(mg/kg)	Mean ulcer index	Preventive ratio (%)
Normal saline 10 ml/kg	-	0.00 ± 0.00	100.00
Ethanol 1 ml	-	4.4 ± 0.36	0.00
Extract + ethanol	50	3.2 ± 0.18	27.3
Extract + ethanol	100	2.2 ± 0.33*	50.0
Extract + ethanol	200	1.8 ± 0.34*	59.1
Extract + ethanol	400	1.6 ± 0.46*	63.6
Cimetidine + ethanol	200	0.42 ± 0.01**	90.45

* Significantly different from control at $P < 0.05$ **Highly significantly different from control at $P < 0.01$.

plasma cells. These were graded according to mild (+), moderate (++) or severe (+++). Photomicrographs of representative lesions were taken at various magnifications.

Gastric acid secretory study

This study was carried out using the method of Alemika and Oluwole (1991). 25 rats were randomly divided into 5 groups of 5 rats per group. Rats of the control group (Group 1) received 5 ml of normal saline and served as the control while rats of groups 2 to 4 received extract doses of 100, 200 and 400 mg/kg body weight respectively daily for 15 days. During treatment period, the rats were allowed free access to feed and water. On the 16th day, each rat was anaesthetized with 25 mg ketamine/kg body weight intraperitoneally. The abdomen was cut open by a small midline incision of 4 cm below the xiphoid process. The stomach was exposed and the pylorus and lower oesophagus ligated. The stomachs were placed carefully back into the visceral cavity and the abdominal wall closed by interrupted sutures.

The rats were then killed after 3 h by chloroform inhalation. The stomach was perfused with 1.0 ml normal saline and the gastric contents were collected in a graduated centrifuge tube, centrifuged at 2500 rpm for 10 min. The effluent was titrated to pH 7.0 against standardized 0.01 M NaOH solution until neutral point was attained using pH meter. The total volume of NaOH used corresponds to total acidity obtained (Hawk, 1965).

Statistical analysis

The results were expressed in terms of mean ± SEM. Experimental data were analysed using one way ANOVA followed by student's t-test. P values less than 0.05 were considered statistically significant.

RESULTS

Effects of the extract on ethanol-induced gastric ulceration

Ethanol treatment produced haemorrhagic gastric lesions mainly in the glandular segment of the stomach mucosa. Methanolic extracts of roots of *P. reticulatum* reduced gastric lesion as evident from significant reduction of

ulcer index at 200 and 400 mg/kg ($P < 0.05$) when compared to the control group. Cimetidine however, showed highly significant ($P < 0.01$) gastro-protective effect against haemorrhagic lesions induced by ethanol as evident from ulcer index and ulcer grading (Table 1).

Effect of the extract on piroxicam-induced gastric ulceration

Piroxicam treatment produced focal haemorrhagic gastric lesions and inflammation of the stomach mucosa. Treatment with *P. reticulatum* extract reduced gastric lesion significantly ($P < 0.05$) at 200 and 400 mg/kg, while misoprostol completely protected the rats against gastric lesion as evident from highly significant ($P < 0.05$) reduction of ulcer index and ulcer grading when compared to control (Table 2).

Histopathology

Moderate mucosal atrophy was noted in the groups that received piroxicam alone and 50 mg extract/kg b.w. These were accompanied by moderate infiltration of the stomach wall by lymphoplasma cells and oesinophils. In the 100 and 200 mg extract/kg b.w - treated groups, only mild mucosal atrophy and mild number of oesinophils and lymphoplasma cells were observed. In the 400 mg extract/kg b.w, the misoprostol and the normal saline only - treated groups, no remarkable changes were observed (Table 3 and Figures 1 - 3).

Effects of methanolic extract doses of *Piliostigma reticulatum* on gastric acid secretion

Methanolic extract doses of *P. reticulatum* at 100, 200 and 400 mg/kg body weight significantly reduced basal acid secretion in a dose-dependent manner in treated

Table 2. Effect of the root extract of *P. reticulatum* on piroxicam-induced ulceration in rats.

Treatment	Dose (mg/kg)	Mean ulcer index	Preventive ratio (%)
Normal saline 10 ml/kg	-	0.00 ± 0.00	100
Normal saline + Piroxicam	10	3.2 ± 0.34	0
Extract + Piroxicam	50	3.2 ± 0.34	6.25
Extract + Piroxicam	100	3.0 ± 0.85	43.75
Extract + Piroxicam	200	1.4 ± 0.2*	56.25
Extract + Piroxicam	400	1.0 ± 0.28*	68.75
Misoprostol + iroxicam	200	0 ± 0.00**	100

* Significantly different from control at P < 0.05

** Highly Significantly different from control at P < 0.01.

Table 3. Results of histopathology examinations.

Treatment/dose	(mg/kg)	Intestinal changes
Normal saline 10 ml/kg	-	Unremarkable mucosal changes
Piroxicam	10	Moderate mucosal atrophy noted, moderate infiltration by eosinophils and lymphoplasma cells of the wall.
Extract + piroxicam	50	Moderate mucosal atrophy; moderate number of lymphoplasma cells in the wall
Extract + piroxicam	100	Mild mucosal atrophy; mild number of eosinophils and lymphoplasma cells in the wall.
Extract + piroxicam	200	Mild mucosal atrophy; mild number of eosinophils and lymphoplasma cells in the wall.
Extract + piroxicam	400	Unremarkable mucosal changes
Misoprostol + piroxicam	200	Unremarkable mucosal changes

* Significantly different from control at P < 0.05

** Highly Significantly different from control at P < 0.01.

rats, when compared to the untreated group.

DISCUSSION

The methanolic root extract of *P. reticulatum* showed significantly dose-dependent anti-ulcer activity against experimentally - induced gastric ulcer models used in this study.

Ethanol-induced ulcers which is predominantly in the glandular part of stomach has been reported to stimulate the formation of leukotriene C₄ (LTC₄) resulting in the damage of rat gastric mucosa (Cho et al., 1987). Chronic alcohol misuse is associated with significantly reduced capacity for prostaglandin synthesis in gastric mucosa (Bode et al., 1996). In the rat gastric mucosa, inflammation, erosion and necrosis elicited by exogenous LTC₄ resemble those produced by ethanol (Szabo et al., 1985). Other studies have indicated that an alcohol dependent increase in the production of leukotrienes -compounds produced by the immune system that cause allergic and inflammatory reactions might also contribute to the development of alcohol-induced mucosa injury (Bode and Bode, 1992). Ethanol also produces mucosa damage by

direct necrotizing action which in turn reduces defensive factors, secretion of bicarbonate and production of mucus (Rujjanawate et al., 2005). The protective effect of extract against ethanol-induced gastric lesions may in part be due to reduced leukotriene activity produced.

Piroxicam, a non-steroidal anti-inflammatory agent (NSAID) acts principally by inhibiting activity of cyclo-oxygenase enzyme (COX), non-selectively, leading to a decrease in the production of prostaglandins (PGs) (Hiruma-Lima et al., 2006). Selective inhibition of cyclo-oxygenase pathway increases the level of Leukotrienes in gastric mucosa, which has a potent action on mucosal vasculature leading to inflammation and pain (Kapui et al., 1993). Inhibition of cyclo-oxygenase has also been observed to potentiate the gastric acid secretion effects of histamine (Reeves and Stables, 1985). Prostaglandin E₂ (PGE₂) produced by the gastric mucosa, inhibits secretion of hydrochloric acid and stimulates secretion of mucus and bicarbonate conferring cytoprotective effect on the mucosal layer. The impairment of mucosal defense by piroxicam allows gastric acid to elicit direct erosion of mucosal layer. The extract may thus be acting through prostaglandin-mediated effect as it has been pro-



Figure 1. Photomicrograph showing gastric mucosa with mild atrophy (HE X 40).

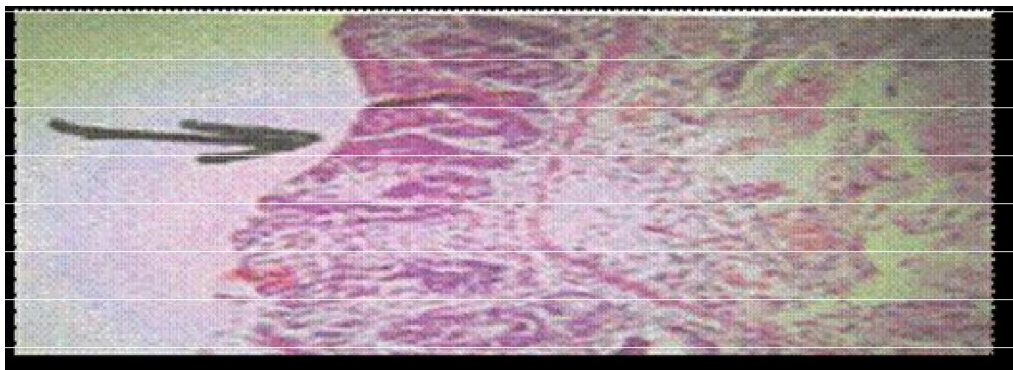


Figure 2. Photomicrograph showing gastric mucosa with moderate atrophy. There is moderate inflammatory cell infiltrate in the mucosa and submucosa (HE X 40).



Figure 3. High power of the mucosa and submucosa showing eosinophils and lymphoplasm cells HE X 100).

posed that non-prostanoids protects gastric mucosa through the mobilization of endogenous prostaglandins (Konturek et al., 1987). Misoprostol a synthetic analogue of prostaglandin E₁ completely protected the mucosal layer against piroxicam-induced lceration. Histopathologi-

cal studies further confirmed the extract's mucosal protective effect in that it inhibited piroxicam - induced mucosal atrophy, infiltration by eosinophils and lymphoplasm cells in the wall. The efficacy of the gastro-histoprotective effects of methanolic extract of *P. reticulatum*

Table 4. Effects of the root extract of *P. reticulatum* on basal gastric acid secretion.

Treatment	Dose(mg/kg)	Mean Gastric Acid Output (x 10 ⁻³ NHCl)	% Reduction
Normal saline 5 ml/kg	-	10.4 ± 1.41	0
Extract	100	5.02 ± 1.88*	51.73
Extract	200	3.60 ± 1.66*	65.38
Extract	400	0.74 ± 0.41**	92.88

* Significantly different from control at P < 0.05

** Highly Significantly different from control at P < 0.01.

against the piroxicam - induced gastric mucosa atrophy, was comparable to that of misoprostol. *P. reticulatum* methanolic root extract anti-secretory activity is evident from its significant reduction in volume of gastric juice in treated rats when compared to the control. The extract significantly reduced the effect of accumulated gastric juice believed to be responsible for ulceration in pyloric ligated rats (Bigoniya et al., 2006). Reflux effect in addition to acid secretion has also been suggested to play an important role in the formation of ulcer in pyloric ligated rats (Goswami et al., 1997). The extract probably stimulated the growth of gastric mucosa epithelial cells resulting in the observed cytoprotective effects in rats. The plant, *P. reticulatum* has been reported to possess tannins, saponins and sterols as phytochemical constituents (Salawu et al., 2007). Tannins are known to affect the integrity of mucosa membrane. Tannins being astringent may precipitate micro-proteins in the site of ulcer thus preventing absorption of toxic substances by forming a protective layer and resisting the mucous layer against the attack of proteolytic enzymes (Bigoniya et al., 2006). Saponins protect stomach mucosa from acid by selectively inhibiting prostaglandin F₂ (PGF₂), which causes vasoconstriction of mucosal blood vessels (Aguwa and Okunji, 1986). Presence of these phytochemical components may also contribute to its protective effect by maintaining an efficient gastric mucosa microvascular supply. In conclusion, the reported results have validated the folkloric use of *P. reticulatum* root in the therapy of gastric ulcer disease. In particular, the present findings have pointed out the possible gastric cytoprotective and anti-secretory effects of the extract.

REFERENCES

- Aguwa CN, Okunji CO (1986) Gastrointestinal studies of *Pyrenacantha stanudii* leaf extracts. J. Ethnopharmacol. 15: 45-55.
- Alemika TOE, Olurode FS (1991): An investigation of the potential of *Boswellia dalzielii* and *Commiphora kerstingi* in the treatment of peptic ulcer. West Afr. J. Pharmacol. Drug Res. 9 (10): 91-94.
- Bigoniya P, Rana AC, Agrawal GP (2006): Evaluation of the anti-ulcer activity of *Wrightia tinctoria* bark extract in induced acute gastric ulcers in rat. Nig. J. Nat. Prod. Med. 10: 36-40.
- Bode JC, Bode C (1992) Alcohol malnutrition and the gastrointestinal tract. In: Watson RR, Watzl B, eds. Nutrition and Alcohol. Boca Raton: CRC Press: 403-28
- Bode C, Maute G, Bode JC (1996) Prostaglandin E2 and prostaglandin F2 biosynthesis in human gastric mucosa: Effect of chronic alcohol misuse. Gut 39(3):348-352.
- Burkill HM (1995). The Useful Plants of West Tropical Africa. 2nd Edition. Volume 3, Families J-L. Royal Botanic Gardens, Kew, Richmond, United Kingdom. 857
- Cho CH, Ogle CW, Sevilla EL (1987). The Protective Effects of Sulphasalazine Against Ethanol-induced Gastric Damage in Rats. Br J. Pharmacol, 92 (1), 31-37.
- Eastwood GL (1997): Is smoking still important in the pathogenesis of peptic ulcer disease? J. Clin. Gastroenterol. 25 (I):51-7.
- Goswami S, Jain S, Santani D (1997). Evaluation of the Effects of Nicorandil on Experimentally Induced Gastric Ulcers) J. Pharmacy Pharmacol 49 : 195-199
- Hawk H. (1965): In: Hawk's Physiological Chemistry, Oster BL (ed), 14th ed, McGraw-Hill Book Co., New York 483.
- Hinima-Lima TR, Calvo CM, Rodrigues FDP, Andarde W, Vilegas RA, Brito MS (2006): Anti-ulcerogenic activity of *Alchornea castaneaefolia*: effects on somastostatin, gastrin and prostaglandin. J. Ethnopharmacol 104 : 215-224.
- Hunt HR, Ireneus T, Padol YY (2006) Peptic Ulcer Disease Today. Nature Clinical Practice: Gastroenterology and Hepatology 3(2) : 80-85.
- Kapui Z, Boer K, Rosza I, Blasko GY, Hermeez I (1993). Investigation of indomethacin-induced gastric ulcer in rats. Arzneim-Forsch/ Drug Res. 43 : 767-771.
- Konturek SJ, Redechi T, Piastuchi L, Brozowski T, Drozdowicz D (1987). Gastrocytoprotection by colloidal bismuthsubcitrate (De-Nol) and sucralfate. Role of endogenous prostaglandins. Gut 28, Pp 201-205.
- Le Hauerou HN (1980). The role of browse in the Sahelian and Sudanian zones. HN. Le Hauerou, ed; pp 55-82.
- Malfertheiner P (2002). Current Concepts in the Management of Helicobacter pylori infection- the Maastricht 2-2000. Consensus Report. Aliment. Pharmacol. Ther. 16: 167-180.
- Nwafor KD, Effraim KD, Jacks TW (1996). Gastro protective effects of aqueous extract of *Khaya senegalensis* bark on Indomethacin-induced ulceration in rats. West Afr. J. Pharmacol Drug Research, 12: 46-50.
- Reeves JJ, Stables R (1985). Effects of indomethacin, piroxicam and selected prostanoids on gastric acid secretion by the rat isolated gastric mucosa, Br. J. Pharmacol., 86: 677-684.
- Ruijanawate C, Kanjanapothi D, Amornlerdpison, Pojanagaroon S (2005). Anti-gastric ulcer effect of *Kaempferia parviflora*, J. Ethnopharmacol. 102 : 120-122
- Salawu OA, Tijani AY, Obidike IC (2007). Anti-diarrhoeal activity of methanolic root extract of *Piliostigma reticulatum*. J. Phytomed. Therap. 12 : 44-50.
- Szabo S, Trier JS, Brown A, Schnoor J (1985). Early vascular injury and increased vascular permeability in gastric mucosal injury caused by ethanol in the rat. Gastroenterology 88: 228-236.

Tariq M, Parmar NS, Al Yahya MA, Ageel AM, Al Said MS. (1986)
Evaluation of Aloe vera leaf exudate and gel from gastric and
duodenal anti-ulcer activity *Fitoterapia* 57: 380-383.