

Full Length Research Paper

Antilipidemic effect of chitosan against experimentally induced myocardial infarction in rats

R. Sivakumar¹, R. Rajesh¹, S. Buddhan¹, R. Jeyakumar¹, D. Rajaprabhu¹, B. Ganesan^{1,2}, R. Anandan^{2*}

¹Vinayaka Missions University, Ariyanoor, Salem-636308, Tamil Nadu, India.

²Biochemistry and Nutrition Division, Central Institute of Fisheries Technology, Matsyapuri (PO), Cochin-682029, India.

Accepted 16 November, 2018

Myocardial infarction is a major public health concern and the leading cause of death all over the world. A better understanding of the processes involved in myocardial infarction has stimulated the search for new drugs, which could limit the myocardial injury. In the present study, an attempt has been made to examine the preventive effects of chitosan, a marine polysaccharide, on isoprenaline-induced myocardial infarction in male albino rats, an animal model for myocardial infarction of human beings. Dietary supplementation of 2% chitosan for 60 days significantly reduced the isoprenaline-induced elevation in the levels of plasma diagnostic marker enzymes and maintained the level of myocardial taurine content at near normal. It exerted significant antilipidemic effect against isoprenaline-induced myocardial infarction by maintaining the level of cholesterol, triglycerides, free fatty acids and phospholipids in plasma and heart tissue at the levels comparable to that of control animals. Also chitosan supplementation significantly prevented isoprenaline-induced lipid peroxidation and maintained the reduced glutathione content in plasma and heart tissue at near normalcy. The results of the present investigation indicated that the cardioprotective effect of chitosan might be ascribable to the hypolipidemic property and/or antioxidant nature of chitosan.

Key words: Isoprenaline, diagnostic marker enzymes, taurine, lipids, lipid peroxidation, reduced glutathione.

INTRODUCTION

Globally, myocardial infarction is a major public health concern and the leading cause of mortality. Developing countries like India are also struggling to manage the impact of myocardial infarction along with the growing burden of obesity, Type II diabetes and hypertension (Tilak-Jain and Devasagayam, 2006). In recent years, an increasing number of young Indians are succumbing to myocardial infarction due to unusual risk factors characterized by high triglycerides, low High Density Lipoproteins (HDL), glucose intolerance, insulin resistance, abdominal obesity and increased lipoprotein (a) levels (Farvin et al., 2006; Packard et al., 2005). The major abnormalities noticed following myocardial infarction are lipidemia, peroxidation and loss of plasma membrane integrity (Farvin et al., 2004). A better understanding of

the processes involved in myocardial infarction has stimulated the search for new drugs, which could limit the myocardial injury.

Natural products have been the starting point for the discovery of many important modern drugs. This fact has led to chemical and pharmacological investigations and general biological screening programs for natural products all over the world (Nagle and Zhou, 2006). In recent times, there is a lot of interest in drugs from marine origin with potential benefits. Chitosan is one of the most abundant naturally occurring polysaccharides present in the shellfish, clams, krill, oysters, squid, fungi and insects (Cardenas et al., 2001). It is a polymer of - (1-4)-D-gluco-samine and it is chemically similar to that of the plant fiber, cellulose. It carries a positive charge on the acetyl remnants and when solubilized in an acid environment, the chitosan polymers bind to negatively charged molecules such as fats and lipids. Experimental studies have shown that it behaves as a fibre in the gastroin-

*Corresponding author. E-mail: kranandan@email.com

testinal tract and increases the amount fat eliminated in the stool (van Bennekum et al., 2005; Sumiyoshi and Kimura, 2006).

Reports by Sumiyoshi and Kimura (2006) and Xu et al. (2007) have shown that the dietary supplementation of chitosan is capable of ameliorating high fat diet-induced hyperlipidemia in experimental animals. It has been reported to possess antilipidemic (Santhosh et al., 2006), antioxidant (Xie et al., 2001) and membrane stabilizing properties (Filipovic-Grcic et al., 2001). Earlier Anandan et al. (2004) reported the antiulcer effect of chitosan against HCl-ethanol mixture induced peptic ulcer in rats. Recently, it has attracted more attention as a biomedical material, owing to its unique biological activities, which include antitumor, immunoenhancing effects and antibacterial activity in combination with its non-toxic nature (Kim et al., 2003). Chitosan has profound applications in the fields of clarification and purification, chromatography, paper and textiles, photography, food and nutrition, agriculture, pharmaceutical and medical, cosmetics, biodegradable membranes and biotechnology (Senel and McClure, 2004). Though the beneficial effects of chitosan have been extensively studied, the cardioprotective effect of chitosan in experimentally induced myocardial infarction condition has not yet been explored.

Isoprenaline [L- β - (3,4-dihydroxyphenyl) - isopropylaminoethanolhydrochloride], a β -adrenergic agonist has been reported to cause oxidative stress in the myocardium, which results in infarct like necrosis of heart muscle similar those observed in myocardial infarction in human beings (Farvin et al., 2004; Anandan et al., 2007). Isoprenaline induces myocardial necrosis by a multiple step mechanism. Injection of isoprenaline into rats increases the low-density lipoproteins (LDL) cholesterol level in the blood, which in turn leads to the build up of harmful deposits in the arteries, and thus favors myocardial infarction (Rajadurai and Prince, 2006; Farvin et al., 2006). Increased lipolysis and peroxidation of endogenous lipids also play a major role in the cytotoxic action of isoprenaline (Padma et al., 2006). A considerable body of clinical and experimental evidence now exists suggesting the involvement of free radical mediated oxidative process in the pathogenesis of isoprenaline-induced myocardial infarction (Shiny et al., 2005; Anandan et al., 2003; Anandan et al., 2007).

In the present study, we have attempted to assess the cardioprotective effect of chitosan against isoprenaline-induced myocardial infarction in male albino rats by virtue of its antioxidant, hypolipidemic and membrane stabilizing properties.

MATERIALS AND METHODS

Chemicals

Epinephrine, isoprenaline, taurine, tetraethoxy propane and cholesterol were obtained from M/s. Sigma Chemical Company, St.

Louis. MO, USA. Chitosan (Mw 750000 Da; viscosity 8cps; deacetylation rate 85 - 87%; purity 98.6%) used in experiment was a kind gift from Dr. T. K. Thankkappan, Principal Scientist, Central Institute of Fisheries Technology, Cochin, India All the other chemicals used were of analytical grade.

Animals

Male Wistar strain albino rats, weighing 120 - 150 g were selected for the study. The animals were housed individually in polypropylene cages under hygienic and standard environmental conditions (28 \pm 2°C, humidity 60 - 70%, 12 h light/dark cycle). The animals were allowed a standard diet [M/s Sai Feeds, Bangalore, India] and water *ad libitum*. The experiment was carried out as per the guidelines of Committee for the Purpose of Control and Supervision of Experiments on Animals (CPCSEA), New Delhi, India.

Experimental protocol

Seven days after acclimatization, the animals were divided into four groups of 6 rats each. Group I rats were normal controls given only standard diet. Group I and Group III animals were fed on standard diet with corn starch at 2% level for 60 days and Group II and Group IV animals were fed on standard diet with added chitosan at 2% level for the same period. After 60 days feeding, the Group III and Group IV animals were intraperitoneally (i.p.) injected with isoprenaline [11 mg (dissolved in physiological saline)/100g body weight per day for 2 days] for the induction of myocardial infarction (Anandan et al., 2003). Control animals (Group I and Group II) were i.p. injected with physiological saline alone for 2 days.

At the end of the experimental period, the animals were killed and blood was collected using heparin as anticoagulant. The plasma separated was used for the determination of diagnostic marker enzymes, alanine aminotransferase [EC 2.6.1.2] (ALT) (Mohur and Cook, 1957), aspartate aminotransferase [EC 2.6.1.1] (AST) (Mohur and Cook, 1957), lactate dehydrogenase [EC 1.1.1.27] (LDH) (King, 1965) and creatine phosphokinase [EC 2.7.3.2] (CPK) (Okinaka et al., 1961). High-density lipoprotein (HDL) and low-density lipo-protein (LDL) fractions were separated from plasma according to the dual precipitation technique (Burstein and Scholnick, 1972). The heart tissue was excised immediately and thoroughly washed with physiological saline. Taurine content in the heart tissue was determined by method of Ishida et al. (1981) using Shimadzu 10AS Amino Acid Analyzer.

The cholesterol, triglycerides, free fatty acids and phospholipids contents in heart tissue were determined after extracting total lipids according to the method of Folch et al. (1957). Cholesterol was estimated by the method of Parekh and Jung (1970) and the triglycerides were determined by the method of Rice (1970). The method described by Horn and Menahan (1981) was followed for the estimation of free fatty acids, and the phospholipids were estimated by the method of Fiske and Subbarow (1925) as inorganic phosphorous liberated after perchloric acid digestion (Bartlette, 1959). Lipid peroxide content in plasma and heart tissue was determined by the thiobarbituric acid (TBA) reaction as described by Okhawa et al. (1979).

Statistical analysis

Results are expressed as mean \pm SD. Multiple comparisons of the significant ANOVA were performed by Tukey's multiple comparison test. A P value <0.05 was considered as statistically significant. All data were analyzed with the aid of statistical package program SPSS 10.0 for Windows.

Table 1. Levels of alanine aminotransferase (ALT), aspartate aminotransferase (AST), lactate dehydrogenase (LDH), and creatine phosphokinase (CPK) in plasma of normal and experimental groups of rats.

Groups	Group I Control	Group II Chitosan	Group III Isoprenaline	Group IV Chitosan + Isoprenaline
ALT	89.2 ± 6.71	82.5 ± 6.19	337 ± 24.6 ^{a,b}	108 ± 9.18 ^c
AST	95.4 ± 6.92	89.7 ± 7.11	345 ± 27.9 ^{a,b}	120 ± 9.63 ^c
LDH	143 ± 8.67	132 ± 8.25	388 ± 24.3 ^{a,b}	164 ± 10.9 ^{c,d}
CPK	98.7 ± 7.36	103 ± 6.97	322 ± 18.0 ^{a,b}	118 ± 7.86 ^c

Results are mean ± SD for 6 animals. Group I and Group III animals, fed standard diet with corn starch at 2% level for 60 days. Group II and Group IV, fed standard diet with added chitosan at 2% level for 60 days. Group III and Group IV animals, intraperitoneally (i.p.) injected with isoprenaline [11mg (dissolved in physiological saline)/100g body weight per day for 2 days] for the induction of myocardial infarction after 60 days feeding. Values expressed: ALT, AST, and LDH, mol pyruvate liberated h⁻¹l⁻¹; CPK, mol creatine liberated h⁻¹l⁻¹. ^aP<0.001 significantly different compared with Group I control animals; ^bP<0.001 significantly different compared with Group II chitosan-administered rats; ^cP<0.001 significantly different compared with Group III isoprenaline-induced myocardial infarcted rats; ^dP<0.05 significantly different compared with Group II animals.

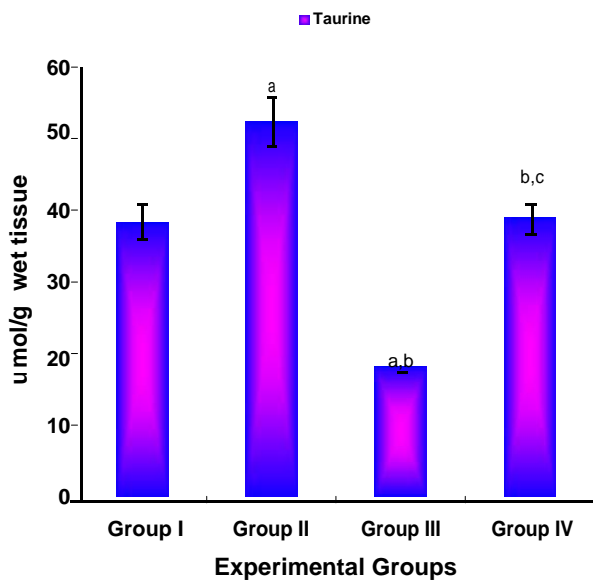


Figure 1. Level of taurine in heart tissue of control and experimental groups of rats. Results are mean ± SD for 6 animals. Group I and Group III animals, fed standard diet with corn starch at 2% level for 60 days. Group II and Group IV, fed standard diet with added chitosan at 2% level for 60 days. Group III and Group IV animals, intraperitoneally (i.p.) injected with isoprenaline [11mg (dissolved in physiological saline)/100g body weight per day for 2 days] for the induction of myocardial infarction after 60 days feeding. ^aP<0.001 significantly different compared with Group I control animals; ^bP<0.001 significantly different compared with Group II chitosan-administered rats; ^cP<0.001 significantly different compared with Group III isoprenaline-induced myocardial infarcted rats.

RESULTS

Table 1 shows the levels of diagnostic marker enzymes

(AST, ALT, LDH and CPK) in the plasma of normal and experimental groups of rats. There was a significant ($P<0.001$) elevation noticed in the levels of these marker enzymes in the plasma of Group III isoprenaline-induced myocardial infarcted rats compared to Group I control rats. The dietary chitosan supplementation significantly ($P<0.001$) reduced the isoprenaline-mediated release of these diagnostic marker enzymes from the heart tissue into the systemic circulation. Injection of isoprenaline induced a significant depletion in the level of taurine content in heart tissue of Group III rats compared to Group I controls (Figure 1). The Group IV chitosan-fed rats showed a significant ($P<0.001$) increase in cardiac taurine content compared to Group III rats. Interestingly, there was a significant increase observed in the taurine content in the heart tissue of Group II chitosan-supplemented rats as compared to Group I control rats.

There were significant ($P<0.001$) elevation noted in the levels of cholesterol, triglycerides and free fatty acids in the plasma and heart tissue of Group III isoprenaline-injected rats compared to Group I control rats (Table 2 and Table 4). The level of LDL cholesterol was significantly ($P<0.001$) higher in myocardial infarction induced rats, whereas the levels of HDL cholesterol was significantly lower as compared to normal controls (Table 3). In the present study, dietary supplementation chitosan significantly ($P<0.001$) prevented the isoprenaline-induced rise in the levels of total cholesterol, triglycerides and free fatty acids in plasma and heart tissue of Group IV rats compared to Group III rats. Also it maintained the level of LDL-cholesterol and HDL-cholesterol in plasma at a concentration comparable to that of control rats. Phospholipids concentration in heart tissue of the dietary incorporation of chitosan significantly isoprenaline administered animals was significantly ($P<0.001$) lower than

Table 2. Levels of cholesterol, triglycerides, free fatty acids, phospholipids and lipid peroxides in plasma of normal and experimental groups of rats.

Groups	Group I Control	Group II Chitosan	Group III Isoprenaline	Group IV Chitosan+Isoprenaline
Cholesterol	85.4 ± 5.23	71.2 ± 4.56	135 ± 7.48 ^{a,b}	91.4 ± 5.18 ^{c,d}
Triglycerides	42.7 ± 2.78	36.2 ± 1.84	72.9 ± 4.65 ^{a,b}	45.5 ± 2.01 ^c
Free fatty acids	15.6 ± 0.95	14.1 ± 0.92	37.2 ± 2.19 ^{a,b}	21.3 ± 1.23 ^c
Phospholipids	76.9 ± 5.22	81.7 ± 5.08	143 ± 9.46 ^{a,b}	94.5 ± 5.91 ^c
Lipid peroxides	0.97 ± 0.05	0.86 ± 0.06	2.79 ± 0.15 ^{a,b}	1.14 ± 0.08 ^c

Results are mean ± SD for 6 animals. Group I and Group III animals, fed standard diet with corn starch at 2% level for 60 days. Group II and Group IV, fed standard diet with added chitosan at 2% level for 60 days. Group III and Group IV animals, intraperitoneally (i.p.) injected with isoprenaline [11mg (dissolved in physiological saline)/100g body weight per day for 2 days] for the induction of myocardial infarction after 60 days feeding. Values expressed: cholesterol, triglycerides, free fatty acids and phospholipids - mg/dl; lipid peroxides - n mol/ml. ^a $P < 0.001$ significantly different compared with Group I control animals; ^b $P < 0.001$ significantly different compared with Group II chitosan administered rats; ^c $P < 0.001$ significantly different compared with Group III isoprenaline-induced myocardial infarcted rats; ^d $P < 0.05$ significantly different compared with Group II animals.

Table 3. Levels of LDL-cholesterol and HDL-cholesterol in plasma (mg/dl) of normal and experimental groups of rats.

Groups	Group I Control	Group II Chitosan	Group III Isoprenaline	Group IV Chitosan+Isoprenaline
LDL-cholesterol	38.7 ± 1.96	29.5 ± 1.21	74.6 ± 5.29 ^{a,b}	42.3 ± 2.14 ^c
HDL-cholesterol	19.4 ± 1.17	27.2 ± 1.36 ^a	11.2 ± 0.94 ^{a,b}	22.8 ± 1.12 ^{c,d}

Results are mean ± SD for 6 animals. Group I and Group III animals, fed standard diet with corn starch at 2% level for 60 days. Group II and Group IV, fed standard diet with added chitosan at 2% level for 60 days. Group III and Group IV animals, intraperitoneally (i.p.) injected with isoprenaline [11mg (dissolved in physiological saline)/100g body weight per day for 2 days] for the induction of myocardial infarction after 60 days feeding. ^a $P < 0.001$ significantly different compared with Group I control animals; ^b $P < 0.001$ significantly different compared with Group II chitosan administered rats; ^c $P < 0.001$ significantly different compared with Group III isoprenaline-induced myocardial infarcted rats; ^d $P < 0.05$ significantly different compared with Group II animals.

that of control animals (Table 4). ($P < 0.001$) ameliorated the isoprenaline-mediated degradation of membrane phospholipids.

There was a significant ($P < 0.001$) increase in the level of lipid peroxidation along with a concomitant decline in the level of GSH noted in the heart tissue of Group III isoprenaline-administered rats as compared to controls (Table 2 and Table 4). The dietary supplementation of chitosan significantly ($P < 0.001$) reduced the isoprenaline-induced adverse effects and maintained the level of evaluated parameters at near normalcy. The normal rats receiving chitosan (Group II) alone did not show any significant change when compared with normal (Group I) rats, indicating that it does not *per se* have any adverse effects.

DISCUSSION

The significant ($P < 0.001$) rise observed in the levels of diagnostic marker enzymes (ALT, AST, LDH and CPK) in the plasma of Group III isoprenaline-administered rats as

compared to that of Group I control rats (Table 1), which is in line with earlier reports (Farvin et al., 2004; Karthick and Prince, 2006), is an indication of the severity of isoprenaline-induced necrotic damage to the myocardial membrane. Of all the macromolecules that leak from damaged tissue, enzymes because of their tissue specificity and catalytic activity are the best markers of tissue damage. The release of cellular enzymes reflects non-specific alterations in the plasma membrane integrity and permeability as a response to β -adrenergic stimulation.

In the present study, the dietary supplementation of chitosan at 2% level was significantly ($P < 0.001$) prevented the isoprenaline-induced elevation in the levels of these diagnostic marker enzymes in plasma of Group IV animals compared to Group III isoprenaline-injected rats, indicating the cytoprotective activity of chitosan. Reports by Anandan et al. (2004) indicated that chitosan supplementation was capable of exerting significant cytoprotection on mucosal cell lining from the necrotic damage induced by HCl-ethanol mixture. Jeon et al. (2003) reported that chitosan incorporation attenuated the car

Table 4. Levels of cholesterol, triglycerides, free fatty acids and phospholipids in heart tissue of normal and experimental groups of rats.

Groups	Group I Control	Group II Chitosan	Group III Isoprenaline	Group IV Chitosan + Isoprenaline
Cholesterol	5.45 ± 0.31	4.76 ± 0.25	8.67 ± 0.57 ^{a,b}	6.04 ± 0.31 ^{c,d}
Triglycerides	4.74 ± 0.32	4.16 ± 0.27	8.07 ± 0.62 ^{a,b}	4.95 ± 0.39 ^c
Free fatty acids	0.21 ± 0.02	0.15 ± 0.01	0.43 ± 0.04 ^{a,b}	0.25 ± 0.03 ^c
Phospholipids	28.7 ± 1.63	32.9 ± 1.92	14.5 ± 0.98 ^{a,b}	26.1 ± 1.32 ^c
Lipid peroxides	1.18 ± 0.08	0.91 ± 0.05	2.87 ± 0.18 ^{a,b}	1.34 ± 0.11 ^c
GSH	4.75 ± 0.27	5.34 ± 0.35	2.12 ± 0.15 ^{a,b}	4.67 ± 0.31 ^c

Results are mean ± SD for 6 animals. Group I and Group III animals, fed standard diet with corn starch at 2% level for 60 days. Group II and Group IV, fed standard diet with added chitosan at 2% level for 60 days. Group III and Group IV animals, intraperitoneally (i.p.) injected with isoprenaline [11mg (dissolved in physiological saline)/100g body weight per day for 2 days] for the induction of myocardial infarction after 60 days feeding. Values expressed: Cholesterol, triglycerides, free fatty acids and phospholipids - mg/g wet tissue; lipid peroxides - n mol/mg protein; GSH- µg/g wet tissue. ^a*P*<0.001 significantly different compared with Group I control animals; ^b*P*<0.001 significantly different compared with Group II chitosan administered rats; ^c*P*<0.001 significantly different compared with Group III isoprenaline-induced myocardial infarcted rats; ^d*P*<0.05 significantly different compared with Group II animals.

the carbon tetrachloride-induced hepatic injury in experimental rats. Investigations by Yan et al. (2006) showed that supplementation of chitosan significantly reduced the release of diagnostic marker enzymes from the liver into the systemic circulation in carbon tetrachloride-intoxicated animals.

Taurine makes up more than 50% of the total amino acid pool in the mammalian heart (Lombardini, 1996). It is involved in various important biological and physiological functions, which include cell membrane stabilization, antioxidation, detoxification, osmoregulation and neuro-modulation (Shiny et al., 2005). Warskulat et al. (2004) have demonstrated that pathology develops in the myocardium if the animal is depleted of taurine stores either through a taurine deficient diet or use of taurine transport antagonists. Pion et al. (1987) were the first to explain the role of dietary taurine deficiency associated with a dilated cardiomyopathy observed in experimental animals. The present findings confirmed the same pattern, and showed a significant (*P*<0.001) decrease in myocardial taurine content in Group III myocardial infarction induced rats compared to Group I normal rats (Figure 1). The Group IV rats supplemented with chitosan showed a significant (*P*<0.001) increase in cardiac taurine content as compared to Group III rats.

Taurine is primarily utilized in biological system for the elimination of cholesterol from the body through the bile acid conjugation reactions. Chitosan is capable of increasing the fecal excretion of cholesterol without the involvement of taurine-mediated bile acid conjugation reactions (Yao and Chiang, 2002). This might be the possible reason for the increase noticed in the cardiac taurine content in Group II chitosan-supplemented rats.

Hence, it is possible that the supplementation of chitosan is capable of preserving the cellular taurine content for other important biological processes such as cell membrane stabilization, antioxidation, detoxification and osmoregulation in the myocardium.

Significant (*P*<0.001) rise observed in the levels of cholesterol, triglycerides and free fatty acids in the plasma and heart tissue of Group III rats as compared to Group I control rats is an indication of severity of isoprenaline-induced hyperlipidemic condition (Table 2 and Table 4). The level of LDL cholesterol was significantly (*P*<0.001) higher in Group III myocardial infarction induced rats, whereas HDL cholesterol levels were significantly lower compared to Group I animals (Table 3), which might be due to the increased mobilization of LDL-cholesterol from the blood into the myocardial membranes, resulting in abnormal cholesterol deposition in the myocardium. These findings are in accordance with an earlier reported study (Sangeetha and Quine, 2006), which showed that the free fatty acids liberated from adipose tissue also enters into the myocardium, and the process is proportional to the free fatty acid concentration in the coronary sinus. Though heart can utilize free fatty acids for its energy requirements, the excess free fatty acid may be used for the synthesis of triglycerides, resulting in hypertriglyceridemia as observed in the present study.

In the present study, supplementation with chitosan significantly prevented the isoprenaline-induced elevation in total cholesterol, triglycerides and free fatty acids in plasma and heart tissue of Group IV rats as compared to Group III rats. It also maintained the level of LDL-cholesterol and HDL-cholesterol in plasma at a concentration comparable to that of Group II rats. Earlier reports

(Trautwein et al., 1997; Yao and Chiang, 2002) indicated that chitosan supplementation was effective in lowering plasma total cholesterol, VLDL cholesterol and LDL cholesterol levels in experimental animals. In the present study, a slight reduction in the level of total cholesterol and LDL-cholesterol were also observed in Group II chitosan-fed normal rats, establishing the anticholesterolemic property of chitosan (Ylitalo et al., 2002). The hypolipidemic property of chitosan has already been reported in high fat diet fed experimental animals (Deuchi et al., 1995). The cardioprotective effect of chitosan is probably related to its ability to inhibit the increased accumulation of lipids both in the systemic circulation and in the myocardium by its antilipidemic property.

The significant depletion noticed in the levels of phospholipids in the heart tissue of Group III animals as compared to Group I rats (Table 4), is in line with earlier reported studies (Kaul and Kapoor, 1989; Kumar et al., 2001), which indicate that ischemic injury related alterations in lipid composition of myocardial tissue appears to occur due to the destruction of myocardial membrane lipid bi-layer. Lipid peroxidation *in vivo* has been identified as one of the basic deteriorative reaction in cellular mechanisms of the myocardial ischemia (Singal et al., 1982). The increased peroxidation of membrane phospholipids releases free fatty acids by the action of phospholipase A₂. Hence, the significant elevation noticed in the levels of free fatty acids in plasma and heart tissue of isoprenaline-treated rats might be due to enhanced breakdown of membrane phospholipids, which could very likely be the biochemical basis for the irreversible cell injury and ischemia.

The significant ($P < 0.001$) rise noted in the level of lipid peroxidation with concomitant decline in reduced glutathione in plasma and heart tissue of Group III isoprenaline-administered rats as compared to Group I rats (Table 4) concurs with the findings of Nirmala and Puvanakrishnan, (1996), which indicated that the higher vulnerability of myocardium to peroxidative damage was mainly due to a decline in the level of free radical scavengers. Depletion of GSH results in enhanced lipid peroxidation, and excessive lipid peroxidation can cause increased GSH consumption (Comporti, 1985; Farvin et al., 2004), as observed in the present study. GSH protects the cell membranes from the damaging action of lipid peroxide. In the present study, the animals supplemented with chitosan showed a significant ($P < 0.05$) decrease in the level of lipid peroxidation in the plasma and heart tissue, thus demonstrating the antioxidant effects of chitosan in experimentally induced oxidative stress conditions. Reports by Jeon et al. (2003) have shown that chitosan has strong antioxidative effects, which decrease free radical production and increase antioxidant enzyme activities during CCl₄-induced lipid peroxidation in rats.

It is generally considered that the inhibition of lipid peroxidation by an antioxidant can be explained by various mechanisms. One is the free radical-scavenging activity.

Park et al. (2004) have suggested that chitosan may eliminate various free radicals by the action of nitrogen on the C-2 position of the chitosan. Xie et al. (2001) reported that the scavenging mechanism of chitosan is related to the fact that the free radicals can react with the hydrogen ion from the ammonium ions to form a stable molecule. Youn et al. (2001) have shown that antioxidative effects of chitosan increase with higher concentration as indicated by the results of DPPH radical assay. The present observation also reveals that the supplementation of chitosan is capable of exerting antioxidant property against isoprenaline-induced lipid peroxidation.

In conclusion, the results of the present study indicate that the supplementation of chitosan at a concentration of 2% of the diet for 60 days prevents the symptoms of isoprenaline-induced myocardial infarction in rats. The overall cardioprotective effect of chitosan is probably related to its ability to inhibit the isoprenaline-induced lipid accumulation by its hypolipidemic property and/or to its free radical scavenging ability against isoprenaline-induced lipid peroxidation, which is primarily responsible for the irreversible necrosis of the myocardial membrane.

REFERENCES

- Anandan R, Mathew S, Nair PGV (2004). Antiulcerogenic effects of chitin and chitosan on mucosal antioxidant defense system in HCl-ethanol induced ulcer in rats. *J. Pharm. Pharmacol.* 56: 265-269.
- Anandan R, Asha KK, Ammu K, Suseela M, Nair PGV (2003). Effects of peroxidised PUFA on tissue defense system in experimentally induced myocardial infarction in rats, in *Seafood safety*. Society of Fisheries Technologists (India), Edited by Surendran PK, Mathew PT, Thampuran N, Nambiar N, Joseph J, Boopendranath MR, Lakshmanan PT, Nair PGV Cochin. pp. 330-335.
- Anandan R, Mathew S, Sankar TV, Viswanathan Nair PG (2007). Protective effect of n-3 polyunsaturated fatty acids concentrate on isoproterenol-induced myocardial infarction in rats. *Prostaglandins. Leukot. Essent. Fatty Acids.* 76: 153-158.
- Bartlette GR (1959). Phosphorous assay in column chromatography. *J. Biol. Chem.* 234: 466-468.
- Burstein M, Scholnick HR (1972). Precipitation of chylomicron and very low density lipoprotein from human serum with sodium lauryl sulphate. *Life. Sci.* 1: 177-184.
- Cardenas G, Orlando P, Edelio T (2001). Synthesis and applications of chitosan mercaptanes as heavy metal retention agent. *Int J Biol Macromol.* 28: 167-174.
- Comporti M (1985). Biology of disease: Lipid peroxidation and cellular damage in toxic liver injury. *Lab. Invest.* 53: 599-623.
- Deuchi K, Kanauchi O, Shizukuishi M, Kobayashi E (1995). Continuous and massive intake of chitosan affects mineral and fat-soluble vitamin status in rats fed on a high-fat diet. *Biosci. Biotechnol. Biochem.* 59:1211-1216.
- Farvin KHS, Anandan R, Kumar SHS, Shiny KS, Mathew S, Sankar TV, Nair PGV (2006). Cardioprotective effect of squalene on lipid profile in isoprenaline-induced myocardial infarction in rats. *J. Med. Food.* 9: 531-536.
- Farvin KHS, Anandan R, Kumar SHS, Shiny KS, Sankar TV, Thankappan TK (2004). Effect of squalene on tissue defense system in isoproterenol-induced myocardial infarction in rats. *Pharmacol. Res.* 50: 231-236.
- Filipovic-Grcic J, Skalko-Basnet N, Jalsenjak I (2001). Mucoadhesive chitosan-coated liposomes: characteristics and stability. *J. Microencaps.* 18: 3-12.
- Fiske CH, Subbarow Y (1925). The colorimetric determination of phosphorus. *J. Biol. Chem.* 66: 375-400.

- Folch J, Lees M, Stanely GHS (1957). A simple method for isolation and purification of total lipids from animal tissues. *J. Biol. Chem.* 226: 497-509.
- Horn WT, Menahan LA (1981). A sensitive method for determination of free fatty acids in plasma. *J. Lipid. Res.* 122: 377-381.
- Ishida Y, Fugita T, Asai K (1981). New detection and separation method for amino acid by high performance liquid chromatography. *J. Chromato.* 204: 143-148.
- Jeon TI, Hwang SG, Park NG, Jung YR, Shin SI, Choi SD, Park DK (2003). Antioxidative effect of chitosan on chronic carbon tetrachloride-induced hepatic injury in rats. *Toxicology.* 187: 67-73.
- Karthick M, Prince PSM (2006). Preventive effect of rutin, a bioflavonoid, on lipid peroxides and antioxidants in isoproterenol-induced myocardial infarction in rats. *J. Pharm. Pharmacol.* 58: 701-707.
- Kaul S, Kapoor NK (1989). Reversal of changes of lipid peroxides, xanthine oxidase and SOD by cardio protective drugs in isoproterenol-induced myocardial necrosis in rats. *Indian J. Exp. Biol.* 27: 625-627.
- Kim KW, Thomas RL, Lee C, Park HJ (2003). Antimicrobial activity of native, degraded and O-carboxymethylated chitosan. *J. Food. Prot.* 66: 1495-1498.
- King J (1965). The dehydrogenase of oxidoreductase-lactate dehydrogenase, in *Practical Clinical Enzymology*, edited by King J C, Van D Nostrand Co, London, pp. 83-93.
- Kumar SHS, Anandan R, Devaki T, Kumar MS (2001). Cardioprotective effects of *Picrorrhiza kurroa* against isoproterenol-induced myocardial stress in rats. *Fitoterapia.* 72: 402-405.
- Lombardini JB (1996). Taurine depletion in the intact animal stimulates in vitro phosphorylation of a 44-kDa protein present in the mitochondrial fraction of the rat heart. *J. Mol. Cell. Cardiol.* 28: 1957-1961.
- Mohr A, Cook IY (1957). Simple methods for measuring serum levels of glutamic-oxalo acetic and glutamic-pyruvic transaminase in routine laboratories. *J. Clin. Pathol.* 10: 394-399.
- Nagle DG, Zhou YD (2006). Natural product-derived small molecule activators of hypoxia-inducible factor-1 (HIF-1). *Curr. Pharm. Des.* 12: 2673-2688.
- Nirmala C, Puvanakrishnan R (1996). Protective role of curcumin against isoproterenol induced myocardial infarction in rats. *Mol. Cell. Biochem.* 159: 85-93.
- Ohkawa H, Ohishi N, Yagi K (1979). Assay for lipid peroxides in animal tissue by thiobabutaric acid reaction. *Anal. Biochem.* 95: 351-358.
- Okinaka S, Kumogai H, Ebashi S, Sugaita H, Momoi H, Toyokura Y, Fujie Y (1961). Serum creatine phosphokinase activity in progressive muscular dystrophy and neuromuscular disease. *Arch. Neurol.* 4: 520-525.
- Packard KA, Majeed F, Mohiuddin SM, Mooss AN, Hilleman DE, Arouni AJ (2005). Low high-density lipoprotein cholesterol is associated with impaired endothelial function in Asian Indians. *Ethn. Dis.* 15: 555-561.
- Padma VV, Devi CS, Ramkumar KM (2006). Modulatory effect of fish oil on the myocardial antioxidant defense system in isoproterenol-induced myocardial infarction. *J. Basic. Clin. Physiol. Pharmacol.* 17: 1-15.
- Parekh AC, Jung DH (1970). Cholesterol determination with ferric acetate- uranyl acetate and sulphuric acid – ferrous sulphate reagents. *Anal. Chem.* 42: 1423-1427.
- Park PJ, Je JY, Kim SW (2004). Free radical scavenging activities of different deacetylated chitosans using an ESR spectrometer, *Carbohydrate Polymer.* 55: 17-22.
- Pion PD, Kittleson MD, Rogers QR, Morris JG (1987). Myocardial failure in cats associated with low plasma taurine: a reversible cardiomyopathy. *Science.* 237: 764-768.
- Rajadurai M, Stanely Mainzen Prince P (2006). Preventive effect of naringin on lipids, lipoproteins and lipid metabolic enzymes in isoproterenol-induced myocardial infarction in Wistar rats. *J. Biochem. Mol. Toxicol.* 20: 191-197.
- Rice EW (1970). Triglycerides in serum, In *Standard methods in clinical chemistry*, (Roedrick P, Mc Donald RP, Eds), Academic press. New York, p.215.
- Sangeetha T, Darlin Quine S (2006). Preventive effect of S-allyl cysteine sulfoxide (allicin) on cardiac marker enzymes and lipids in isoproterenol-induced myocardial injury. *J. Pharm. Pharmacol.* 58: 617-623.
- Santhosh S, Sini TK, Anandan R, Mathew PT (2006). Effect of chitosan supplementation on antitubercular drugs-induced hepatotoxicity in rats. *Toxicology.* 219: 53-59.
- Senel S, McClure SJ (2004). Potential applications of chitosan in veterinary medicine. *56:1467-1480*
- Shiny KS, Kumar SHS, Farvin KHS, Anandan R, Devadasan K (2005). Protective effect of taurine on myocardial antioxidant status in isoprenaline-induced myocardial infarction in rats. *J. Pharm. Pharmacol.* 57: 1313-1317
- Singal PK, Kapur N, Dhillion KS, Beamish RE, Dhalla NS (1982). Role of free radicals in catecholamine-induced cardiomyopathy. *Can. J. Physiol. Pharmacol.* 60: 1390-1397.
- Sumiyoshi M, Kimura Y (2006). Low molecular weight chitosan inhibits obesity induced by feeding a high-fat diet long-term in mice. *J. Pharm. Pharmacol.* 58: 201-207.
- Tilak-Jain JA, Devasagayam TPA (2006). Cardioprotective and other beneficial effects of some Indian medicinal plants. *J. Clin. Biochem. Nutr.* 38: 9-18.
- Trautwein EA, Jurgensen U, Erbersdobler HF (1997). Cholesterol lowering and gallstone-preventing action of chitosans with different degrees of deacetylation in hamsters fed cholesterol-rich diets. *Nutr. Res.* 17: 1053-1065.
- Van Bennekum AM, Nguyen DV, Schulthess G, Hauser H, Phillips MC (2005). Mechanisms of cholesterol-lowering effects of dietary insoluble fibres: relationships with intestinal and hepatic cholesterol parameters. *Br. J. Nutr.* 94: 331-337.
- Warskulat U, Flogel U, Jacoby C, Hartwig HG, Thewissen M, Merx MW, Molojavyi A, Heller-Stilb B, Schrader J, Haussinger D (2004). Taurine transporter knockout depletes muscle taurine levels and results in severe skeletal muscle impairment but leaves cardiac function uncompromised. *FASEB J.* 18: 577-579.
- Xie W, Xu P, Liu Q (2001). Antioxidant activity of water-soluble chitosan derivatives. *Biorg. Med. Chem. Lett.* 11: 1699-1701.
- Xu G, Huang X, Qiu L, Wu J, Hu Y (2007). Mechanism study of chitosan on lipid metabolism in hyperlipidemic rats. *Asia Pac J. Clin. Nutr.* 16: 313-317.
- Yan Y, Wanshun L, Baoqin H, Bing L, Chenwei F (2006). Protective effects of chitosan oligosaccharide and its derivatives against carbon tetrachloride-induced liver damage in mice. *Hepatol. Res.* 35: 178-84.
- Yao HT, Chiang MT (2002). Plasma lipoprotein cholesterol in rats fed a diet enriched in chitosan and cholesterol. *J. Nutr. Sci. Vitaminol. (Tokyo).* 48: 379-383.
- Ylitalo R, Lehtinen S, Wuolijoki E, Ylitalo P, Lehtimäki T (2002). Cholesterol-lowering properties and safety of chitosan. *Arzneimittelforschung.* 52: 1-7.
- Youn SK, Kim YJ, Ahn DH (2001). Antioxidative effects of chitosan in meat sausage. *J. Korean Soc. Food Sci. Nutr.* 30: 477-481.