

Full Length Research Paper

Laparoscopic nephrectomy for atrophic kidney due to serious infection: A review of 15 cases

Hitoshi Yanaihara¹, Fuminari Hanashima¹, Koichiro Ogihara¹, Hirofumi Kaguyama¹, Hirofumi Sakamoto¹, Kayo Aonuma¹, Kaori Matsuda², Yoko Nakahira¹ and Hirotaka Asakura¹

¹Department of Urology, Saitama Medical University, Saitama, Japan.

²Department of Urology, Kanetsu Hospital, Saitama, Japan.

Accepted 5, March 2014

Review cases in which laparoscopic nephrectomy was performed for atrophic kidney due to serious infection with an emphasis on procedural details and complications. Data from 15 patients who underwent laparoscopic nephrectomy for atrophic kidney due to serious infection between November 2007 and March 2013 were reviewed. All procedures were performed by a single surgeon at our institution. Atransperitoneal approach was used in 14 patients and drainage tubes were placed in the renal fossa following nephrectomy in 10 patients. The tubes were removed on the first postoperative day in 9 patients. Postoperative antibiotic therapy was required in 1 patient, but all procedures were completed without requiring a blood transfusion. No conversions to an open surgical procedure were required, and there were no serious complications in any of the patients. The pneumoperitoneum time and blood loss of the patients were 126.5 ± 58.8 min (range, 61–261 min) and 37.7 ± 81.2 mL (range, 0–300 mL), respectively. Contrary to reports from previous studies, threat of blood transfusion and conversion to open surgery in patients undergoing laparoscopic nephrectomy for atrophic kidney due to serious infection was low in our study. With technological advances, the benefits of laparoscopic management increasingly outweigh the difficulties of this procedure. Laparoscopic nephrectomy for infectious conditions is an acceptable alternative to open nephrectomy when selected with appropriate preparation and forethought.

Key words: Laparoscope, nephrectomy, atrophic kidney, infection, complication.

INTRODUCTION

The use of laparoscopic procedures has become more popular due to improvements in techniques and equipment. However, because of unpredictable perinephric inflammatory changes, laparoscopic nephrectomy (LN) for atrophic kidney due to serious infection remains challenging with a high rate of conversion to open surgery and risk of blood loss reported in the literature (Duarte et al., 2008; Hsiao and Pattaras, 2008; Katz et al., 2004; Manohar et al., 2007; Shekarriz et al., 2001; Smith and Pasic, 2008; Tobias-Machado et al., 2005; Winaikosol et al., 2012).

In oncology, the standard surgical steps performed by clinicians are consistent, and there are many cases of each specific disease, therefore, surgical techniques are

easily taught and can be mastered through performing procedures repeatedly. In contrast, the number of cases of atrophic kidney due to serious infection is low and the renal hilum may be difficult to dissect because of inflammatory changes caused by infection. For these reasons, performing LN for infectious conditions may be challenging because surgeons have less experience with it than with using LN for more common, less complicated diagnoses.

Difficulties in using this procedure have been reported in the literature (Duarte et al., 2008; Hsiao and Pattaras, 2008; Katz et al., 2004; Manohar et al., 2007; Shekarriz et al., 2001; Smith and Pasic, 2008; Tobias-Machado et al., 2005; Winaikosol et al., 2012); however, some of the data may be flawed for 2 reasons. First, in most of the previous studies the procedure was performed by several surgeons, so differences in technique may have been a factor. Second, the use of sealing devices during the procedure has not been reported in previous studies, either

*Corresponding author. E-mail: yanaiha@saitama-med.ac.jp
Tel: +81-49-276-1243; Fax: +81-49-295-8004

because use of the devices was not considered or because the studies were conducted before 2006 when the devices became available.

We reviewed the data on 15 patients who underwent LN for atrophic kidney due to serious infection between November 2007 and March 2013. All procedures were performed by a single surgeon in our facility using sealing devices when indicated.

METHODS

The study included 15 female patients who underwent LN for atrophic kidney due to serious infection performed by a single surgeon at our institution between November 2007 and March 2013. This study was approved by institutional review board of Saitama Medical University Hospital.

The study patients required LN because of near total loss of renal parenchymal function or because the benefit of nephrectomy was determined to exceed the benefit of preserving the kidney. All patients had at least 1 episode of serious infectious episode and a clinical history of urolithiasis and/or ureteropelvic junction obstruction. The clinical data of the patients are presented in Table 1.

Prior to the operation infection was controlled with antibiotics or by placement of a drainage tube. Preoperatively, a nephrostomy tube was inserted in 6 patients, and a ureteral stent was used in 2 patients. LN was not performed until at least one month after complete remission of an infectious episode.

A transperitoneal approach was used in 14 patients. To prevent the spread of microorganisms to the central nervous system, a retroperitoneal approach was used in 1 patient who had a ventriculoperitoneal shunt.

Devices used during the procedures included a monopolar scalpel with suction, bipolar forceps, and a sealing device. Renal arteries and veins were ligated with the polymer ligation system followed by dissection if possible.

Perioperative data including pneumoperitoneum time, blood loss, and complications were recorded. All data was retrospectively analyzed.

RESULTS

The mean pneumoperitoneum time and perioperative blood loss were 126.5 ± 58.8 min (range, 61–261 min) and 37.7 ± 81.2 mL (range, 0–300 mL), respectively. No conversions to an open surgical procedure were required. The renal arteries could not be identified during the procedure in 3 patients, and the renal artery and renal vein could not be identified in 1 of the 3 patients. In these patients, the unidentified renal vessels were sealed and dissected with a vessel sealing system. No serious complications were recorded, although intraoperative

spillage from the renal pelvis was observed in 3 patients. No patients required a perioperative blood transfusion.

Postoperative drainage tubes were placed according to the personal preference of the surgeon, and 10 patients had one placed in the renal fossa. The drainage tubes were removed on the first postoperative day in 9 of the 10 patients. Postoperative antibiotic therapy was required in 1 patient.

One wound infection, which was treated while local drainage was reported.

DISCUSSION

LN for atrophic kidney due to serious infection is an important method of controlling infection, but may be a difficult procedure because of dense perinephric adhesions. The usual causes of atrophic kidney are urolithiasis and ureteropelvic junction obstruction (Duarte et al., 2008; Hsiao and Pattaras, 2008; Katz et al., 2004; Manohar et al., 2007; Shekarriz et al., 2001; Smith and Pasic, 2008; Tobias-Machado et al., 2005; Winaikosol et al., 2012). In our study, all patients were female, but this demographic has not been previously reported in the literature. High rates of blood transfusion (7–12%) and conversion to open nephrectomy (5–17%) have been reported (Duarte et al., 2008; Hsiao and Pattaras, 2008; Katz et al., 2004; Manohar et al., 2007; Shekarriz et al., 2001; Smith and Pasic, 2008; Tobias-Machado et al., 2005; Winaikosol et al., 2012); however, the rate of these complications were low in our case series. This may be attributable, in part, to the use of bipolar and sealing devices since 2006, although high rates of these complications have continued to be reported after 2006.

The use of nephrostomy or ureteral stent to control infection prior to nephrectomy is controversial. We prefer to use a nephrostomy tube because we have found it provides excellent infection control and provides an accurate assessment of renal function. Katz et al. (2004) reported nephrostomy tube placement was performed in 75% of the cases of LN for infected, obstructed, or nonfunctioning kidneys.

However, nephrostomy may interfere with the use of a retroperitoneal surgical approach (Hsiao and Pattaras, 2008).

At our institution, a transperitoneal approach is preferred for several reasons. Because the renal hilum is frequently covered by copious amounts of stiff tissue (Figure 1), the wide visual field provided by a transperitoneal approach is beneficial for accurate dissection. In addition, when a large amount of infectious spillage from the pelvis cannot be avoided, a transperitoneal approach allows thorough lavage followed by drainage tube placement, which usually results in an uncomplicated postoperative course. However, there are studies describing the advantage of a retroperitoneal approach (Winaikosol et al., 2012).

Table 1. Clinical data of 15 patients who underwent a paroscopic nephrectomy for atrophic kidney due to serious infection.

Pt No.	age	sex	clinical diagnosis	side	preoperative drainage	approach	Pneumoperitoneum time (min)	Blood Loss (ml)	intraoperative spillage	Postoperative drain
1	50	female	PUJO	rt	nephrostomy	TP	135	little	+	+
2	55	female	stone	left	nephrostomy	TP	132	little	-	+
3	72	female	stone	rt	none	TP	108	25	-	+
4	70	female	PUJO	rt	nephrostomy	TP	150	110	-	+
5	62	female	stone	rt	nephrostomy	TP	217	100	-	+
6	65	female	stone	rt	none	TP	85	little	-	-
7	57	female	stone	rt	none	TP	65	little	-	-
8	81	female	stone	rt	none	RP	85	little	-	+
9	68	female	PUJO	rt	none	TP	118	30	+	+
10	60	female	stone	rt	nephrostomy	TP	174	little	-	+
11	55	female	stone	left	ureteral stent	TP	163	300	-	+
12	23	female	PUJO	rt	ureteral stent	TP	70	little	-	-
13	64	female	PUJO	rt	none	TP	74	little	-	-
14	69	female	PUJO	left	nephrostomy	TP	61	little	-	-
15	44	female	Ileal conduit	left	none	TP	261	little	+	+

Abbreviations: PUJO = pyeloureteral junction obstruction, TP = transperitoneal, RP = retroperitoneal.

Prior to the exposing of the renal hilum, adhesions to adjacent organs should be taken down. The extent of adhesions cannot be predicted preoperatively. The pancreas, duodenum, colon, spleen, and vena cava should be meticulously dissected using extreme caution (Duarte et al., 2008; Hsiao and Pattaras, 2008; Katz et al., 2004; Manohar et al., 2007; Winaikosol et al., 2012). Damage to hidden vessels during adhesion take down may result in abrupt bleeding despite the use of a sealing device is used. Injury of adjacent organs is common in this procedure, and it is main indication for conversion to open surgery (Duarte et al., 2008; Hsiao and Pattaras, 2008; Katz et al., 2004; Winaikosol et al., 2012).

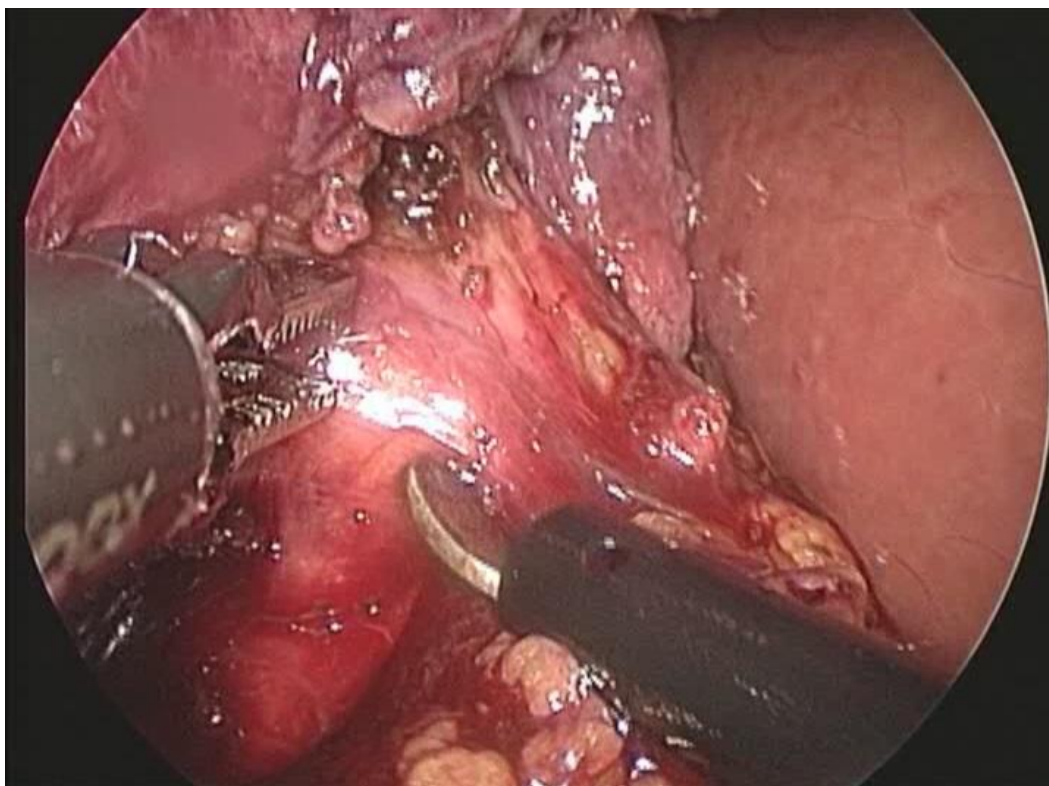
Because the renal artery is usually atrophic, renal blood flow is frequently limited. Renal vein size is often preserved, but it is frequently covered with

fibrose tissue, which may prevent division of the renal vessels. When this occurs, conversion to open surgery is indicated. This problem may be overcome by cutting the entire renal hilum using a sealing device. The dissection of the renal pedicle using an endoscopic stapler following the complete exposure of the entire kidney has been described in previous reports (Katz et al., 2004).

A drainage tube can be placed when necessary; however, even when massive pelvic content spillage occurs, lavage may be more important than drainage. In our case series, drainage tubes were placed in 10 out of 15 patients; however, most of these may not have been necessary, because 9 of 10 placed tube could be removed on the first postoperative day.

The operation time for LN may be longer than for an ordinary

Figure 1. Renal hilum completely covered with fibrosed tissue causing the renal vein to be unidentifiable.



radical nephrectomy. In addition, a higher blood loss is expected with LN. However, previous case series have demonstrated good results (Duarte et al., 2008; Hsiao and Pattaras, 2008; Katz et al., 2004; Manohar et al., 2007; Shekarriz et al., 2001; Tobias-Machado et al., 2005; Winaikosol et al., 2012). This procedure could be performed only by trained surgeons using standard, consistent techniques. None of our patients required blood transfusion or conversion to open surgery. We believe this is because the procedures were performed after 2007 when bipolar devices and sealing devices became available. The usefulness of bipolar and sealing devices has often been reported in ordinary surgical settings (Smith and Pasic, 2008), but we believe it could be used more frequently in LN due to serious infection. However, it should be remembered that nephrectomy for xanthogranulomatous pyelonephritis is the most challenging procedure, and it carries a higher open conversion rate (26–40%) (Duarte et al., 2008; Khaira et al., 2005; Arvind et al., 2011).

CONCLUSION

Laparoscopic nephrectomy for infectious conditions is uncommon and usually challenging. Previous studies report a high rate of blood transfusion and conversion to

open surgery, even when experienced surgeons perform the procedure. However, technical difficulties can now be overcome with improved technology. Trained surgeons can elect to perform laparoscopic surgery for most procedures, but we must remain aware the individual patients vary and complications can unexpectedly arise during any operation. Therefore, an alternative procedure should always be considered before any procedure in case complications arise. Laparoscopic procedures continue to improve with time. LN for infectious conditions will become an increasingly viable option when chosen with appropriate preparation and forethought.

Nonstandard abbreviations: LN = laparoscopic nephrectomy

ACKNOWLEDGMENTS

The authors have no financial grants, funding, or affiliations to acknowledge.

REFERENCES

Arvind NK, Singh O, Ali Q, Gupta SS, Sahay S (2011). Laparoscopic nephrectomy in xanthogranulomatous pye-

- lonephritis: 7-year single-surgeon outcome. *Urology*. 78(4): 797-801.
- Duarte RJ, Mitre AI, Chambô JL, Arap MA, Srougi M (2008). Laparoscopic nephrectomy outside Gerota fascia for management of inflammatory kidney. *J. Endourol*. 22(4): 681-686.
- Hsiao W, Pattaras JG (2008). Not so "simple" laparoscopic nephrectomy: outcomes and complications of a 7-year experience. *J. Endourol*. 22(10):2285-90.
- Katz R, Pode D, Golijanin D, Gofrit ON, Shenfeld OZ, Shapiro A, Reissman P (2004). Laparoscopic nephrectomy for infected, obstructed and nonfunctioning kidneys. *Surg. Laparosc. Percutan. Tech*. 14(6): 340-343.
- Khaira HS, Shah RB, Wolf JS (2005). Laparoscopic and open surgical nephrectomy for xanthogranulomatous pyelonephritis. *J. Endourol*. 19(7): 813-817.
- Manohar T, Desai M, Desai M (2007). Laparoscopic nephrectomy for benign and inflammatory conditions. *J. Endourol*. 21(11): 1323-1328.
- Shekarriz B, Meng MV, Lu HF, Yamada H, Duh QY, Stoller ML (2001). Laparoscopic nephrectomy for inflammatory renal conditions. *J. Urol*. 166(6): 2091-2094.
- Smith R, Pasic R (2008). The role of vessel sealing technologies in laparoscopic surgery. *Surg. Technol. Int*. 17:208-12.
- Tobias-Machado M, Lasmar MT, Batista LT, Forseto PH Jr, Julianon RV, Wroclawski ER (2005). Laparoscopic nephrectomy in inflammatory renal disease: proposal for a staged approach. *Int. Braz. J. Urol*. 31(1): 22-28.
- Winaikosol K, Phacherat K, Chotikawanich E (2012). Laparoscopic simple nephrectomy: perioperative outcomes at Srinagarind Hospital. *J. Med. Assoc. Thai*. 95 (Suppl 11):18-24.