

## Case Report

# Pyknodysostosis with hearing impairment: A case report

Mohd Ashraf<sup>1</sup>, Arshad Farooq<sup>1</sup>, Tasaduq Ahmad<sup>1</sup>, Mohmmad Himayun<sup>1</sup> and Khurshed A Wani<sup>2</sup>

<sup>1</sup>Sher-i-Kashmir Institute of Medical Sciences (SKIMS) Medical College, and <sup>2</sup>Govt. Medical College (GMC) Srinagar.

Accepted 03 November, 2010

Pyknodysostosis is a rare sclerosing bone disease that has autosomal recessive trait. It is characterized by small stature, diffuse osteosclerosis with tendency to transverse fractures, acro-osteolysis of fingers, with flattened and grooved nails. Other features include persistence of fontanelles, delayed closure of sutures, wormian bones, absence of frontal sinuses and obtuse mandibular gonial angle with relative mandibular prognathism. We report a 9-year-old girl having features of pyknodysostosis with progressive hearing impairment, in the form of otosclerosis.

**Keywords:** Craniofacial abnormalities, hearing impairment, otosclerosis, pyknodysostosis, sclerosing bone diseases.

## INTRODUCTION

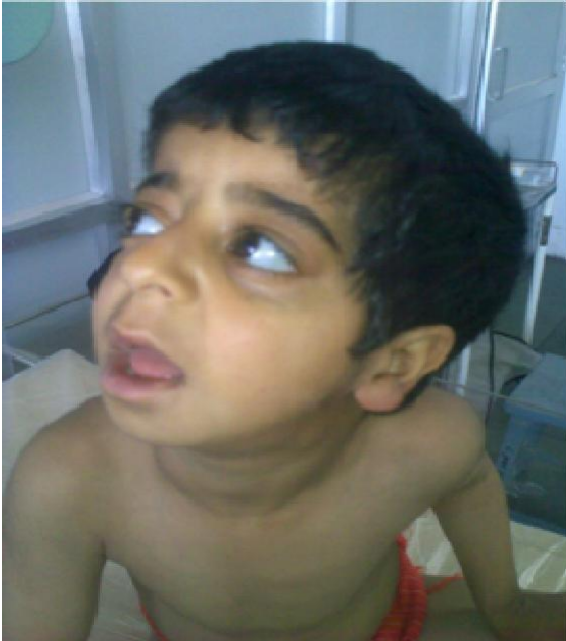Pyknodysostosis, first described in 1962 by Maroteaux and Lamy (Maroteaux et al., 1962), is a rare autosomal recessive disorder characterized by post natal onset of short limbed short stature and generalized hyperostosis. These patients have acro-osteolysis with sclerosis of the terminal phalanges, a feature that is considered essentially pathognomonic (Fleming et al., 2007). Other features include diffuse osteosclerosis with tendency to transverse fractures, flattened and grooved nails, wrinkled skin, kyphosis and scoliosis (Schmitz et al., 1996), persistence of fontanelles, delayed closure of sutures, presence of wormian bones, absence of frontal sinuses and obtuse mandibular gonial angle with relative mandibular prognathism are common features (Glass et al., 1996). The intellectual and sexual development is usually normal in these patients. In some patients a history of repeated chest infection and sleep apnea due to upper respiratory obstruction has been reported (Sing et al., 2004). Fronto-parietal bossing, thick calvaria, open fontanelles and sutures, hypoplastic paranasal sinuses, relative proptosis, beaked nose, blue sclera and hypoplastic midface are among cranial and maxillofacial features of this disorder. A greater tendency for fractures, especially of the long bone is

a common finding in this disorder (Edelson et al., 1992). However, hearing impairment with pyknodysostosis has not been presented as an association which is the illustrative interest in our case.

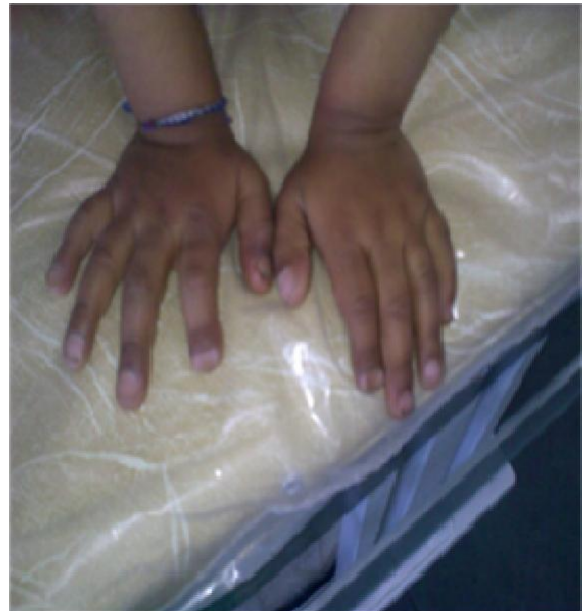## CASE REPORT

A nine-year-old female presented with progressive impairment of hearing and short stature. Detailed history revealed that this patient was a product of consanguineous marriage and had uneventful antenatal, post natal period or other illness (meningitis) that could have association with this hearing impairment. There was no positive familial or drug history. This patient had normal neuromotor and sociobehavioral development with progressive hearing impairment from last 6 months. Patient anthropometry showed height of 110 cm (<120cm), arm span of 90cms, weight of 19 kgs (<22.5 Kgs), chest circumference of 57cm with expansion of 2-3 cm on inspiration, head circumference of 53cm. She had dystrophic nails, persistent anterior fontanelle, open skull sutures, blue sclera and sharp beaked nose (Figures 1,2,3), with normal USG cranium, cardiorespiratory status. Laboratory tests showed Hb=10.8g/dL, TLC=8.8  $10^3$  / $\mu$ L, Polys 53, Lymphos= 43% and mixed= 4%. Platelet

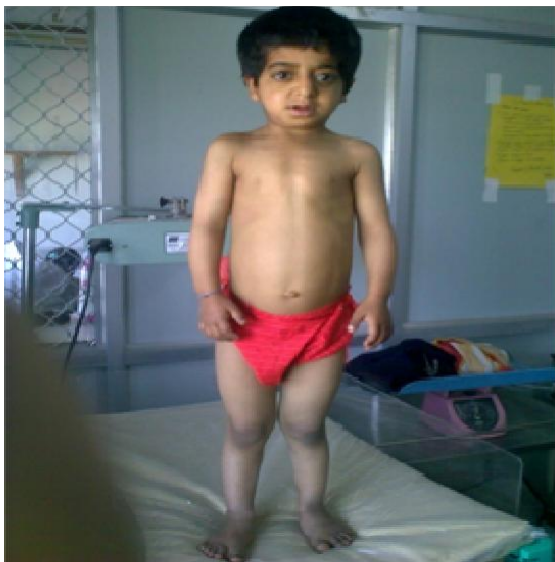\*Corresponding author email: [aashraf\\_05@yahoo.co.in](mailto:aashraf_05@yahoo.co.in);  
Phone: 91-9419011982.



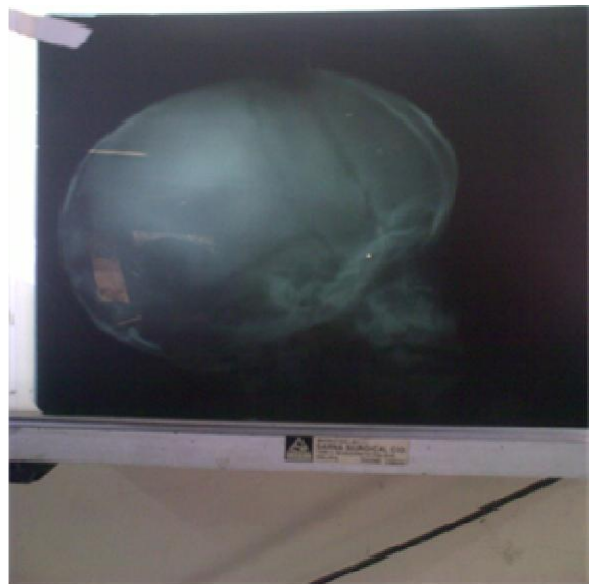**Figure 1.** Showing blue sclera and beaked nose



**Figure 2.** Showing flat and grooved nail



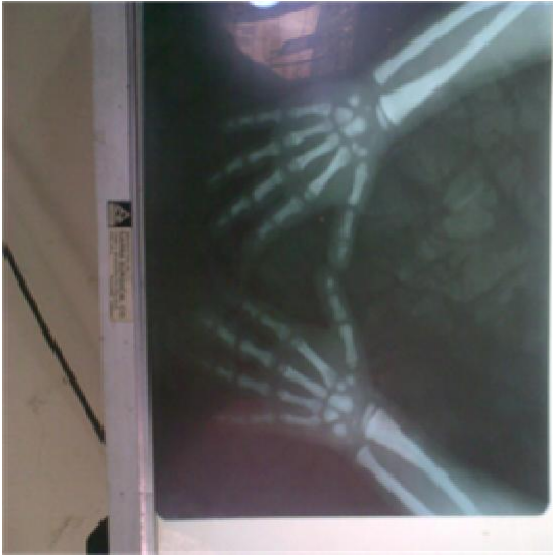**Figure 3.** General phenotypic appearance of pyknodysostotic patient



**Figure 4.** Open anterior and posterior fontanelles

count was  $2.8 \times 10^5/\mu\text{L}$ , S.  $\text{Ca}^{++}=9.8\text{mg/dL}$ , S. Creatinine= 0.6 mg/dL, Alkaline phosphatase 200 IU/L. However, there was generalized increase in bone density on limb X-rays, hypoplastic distal phalanges, and open skull sutures as

shown in the (Figures 4, 5) and otoscopy showed bilateral bluish hue over the promontory with normal tympanic membrane mobility, pure tone audiometry and impedance audiometry showed features suggestive of

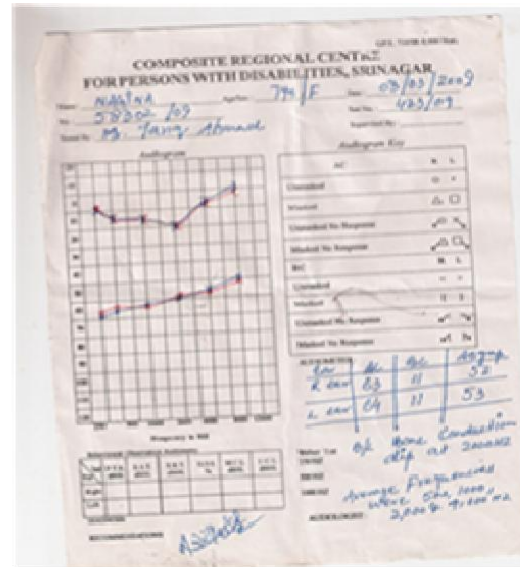


**Figure 5.** Showing increased bone density, with acro-osteolysis of terminal phalanges

bilateral otosclerosis with 52 decibel hearing loss. (Figure 6)

## DISCUSSION

Although our case had various features like small stature, beaked nose, hypoplasia of mid face, persistent fontanelles, blue sclera, proptosis, patent cranial sutures similar to that of other case reports (Maroteaux et. al., 1962; Fleming et. al. 2007), but had no history of repeated chest infections, sleep apnea, kyphosis, and scoliosis (Schmitz et. al., 1996). Our patient is a product of consanguineous marriage which supports the autosomal recessiveness of this disorder. Our patient had come for evaluation of decrease in height for her age and sex, despite good nutrition, and good paternal and sibling heights, and incidentally was found to have moderate degree of hearing loss. Although conductive hearing loss is frequent in infancy; they are usually secondary to acute or chronic otitis media with or with no effusion, which was not remarkable as per the history provided by the parents. Our patient showed bilateral conductive hearing loss of 52 decibels, as per audiometric evaluation (Figure 6), and laboratory features like presence of bilateral Schwartze sign (redish hue seen on promontory through the tympanic membrane), Carharts sign (dip at 2000 Hz in bone conduction), and Weber test not lateralized to any ear with absolute normal bone conduction tests, all were suggestive of associated bilateral otosclerosis, which is extremely rare at this age that too in Indian subcontinent. There is not much literature about this



**Figure 6.** Pune tone audiometry showing hearing loss in this patient

association of pyknodysostosis and otosclerosis, except few case reports (Mujawar et al., 2009). Other congenital or acquired causes of conductive hearing loss, such as otosclerosis, tympanosclerosis, are generally underdiagnosed or diagnosed late, which may result in delayed language development (Briggs et.al., 1994; Murphy et al., 1996;). A complete clinical history, examination and complementary tests are essential for the diagnosis of pyknodysostosis with otosclerosis.

Pyknodysostosis does not have any specific treatment as of date and only supportive measures are needed. Since bone fractures are a primary threat to those affected by Pycnodysostosis, it is important that care is taken to prevent or minimize tendencies for a fracture to occur. Such precautions include careful handling of an affected child, along with exercise and activities that are safe and do not require too much impact. Dental hygiene and regular dental checkups are also necessary. Regarding the Otosclerosis part treatment options include anti-enzyme, bone resorption moderating drugs, and surgical interventions. Surgery is not recommended in children below age 5 years, (Briggs et.al., 1994). Cole, House and Robinson have stated that stapedotomy is a safe and effective treatment in pediatric patients (Cruz et. al., 2000; Robinson et. al., 1983; Cole et.al., 1982). Our patient was put on sodium fluoride (10 mg/day); but the results are not encouraging for this patient. After a careful appraisal of the case and talks with the patients family, we decided for an expectant approach and outpatient monitoring.

## Conclusion

A high rate of suspicion is essential for an early diagnosis of pediatric otosclerosis, in those patients who have bony dysplasias, will make it possible to monitor the disease and to apply the most appropriate treatment. In this study, we found that this patient although a case of Pyknodysostosis, had another significant problem of Otosclerosis, which are not reported earlier in the literature. Henceforth we suggest for active screening of hearing capabilities in pyknodysostotic patients.

## REFERENCES

- Briggs RJS, Luxford WM (1994). Correction of conductive hearing loss in children: *Pediatr. Otol.* 27:607-20.
- Cole JM (1982). Surgery for Otosclerosis in children. *Laryngoscope* 92:859-62.
- Cruz OLM, Costa SS.(2000). In: Cruz OLM, Costa SS. *Otites Médias - Aspectos Gerais* 114. *Otologia Clínica e Cirúrgica*. Rio de Janeiro: Revinter.
- Edelson JG, Obad S, Geiger R, On A, Artul HJ (1992). Pyknodysostosis: Orthopedic Aspects with Description of 14 New Cases. *Clin. Orthop.* 280: 263-276
- Fleming KW, Barest G, Sakai O (2007). Dental and facial bone abnormalities in pyknodysostosis: CT findings. *AJNR Am. J. Neuroradiol.* 28: 132-134.
- Glass RB, Fernbach SK, Norton KI, Choi PS, Naidich TP (2004). The infant skull: a vault of information. *Radiographics* 24: 507-522.
- Maroteaux P, Lamy M (1962). La Pycnodystose. *PresseMed.* 70:999-1002.
- Mujawar Q, Nagarnoor R, Patil H, Thobbi AN, Ukhail S, Malagi N (2009). Pyknodysostosis with unusual findings; a case report. 2: 6544-6549.
- Murphy TP, Wallis DL (1996). Stapedectomy in the Pediatric Patient: *Laryngoscope.*106:1415-1418
- Robinson M (1983). Juvenile Otosclerosis. A 20-year study. *Ann. Otol. Rhinol. Laryngol.* 92:561-565.
- Schmitz JP, Gassmann CJ, Bauer AM, Smith BR (1996). Mandibular reconstruction in a patient with pyknodysostosis. *J. Oral Maxillofac. Surg.* 54:513-517.
- Singh AR, Kaur A, Anand NK, Singh JR (2004). Pyknodysostosis: visceral manifestations and simian crease. *Indian J. Pediatr.* 71: 453-455.