

Full Length Research Paper

Evaluation of estrogen-like activity of *Nigella sativa* in ovariectomized rats

Saadat Parhizkar^{1,2*}, Latiffah Abdul Latiff^{2,3}, Sabariah Abdul Rahman^{2,3} and
Mohammad Aziz Dollah³

¹Faculty of Health, Yasouj University of Medical Sciences, Iran.

²Institute of Biosciences, Universiti Putra Malaysia, Serdang 43400, Malaysia.

³Faculty of Medicine and Health Sciences, Universiti Putra Malaysia, Serdang 43400, Malaysia

Accepted 12 April, 2017

The purpose of the current study was to evaluate estrogenic activity of *Nigella sativa* using ovariectomized (OVX) rats. Forty OVX rats divided into five groups. *N. sativa* was administered orally as a supplement to chaw palate at different doses of 300, 600 and 1200 mg/kg for 21 days to OVX rats and were compared to either positive (0.2 mg/kg conjugated equine estrogen- CEE) or negative control (1 ml distilled water). Histopathological changes of the rats' uterus such as epithelial proliferation and endometrial glandular hyperplasia were assessed as well as uterus weight and serum estradiol level. Supplementation with *N. sativa* resulted in a significant increase in uterine weight as compared to the OVX controls accompanied by altering the serum estrogen levels. Histopathological evaluation of the uterine section revealed changes characterized by atrophy of the uterus in the OVX controls, while the OVX rats supplemented with *N. sativa* showed increased endometrial response as indicated by proliferation of the endometrial glands and epithelial hyperplasia as well as epithelial proliferation and endometrial glandular hyperplasia. The effects of *N. sativa* were comparable to that in the CEE group. *N. sativa* showed the desired effects on the physical, histological and biochemical parameters of the uterine tissue in OVX rats, thereby indicating its probable beneficial role in the treatment of postmenopausal symptoms.

Key words: *Nigella sativa*, estrogenic effect, uterotrophic assay, ovariectomized rat.

INTRODUCTION

Nigella, a genus of the Ranunculaceae family, contains about 20 species many of which have been used as traditional medicinal plants. One of these, *Nigella sativa*, grows to a height of 60 cm, and is distributed in the South Europe, North Africa and south West Asia. Its species are reported to be medicinal plants in the scientific literature as well as in folklore and horticulture, and their medicinal values are well documented (Dey, 1980; Boulos, 1983). The seed of *N. sativa* has been used as a folk medicine for the treatment of a number of illness and conditions that include bronchial asthma, cough, rheumatism, hypertension, diabetes, inflammation, eczema, fever, tumor and influenza (Blunden, 2003; Al-Ghamdi, 2001; Al-Naggar et al., 2003; Nair et al., 1991). Carminative,

diuretic, lactagogue and vermifuge properties have been attributed to a variety of active phytoconstituents in seeds and its oil (Mahmoud et al., 2002; Al-Hader et al., 1993; Swamy and Tan, 2001; Badary, 1999; Daba and Abdel-Rahman, 1998). Several studies on *N. sativa* seeds (Nagi and Mansour, 2000) and its different fractions (Bourgou et al., 2008) have been reported recently but there are no relevant studies on estrogenic activity of *N. sativa*. Because estrogens have typically been used for the treatment of menopausal symptoms and because *N. sativa* have been shown to improve lactation in nursing mothers and to regulate menstruation among females in folk medicine, we investigated the potential estrogenic effects of *N. sativa*. Therefore, the purpose of the present study was to investigate the possible estrogenic effects of *N. sativa*. The uterotrophic assay in ovariectomized rats is one of the classical methods to demonstrate estrogenic activity of chemicals or natural compounds (Clode, 2006). In this study, uterotrophic

*Corresponding author. E-mail: parhizkarsa@gmail.com Tel: +603-8947 2514 Fax: +603-8947 2534

assay, morphological analyses of the uterus and serum estrogen level were used to study the estrogenic activity of *N. sativa*.

MATERIALS AND METHODS

Plant

N. sativa seeds (imported from India) were purchased from a local shop in Serdang, Malaysia. The seed was identified and authenticated by Professor Dr. Nordin Hj Lajis, Head of the Laboratory of Natural products, institute of bioscience, Universiti Putra Malaysia. Voucher specimens of seeds were kept at the cancer research laboratory, institute of bioscience, Universiti Putra Malaysia.

Seeds were cleaned under running tap water for 10 min, rinsed twice with distilled water and air-dried in an oven at 40°C overnight. The seeds and rat chow pellet were ground to a powder using an electric grinder (National, Model MX-915, Kadoma, Osaka, Japan) for 10 min. Grounded seeds and chow pellet mixed with water into three doses of 300, 600 and 1200 mg/kg and backed in an oven at 40°C until receiving instant weight.

Chemicals and reagents

Estradiol radioimmunoassay (RIA) kit was purchased from Diagnostic Systems Laboratories (DSL), USA. Conjugated equine estrogen (CEE 0.625 mg) was purchased from Wyeth, Montreal, Canada. CEE (Wyeth Montreal, Canada), prepared in a dosage of 0.2 mg/kg (Genazzani et al., 2004; Oropeza et al., 2005; Araujo et al., 2006) by dissolving it in distilled water (Genazzani et al., 2004; Hajdu et al., 1965) and was used as a positive control for the purpose of comparison with the treated groups. All other reagents and chemicals were of analytical grade.

Animals

The protocol of the study was approved by animal care and use committee (ACUC) with reference number of UPM/FPSK/PADS/BR/UUH/F01-00220 in accordance to "Guide for care and use of laboratory animals" set by the ACUC of faculty of medicine and health sciences, Universiti Putra Malaysia. The experiment was carried out using 16 week-old female albino Sprague-Dawley rats, weighing 250 to 350 g. They were housed in cages under standard laboratory conditions within a period of 12 h light/dark at 29 to 32°C and 50 to 60% relative humidity in the animal house, faculty of medicine and health sciences, Universiti Putra Malaysia. The animals were allowed to acclimatize for at least 10 days before the start of the experiments. The rats had access to a standard rat chow pellet and drinking water *ad libitum*. Hygienic condition was maintained by changing the bedding weekly. All animal handling were conducted between 08.00 and 10.00 am to minimize the effects of environmental changes. Serum estradiol and body weight were measured at baseline (day 0), 11th, and at the end of experiment (21st days). Histological studies were performed to assess uterine changes at the end of experiment.

Experimental design

Forty rats were ovariectomized in order to induce menopause and to investigate reproductive changes following *N. sativa* supplementation. Their ovariectomy was performed during a distrous cycle to keep the consistent lowest levels of sex hormones

in rats. Surgery of the animals was conducted under a combination of xylazine and ketamine (10 mg/kg + 75 mg/kg, i.p. respectively) anesthesia. Bilateral ovariectomy was performed via a dorso-lateral approach with a small lateral vertical skin incision (Parhizkar et al., 2008). The ovariectomized animals were acclimatized at the Animal House of Faculty of Medicine and Health Sciences for one month prior to supplementation.

The ovariectomized rats were divided equally into five groups (8 animals in each group). The grouping of rats includes negative control (1 ml distilled water by intra-gastric gavage), positive control (0.2 mg/kg/day conjugated equine estrogen-CEE diluted in distilled water by intra-gastric gavage) and the rest groups receiving different doses of *N. sativa*. The test group consist of low dose *N. sativa*-LNS (300 mg/kg NS), moderate dose *N. sativa*-MNS (600 mg/kg NS) and high dose *N. sativa*-HNS (1200 mg/kg NS). Supplementations with *N. sativa*, CEE and distilled water were continued for 3 weeks.

Post-mortem and uterine horn histological study

At the end of the experiment, the rats were weighed and sacrificed under chloroform anesthesia. The uterus was removed and freed from all connective tissue prior to wet weight recordings. To account for individual differences in body weight, an adjusted uterine weight was used for statistical significance calculation. According to Henry and Witt (2002) the actual organ weight, in grams (g), was divided by the actual body weight of the female rats before being sacrificed and multiplied by a standard body weight of 100 g. The adjusted uterine wet weights were reported in g/100 g of body weight. Routine histological processes were employed for paraffin inclusion, sectioning and hematoxylin-eosin staining. Since previous study by Inuwa and Williams (1996), showed that there was no significant difference in structure between the two uterine horns of the same rat and between the various regions of the same horn. One horn from each rat was randomly selected and cut transversely into three equal portion known as proximal, middle and distal. Each portion was prepared as a block and from each block three ribbons were chosen randomly and examined under a light microscope (Olympus CK2) and measurements carried out. For morphological analyses of the uterus, the known E2-induced features recorded includes; shape and height of the luminal and glandular epithelial cells, mitotic figures, determination of hypertrophy and hyperplasia of glands and endometrial epithelium as well as number and types of glands, presence of leucocytes and hypervascularity. The thickness of the endometrium and myometrium were also measured. Appropriate image capture was made using a light microscope (Olympus CK2) coupled to a camera (Olympus BX 41). Measurement was carried out with image analysis software (AxionVision 4.2 RELCarl Zeiss, Jena, Germany).

Statistical analysis

Data were expressed as means \pm standard deviation. The data were analyzed using SPSS windows program version 15 (SPSS Institute, Inc., Chicago, IL, USA). The one-way analysis of variance (ANOVA) and general linear model (GLM) followed by Duncan multiple range test (DMRT) were used to determine which *N. sativa* concentration shows the most significant effect. A p-value less than 0.05 ($P < 0.05$) was considered to be significant.

RESULTS

Uterine weights

Dietary exposure of the rats to various doses of NS or

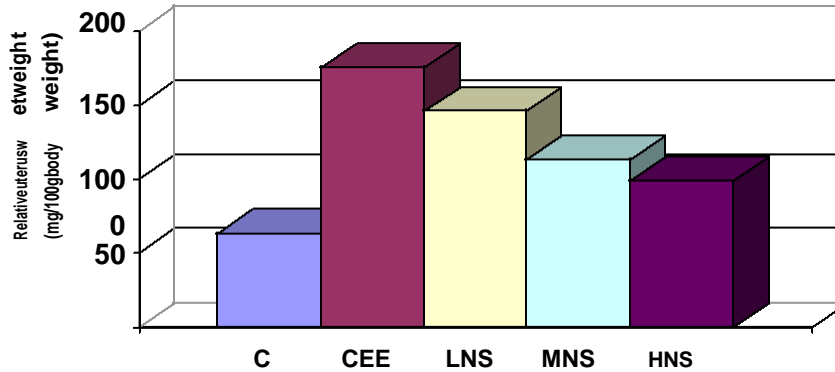


Figure 1. Means of uterus relative weight of OVX rats (mg/100 gm body weight) supplemented with various doses of *N. sativa* or conjugated equine estrogen. Treatment: C = control (1 ml distilled water); CEE = conjugated equine estrogen (0.2 mg/kg); LNS = low dose of *N. sativa* (300 mg/kg); MNS = medium dose of *N. sativa* (600 mg/kg); HNS = high dose of *N. sativa* (1200 mg/kg) groups. Data is expressed as mean. *: Significantly different as compared to control at $P < 0.05$.

CEE for 3 consecutive weeks tends to increase uterine weight ($P < 0.05$) (Figure 1) and resulted in a 2.63 and 2.1 fold increment of the uterine weight for CEE and LNS, respectively. Calculating relative uterus wet weight showed that increased of uterine weight was due to treatment. However, the response was significantly less than that observed in CEE-treated rats ($P < 0.05$).

Morphologic analyses

Microscopical examination of uteri of ovariectomized rats of the control group revealed atrophic endometrium in all cases. All the endometrial glands in these uteri had a narrow lumen and a round or oval shape, microscopical reflection of simple tubular glands which were regarded as normal. All glands were lined with simple cuboidal epithelium. The endometrium was composed of cuboidal inactive cells and the connective tissues contain round nuclei. No mitotic activity was detected in epithelial cells. In rats subjected to CEE, the number of glands, their size and the number of a typical glands, especially glands with daughter glands and glands forming conglomerates, were increased (Figures 2 and 3). The number of glands lined with pseudostratified or stratified epithelium, which often contained a typical cells and nuclei, were also increased by CEE treatment (Figure 4). All uterine structures became hypertrophic and hyperplastic following estrogen treatment. Although differing in intensity, endometrium was hypertrophic and hyperplastic in all animals with dispersed chromatin and prominent nuclei. Mitotic figures were observed in endometrial epithelium and lumen epithelium. Some of these effects in the CEE group are shown in Figure 4B (mitotic cells).

The different doses of *N. sativa* induced proliferate changes in the uterine endometrium as evidenced by increased height of luminal and glandular epithelium with

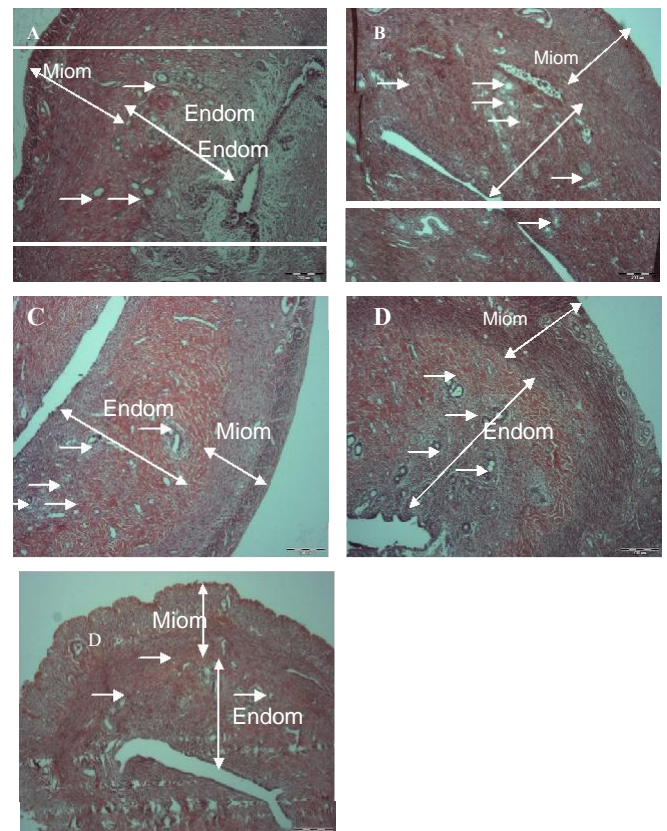


Figure 2. Photomicrographs showing representative uterus of OVX rats: A = Control (1 ml distilled water/day), B= conjugated equine estrogen-CEE (0.2 mg/kg/day CEE), C= LNS, low dose *N. Sativa* (300 mg/kg/day), D= MNS, medium dose *N. Sativa* (600 mg/kg/day) and E= HNS, high dose *N. Sativa* (1200 mg/kg/day). Arrows indicated endometrial glands. Endometrial extension (Endom) and the miometrium (Miom) are seen. In B, C, D and E groups the endometrium appears well developed with a high content of endometrial glands. In all Ns and CEE groups the area of endometrium is much larger than control group. H.E staining (40x).

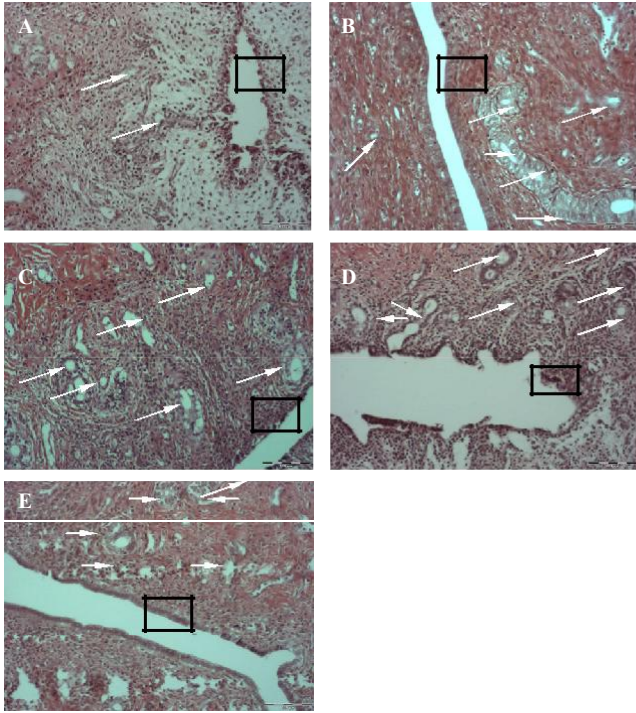


Figure 3. Photomicrographs showing representative endometrium of the uterus of ovariectomized rats: A = Control (1 ml distilled water/day), B= conjugated equine estrogen-CEE (0.2 mg/kg/day CEE), C= LNS, low dose *N. Sativa* (300 mg/kg/day), D= MNS, medium dose *N. Sativa* (600 mg/kg/day) and E= HNS, high dose *N. Sativa* (1200 mg/kg/day). Arrowheads indicated different endometrial glands. The squares indicate the area of uterine lumen and its epithelial cells. H.E. staining (100x).

presence of leukocytes, increased endometrial and myometrial diameters, increased number of glands, present of leucocytes (Table 1), as compared to control, but these changes is more apparent in LNS. In NS groups, endometrial cells were stimulated but no pathologic signs were detected. The uterine histology of rats administered both CEE and NS differed markedly from those of control animals. The number of normal glands was increased significantly ($P < 0.05$) in all NS groups (30, 25, 18 in LNS, MNS and HNS, respectively) as compared to controls (15), which showed a higher number in LNS than CEE (30 vs. 290), but the number of daughter glands and glands forming conglomerates was lower than CEE group.

However, treatment with medium dose of *N. sativa* (600 mg/kg/day) did cause an increase in the number of cystic glands and the incidence of glands with stratified epithelium was not increased. The thickness of endometrium in all NS treated group were significantly higher than in control rats, which in LNS was as much as CEE (363 vs. 371 μm), but myometrial diameter of LNS was even more than CEE (485 vs 463 μm).

The heights of epithelial cells in NS low and medium dose were significantly more than control animals, but not

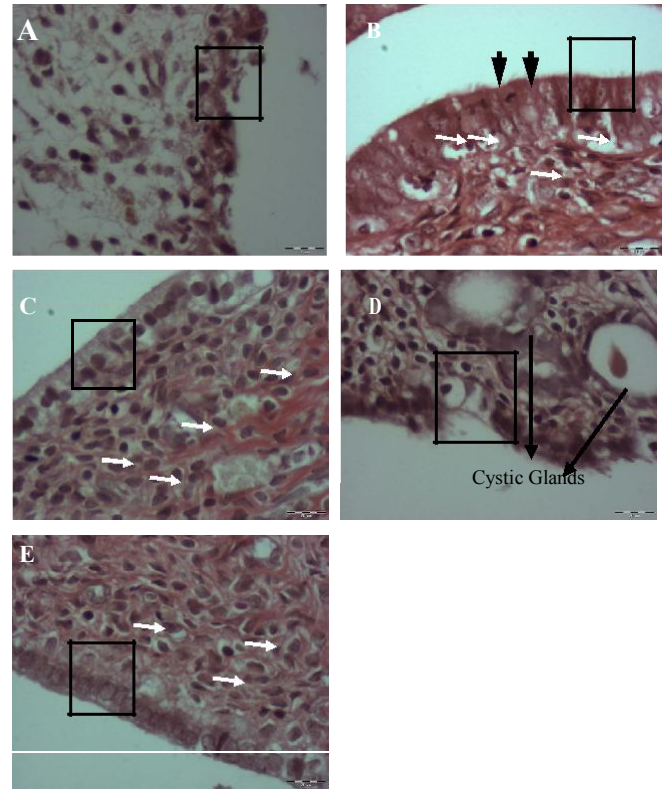


Figure 4. Photomicrography showing representative endometrium of ovariectomized rats: A= control (1ml distilled water/day), B= conjugated equine estrogen-CEE (0.2 mg/kg/day CEE), C= LNS, low dose *N. Sativa* (300 mg/kg/day), D= MNS, medium dose *N. Sativa* (600 mg/kg/day) and E= HNS, high dose *N. Sativa* (1200 mg/kg/day). White arrowheads indicate different leucocytes. Black and thick arrowheads indicate mitosis figure in epithelial cell. The squares indicate the area of uterine lumen and its epithelial cells. H.E. staining (400x).

as much as CEE group. In both CEE and NS groups, the number of leucocytes was increased markedly from those of control rats. There were some leucocytes (arrows), which are fewer in NS groups compare to CEE, but they were significantly more than those of control animals. The histological analysis of the uteri is summarized in Figures 2 to 4.

DISCUSSION

The present study using ovariectomized rats provides the basis for the uterotrophic assay of *N. sativa* at the first time. Treatment with *N. sativa* showed an evidence of uterotrophic activity as indicated by uterine weight and histological changes of uteri in OVX rats. The mechanisms responsible for the effects of phytoestrogens are not clearly understood but there is suggestive evidence that phytoestrogens could act through two possible mechanisms namely, estrogen receptor-dependent and independent (Ginsburg and

Table 1. Summary of physiologic and morphologic finding in uteri of ovariectomized rats supplemented with various doses of *N. sativa* or conjugated equine estrogen.

Parameter	<i>N. sativa</i> supplementations (mg/kg/day)				CEE 0.2 (mg/kg/day)
	C (0)	LNS (300)	MNS (600)	HNS (1200)	
Endometrial thickness (µm)	251 ± 107 ^a	359 ± 67 ^{cd}	313 ± 49 ^{bc}	281 ± 39 ^{ab}	365 ± 123 ^d
Myometrial thickness (µm)	369 ± 125 ^b	483 ± 83 ^c	343 ± 39 ^{ab}	295 ± 57 ^a	473 ± 132 ^c
Luminal epithelial cell height (µm)	4.5 ± 1.2 ^a	15 ± 1.9 ^d	8.6 ± 1.7 ^c	5.9 ± 1.8 ^b	18 ± 3.8 ^e
Glandular epithelial cell height (µm)	6.05 ± 2.4 ^a	13.74 ± 1.24 ^d	9.24 ± 1.89 ^c	7.78 ± 2 ^b	14.42 ± 3.38 ^d
No. of glands	15.41 ± 4.8 ^a	30.58 ± 4.43 ^c	25.20 ± 5.4 ^b	18 ± 4.7 ^a	29.08 ± 6.94 ^c
No. of blood vessels	10.19 ± 0.9 ^a	14.06 ± 1.4 ^c	12.12 ± 1.17 ^b	12.13 ± 1.75 ^b	15.48 ± 1.87 ^d

Data are expressed as Mean ± SD for three slides per rats. The data represent the average of three determinations for each slide. Treatment: C=control group (treated with 1 ml distilled water); CEE= conjugated equine estrogen (treated with 0.2 mg/kg); LNS= low dose of *N. sativa* (treated with 300 mg/kg); MNS= medium dose of *N. sativa* (treated with 600 mg/kg); HNS= high dose of *N. sativa* (treated with 1200 mg/kg) groups. abcde: Comparison of the means between rows significant at P<0.05.

Prelevic, 2000). Many studies have shown that phytoestrogens bind to estrogen receptors and show significant. The considerable change in the levels of estrogen in the present study suggests that *N. sativa* may act both directly and indirectly on the estrogen receptors. These estrogenic activities of *N. sativa* could be attributed to the unsaturated fatty acid contents, which are proven to possess estrogenic activity (Liu et al., 2004; Hu et al., 2007; Suzuki et al., 2008), estrogenic effects in animals, in man and in cell cultures (Banu et al., 2006).

The result of current study showed estrogenic activity of *N. sativa* in various indications such as uterus weight, histological changes of uteri and even blood estradiol (E2) level, which in previous studies only rising in either E2 level (Intan et al., 2008) or vaginal epithelial cell cornification was assayed (Parhizkar et al., 2011). Keshri et al. (1995) reported post-coital contraceptive effect of *N. sativa*. On the other hand Bashandy (2007) showed that *N. sativa* oil improved reproductive performance in hyperlipidemic male rats. The effect might be due to the present of unsaturated fatty acids that are valuable to sustain the reproductive capacity of male animals especially when they are getting older.

Administration of *N. sativa* to ovariectomized rats tended to increase uterine weight, indicating that *N. sativa* contains estrogen-like compounds. The uterine weight increment was significantly lower than that of the positive control (conjugated equine estrogen) group but significantly higher than negative control (distilled water) group which indicated that *N. sativa* exert a weak estrogenic effect. Surprisingly, low dose *N. sativa* exert higher estrogenic effect than moderate and high doses in uterotrophic assay and blood estrogen level. This result was in agreement with Overk et al. (2007) who reported that the low dose of isoflavone extract had more estrogenic potential as compared to higher doses in both *in vivo* and *in vitro* assays. Heyerick et al. (2006) also reported that hope extract in low dose has significant potent to alleviate menopausal discomfort in women, while higher dose did not show any significant effect.

Estrogens are known to cause morphogenetic shifts in the uterus (Martin et al., 1973; Niwa et al., 1998; Couse et al., 1999; Deligdisch, 2000). The histological examination of the uterus of *N. sativa* treated rats showed an estrogenic influence, as evidenced by the increase in the height of both luminal epithelium and endometrial glands, accompanied by the present of leucocytes, an increment in the endometrial and myometrial thickness and an increased in the number of endometrial glands. These results were consistent with uterus weight gain which showed the most estrogenic potent appeared in present of low dose *N. sativa*. The morphologic changes induced by conjugated equine estrogen or *N. sativa* in uterus were similar, differing only in the degree. These results suggest that *N. sativa* has similar although weaker effects than conjugated equine estrogen in the rat uterus. Other study has shown that the post coital effectiveness of *N. sativa* is roughly parallel to its estrogenicity (Keshri et al., 1995). Rimoldi et al. (2007) reported similar results using different doses of Genistein as compared to E2. In contrast, in the present study, *N. sativa* did not show abnormal type of epithelium and a typical endometrial hyperplasia, which has a non-favorable prognosis and is regarded as a pre-cancerous process (Deligdisch, 2000; Silverberg, 2000).

Conclusion

In this study, *N. sativa* showed estrogen-like effects on the physical, histological and biochemical parameters of OVX rats, thereby indicating the probable beneficial role for the treatment of postmenopausal symptoms. In conclusion, this study provides novel evidence in support of continuing action of the traditional use of *N. sativa* in gynecologic disorders.

ACKNOWLEDGEMENT

The authors would like to thank Universiti Putra Malaysia

for its financial support of this research project.

REFERENCES

- Al-Ghamdi MS (2001). The anti-inflammatory, analgesic and antipyretic activity of *Nigella sativa*. *J. Ethnopharmacol.*, 76(1): 45-48.
- Al-Hader A, Aqel M, Hasan Z (1993). Hypoglycemic effect of volatile oil of *Nigella Sativa* seeds. *Int. J. Pharmacol.*, 31: 96-100.
- BH, Blunden G (2003). Pharmacological and toxicological properties of *Nigella sativa*. *Phytother. Res.*, 17(4): 299-305.
- Al-Naggar TB, Gomez-Serranillos MP, Carreto ME, Villar AM (2003). Neuropharmacological activity of *Nigella sativa* L. extracts. *J. Ethnopharmacol.*, 88(1): 63-68.
- Araujo LBF, Soares JM, Simoes RS, Ricardo Santos S, C6 PL, Ricardo Oliveira-Filho M, Sim6es MJ, Haidar MA and Baracat EC (2006). Effect of conjugated equine estrogens and tamoxifen administration on thyroid gland histomorphology of the rat. *Clinics*, 61: 321-326.
- Badary OA (1999). Thymoquinone attenuates ifosfamide-induced Fanconi syndrome in rats and enhances its antitumor activity in mice. *J. Ethnopharmacol.*, 67(2): 135-142.
- Banu J, Bhattacharya A, Rahman M, O'Shea M, Fernandes G (2006). Effects of conjugated linoleic acid and exercise on bone mass in young male Balb/C mice. *Lipids Health Dis.*, 23: 5-7.
- Bashandy SA (2007). Effect of fixed oil of *Nigella sativa* on male fertility in normal and hyperlipidemic rats. *Int. J. Pharmacol.*, 3 (1): 27-33.
- Boulos L (1983). Medicinal plants of North Africa. Reference Publications, Algonac, Michigan, Reference Publication, 103.
- Bourgou S, Ksouri R, Bellila A, Skandrani I, Falleh H, and Marzouk B (2008) Phenolic composition and biological activities of Tunisian *Nigella sativa* L. shoots and roots. *C. R. Biol.*, 331(1): 48-55.
- Clode SA (2006). Assessment of in vivo assays for endocrine disruption. *Best Practice and Research: Clin. Endocrinol. Metab.*, 20(1): 35-43.
- Couse JF, Korach KS (1999). Estrogen receptor null mice: what have we learned and where will they lead us? *Endocr. Rev.*, 20(3): 358-417.
- Daba MH, Abdel-Rahman MS (1998). Hepatoprotective activity of thymoquinone in isolated rat hepatocytes. *Toxicol. Lett.*, 95(1): 23-29.
- Deligdisch L (2000). Hormonal pathology of the endometrium. *Mod. Pathol.*, 13: 285-294.
- Dey AC (1980). Indian Medicinal Plants in Ayurvedic Preparations. Singh, B. K., Singh, M. P., Eds.; Dehradun. 9.
- Genazzani AR, Stomati M, Bernardi F, Luisi S, Casarosa E, Puccetti S, Genazzani AD, Palumbo M and Luisi M (2004). Conjugated equine estrogens reverse the effects of aging on central and peripheral allopregnanolone and beta-endorphin levels in female rats. *Fertil. Steril.*, 81(1): 757-766.
- Ginsburg J, Prelevic GM (2000). Lack of significant hormonal effects and controlled trials of phytoestrogens. *Lancet*, 355: 163-164.
- Hajdu A, Chappel Cland Rona G (1965). The influence of estrogens on scorbutic bone lesions in guinea-pigs. *CMLS*. 21(8): 466-467.
- Henry LA, Witt DM (2002). Resveratrol: Phytoestrogen Effects on Reproductive Physiology and Behavior in Female Rats. *Horm. Behav.*, 41(2): 220-228.
- Heyerick AA, Vervarcke S, Depypere H, Bracke M and De Keukeleire D (2006). A first prospective, randomized, double-blind, placebo-controlled study on the use of standardized hop extract to alleviate menopausal discomfort. *Maturitas*, 54: 164-175.
- Hu Y, Hou TT, Xin HL, Zhang QY, Zheng HC, Rahman Kh, Qin LP (2007). Estrogen-like activity of volatile components from *Vitex rotundifolia* L. *Indian J. Med. Res.*, 126: 68-72.
- Intan NFS, Rashid I, Abdul Latif L, Dollah MA (2008). Effect of Short-term Supplementation of *Nigella savita* on Oestrogen Level in Ovariectomised Rabbits. Universiti Putra Malaysia, Unpublished Thesis.
- Inuwa I, Williams MA (1996). Morphometric study on the uterine horn and thyroid gland in hypothyroid, and thyroxine-treated hypothyroid rats. *J. Anat.*, 188: 383-393.
- Keshri G, Singh MM, Lakshami V, Kamboj VP (1995). Post-coital contraceptive effect of the seeds of *Nigella sativa* in rats. *Indian J. Physiol. Pharmacol.*, 39(1): 59-62.
- Liu M, Xu X, Rang W, Li Y, Song Y (2004). Influence of ovariectomy and 17 β -estradiol treatment on insulin sensitivity, lipid metabolism and post-ischemic cardiac function. *Int. J. Cardiol.*, 97(3): 485-493.
- Mahmoud MR, El-Abhar HS, Salch S (2002). The effect of *Nigella sativa* oil against the liver damage induced by *Schistosoma mansoni* infection in mice. *J. Ethnopharmacol.*, 79(1): 1-11.
- Martin L., Finn CA, Trinder G (1973). Hypertrophy and hyperplasia in the mouse uterus after oestrogen treatment: an autoradiographic study. *J. Endocrinol.*, 56: 133-144.
- Nagi MN, Mansour MA (2000). Protective effect of thymoquinone against doxorubicin induced cardiotoxicity in rats: A possible mechanism of protection. *Pharmacol. Res.*, 41: 283-289.
- Nair SC, Salomi MJ, Pannikar B, Pannikar KR (1991). Modulatory effects of *Crocus sativus* and *Nigella sativa* extracts on cisplatin-induced toxicity in mice. *J. Ethnopharmacol.*, 31(1): 75-83.
- Niwa K, Morishita S, Hashimoto M, Itoh T, Fujimoto J, Mori H, Tamaya T (1998). Effects of tamoxifen on endometrial carcinogenesis in mice. *Jap. J. Cancer Res.*, 89: 502-509.
- Oropeza MV, Orozco S, Ponce H, Campos MG (2005). Tofupill lacks peripheral estrogen-like actions in the rat reproductive tract. *Reprod. Toxicol.*, 20: 261-266.
- Overk CR, Booth NL, Yao P, Burdette JE, Nikolic D, Chen S, Bolton JL, Breemen RB, Pauli GF, Farnsworth NR (2007). The Chemical and Biological Profile of a Red Clover (*Trifolium pratense*) Phase II Clinical Extract. *J. Altern. Complement Med.*, 12(2): 133-139.
- Parhizkar S, Latiff L, Rahman S, Dollah MA (2011) Assessing estrogenic activity of *Nigella sativa* in ovariectomized rats using vaginal cornification assay. *Afr. J. Pharm. Pharmacol.*, 5(2): 137-142
- Parhizkar S, Rashid I, Latiffah AL (2008). Incision Choice in Laparotomy: a Comparison of Two Incision Techniques in Ovariectomy of Rats. *World Appl. Sci. J.*, 4(4): 537-540.
- Rimoldi G, Christoffel J, Wuttke DS, Jarry H, Wuttke W (2007). Effects of Chronic Genistein Treatment in Mammary Gland, Uterus, and Vagina. *Environ Health Perspect.*, 115(S1): 62-68.
- Silverberg SG (2000). Problems in the differential diagnosis of endometrial hyperplasia and carcinoma. *Mod. Pathol.*, 13: 309-327.
- Suzuki KM, Isohama Y, Maruyama H, Yamada Y, Narita Y, Ohta S, Araki, Y, Miyata T and Mishima S (2008). Estrogenic activities of Fatty acids and a sterol isolated from royal jelly. *Evid Based Complement Altern. Med.*, 5(3): 295-302.
- Swamy SMK, Tan BKH (2001). Extraction, Isolation and Characterization of Antitumor Principle, α -hederin from the seeds of *Nigella sativa*, *Planta. Medica.*, 67: 29-32.