

Full Length Research Paper

Minimally invasive reproductive techniques in Arabi Ewes: A study on laparoscopic intrauterine artificial insemination and ultrasonic pregnancy monitoring

Abdalbari A. Alfaris*, Tahir A. Fahid, Baqer Ja'fer and Hassan Al-Dahabi

Department of Internal, Preventive Medicine, Surgery and Obstetrics, College of Veterinary Medicine, University of Basrah, Basrah, Iraq.

Accepted 26 November, 2022

Laparoscopic intrauterine artificial insemination (LAI) refers to a special technique by which the operation is done through several small holes in the abdomen with the aid of telescope. These incisions are much smaller than wound required in traditional surgery. This study aimed to evaluate the efficacy of laparoscopic artificial insemination. To increase the pregnancy and twins rate by using gonadotrophic releasing hormone (GNRH) and accurate pregnancy diagnosis in ewes by using ultrasonography, the present study was carried out in the animal farm college of veterinary medicine/Basrah University. This study started in 3rd August 2009 to 12th February 2010. This study included 9 ewes aged about 8 to 10 months and 2 rams aged between (9 to 11 months) and one of them was vasectomized. The rams were kept and separated from ewes for 2 weeks; at the beginning all ewes were checked for previous pregnancy by using of laparoscope. Injection of 0.00421 mg Buserelin hormone was given to induce estrus. The estrus ewes were prepared for surgical operations and made sedation by injection of Xylazine 0.11 to 0.22 mg/kg body weight (BW); and then 1 ml/cm² of 2% of lidocaine was injected as local anesthesia. The animal was fixed on surgical table and then prepared for aseptic technique; after which the ewes were inseminated laparoscopically by intra uterine injection of 0.25 ml of fresh ram semen. The results show the possibility of laparoscope as a technique used for artificial insemination in ewes in 71.4% of pregnancy rate. The laparoscopic insemination was successfully done in ewes without complication; there was no critical effect of intra-abdominal pressure (14 mmHg) by CO₂ in small ruminants and pregnancy rate in ewes was successfully diagnosed by ultrasonography.

Key words: Laparoscopic surgery, artificial insemination, ultra sonic, estrus, pregnant diagnosis.

INTRODUCTION

For many years, artificial insemination of ewes was thought to be impractical mainly due to difficulties of detecting estrus and controlling the ewes estrus cycle. The inability to freeze ram semen was another factor that limited a wider use of artificial insemination (Al-Saadi, 2001). However, today, with the use of hormones such as progesterone and pregnant mare serum gonadotropin (PMSG) and other reproductive hormones, the synchronization of estrus in ewes is possible; in addition to that

to that ram semen can now readily be frozen which open the door for interstate as well as international movement of semen (Yanmaz et al., 2007). Even with these technological breakthroughs, the conception rate after artificial insemination in ewes was relatively low and therefore it was not practical for commercial use; then laparoscope was used in artificial insemination in ewes by direct manipulation of semen into the uterine horn as a means of genetic improvement (Dally, 2008). Routine intra cervical insemination could not be use in ewes because of some difficulties due to the anatomical structure of the cervix which consist of 5 cartilaginous rings that have an irregular opening between each of them (Al-Shaikhali et al., 1989) thereby making the introduction of inseminating

*Corresponding author. E-mail: vetedu2000@yahoo.com. Tel: (00964)780-4077140.

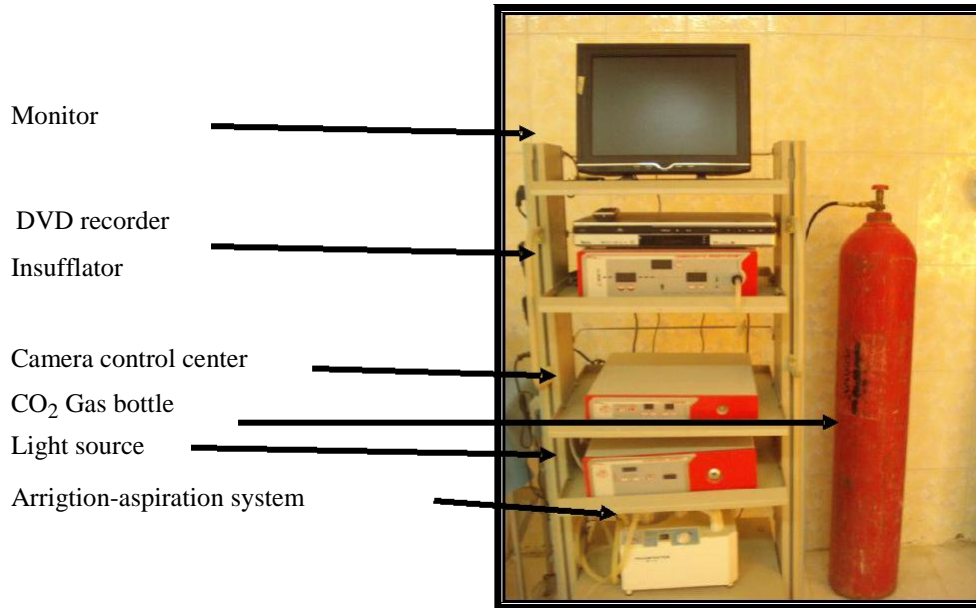


Figure 1. Complete Laparoscope.

introduction of inseminating gun very difficult. In addition to the vaginal PH, estrus period tend to be more acidic due to the effect of estrogen hormone; therefore, the deposition of semen in the vagina will kill a large number of spermatozoa, so laparoscopic device is a favorable method for artificial insemination in ewes with no difficulties (Youngquist and Threlfall, 2007).

Laparoscopy

This is a medical procedure used for examining the interior of the abdominal or pelvic cavity. For examination, the telescope inserted through skin incision (about 0.5 to 1 cm length) consists of fiber – optic camera's head or surgical head (Freeman, 2006). The problems that can be diagnosed or treated by laparoscopy are female infertility, adhesions, diseases of urinary system and other operations of the female reproductive system. Before laparoscopic surgery, open surgery was the common method performed through a very long incision which required nursing the animal for 7 days post-operation and 2 to 6 weeks for complete return to its normal conditions (Bonev et al., 2006). Nowadays, many of the abdominal and pelvic surgery are done by laparoscopy (Ameen, 2006). Prior to laparoscopic insemination estrus, synchronization can be performed by using different kind of hormones which have direct physiological effect on the female reproductive system. The synchronization or induction of estrus is helpful in controlling estrus cycle and inducing of estrus in a period out of breeding season (Danko, 2007). Because the estrus period in ewes is 1 to 3 days (Robert, 1971), it

may not be observed without presence of male so that a teaser male is necessary for detecting the estrus in ewes (McKelvey et al., 1985).

The aims of the present study were as follows: Evaluating the efficacy of LAI on the pregnancy rate and prolificacy of ewes inseminated with fresh ram semen, to increase the pregnancy and twins rate by using gonadotrophic releasing hormone (GNRH) and accurate pregnancy diagnosis in ewes by using ultrasonography.

MATERIALS AND METHODS

The present study was carried out in the animal farm college of veterinary medicine/Basrah University. The study started in 3rd August 2009 to 12th February 2010. Nine sexually matured ewes aged about (8 to 10 months), with 2 rams (9 to 11 months) were used in this study and these animals were obtained from the field of the College of Veterinary Medicine/University of Basrah. The ewes were inseminated laparoscopically with the assistance of hormones (Receptal)[®] to induce estrus (waiting normal estrus); the rams were housed separately from the ewes in animals farm while nutrient (barley) and drinking water were provided for the studied animals twice a day along working time. The complete Laparoscope System (Allgaier instrument GmbH Company, Germany) Figure 1 was used for several abdominal operations. It is an electrical device used to stop bleeding inside the abdominal cavity and during skin opening, Figure 2 (Allgaier instrument GmbH Company, Germany).

Ultrasonographic device

It consists of two parts:

The main unit

It contains of a key board with numbers that can be fixed on the



Figure 2. Electro Cutery.

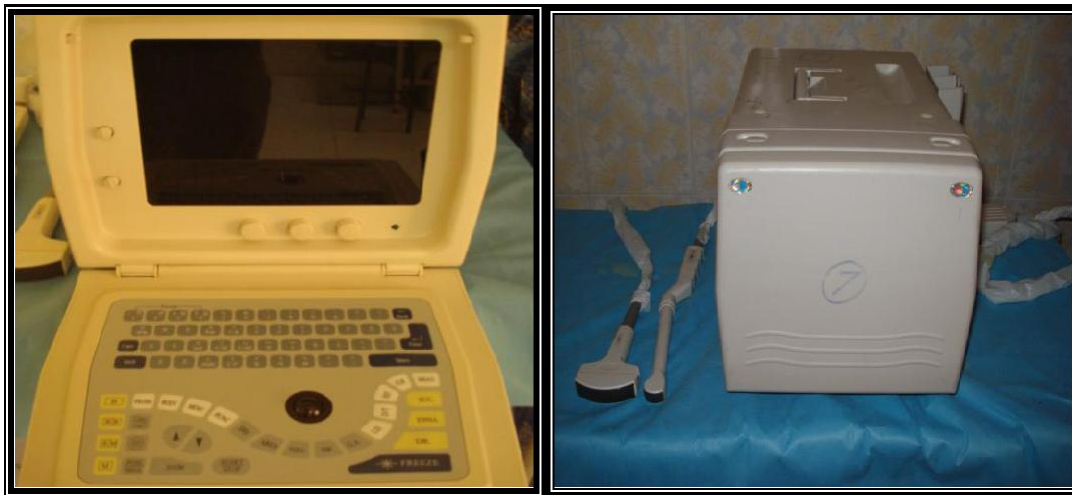

Figure 3. Ultrasonographic device.

monitor to write the history and number of the animal; it is also capable of capturing the image in order to save it, Figure 3 (Sanyo Company, made in China). The probe is connected with the main unit by a special cable (1.5 m); there are two types of probes, one is designed to test pregnancy per rectum and the other is designed to make diagnosis from abdominal wall with the type of liner 5 MHz (Al-Rawi, 2005). Before laparoscopic artificial insemination, the estrus of the ewe was detected by using teaser ram, the ewes were separated away from the male for 10 days then the vasectomized male was placed with the female only in period of estrus detection. All ewes (non pregnant ewes) were treated with a hormone of (receptal) Buserelin Acetate 0.0042 (intervet. B.V. Boxmeer, Holland); this hormone have a GnRH action (stimulate the pituitary gland to produce FSH and LH hormones to induce ovulation then induce estrus within 7 to 12 days after administration (Herbert, 2005). The dose needed to induce estrus was 2.5 ml/animal Intra Muscularly, each milliliter containing 0.0042% of Buserelin Acetate hormone. When the estrus of the ewe was detected, it was deprived of food for 24 h and water for 12 h; then the abdominal region was prepared for aseptic surgery by clipping, shaving and then the area was disinfected by 5% tincture iodine after fixing the animal on surgical table, Figure 4 (Riebold et al., 1983).

Premedication of 0.11 to 0.22 mg/kg BW of xylazine was injected intra muscularly, after that local infiltration was made by injection of

1 ml/cm³ of 2% lidocaine subcutaneously as a mean of local anesthesia only at the site of opening (introduce the trocar). This method was enough to control the pain during the operation (Sahnrey and Holtz, 2005).

Semen collection

The semen was collected by an artificial vagina (AV); the AV was partially filled with hot water at 60°C to provide suitable environmental temperature of 40 to 45°C. Sunflower oil was used to lubricate the first third of AV to facilitate the entrance of male penis. Training was done 2 weeks before operation in order to get semen with natural ejaculated characters; also, provide a good dait to the male 12 h before collection to make sure a good semen quality was gotten (Donovan et al., 2001).

Semen evaluation

After the collection of the semen, it was kept in water bath in temperature of 37°C and a sub sample was taken to make evaluation.

i) The volume and color of semen was assessed at the time of

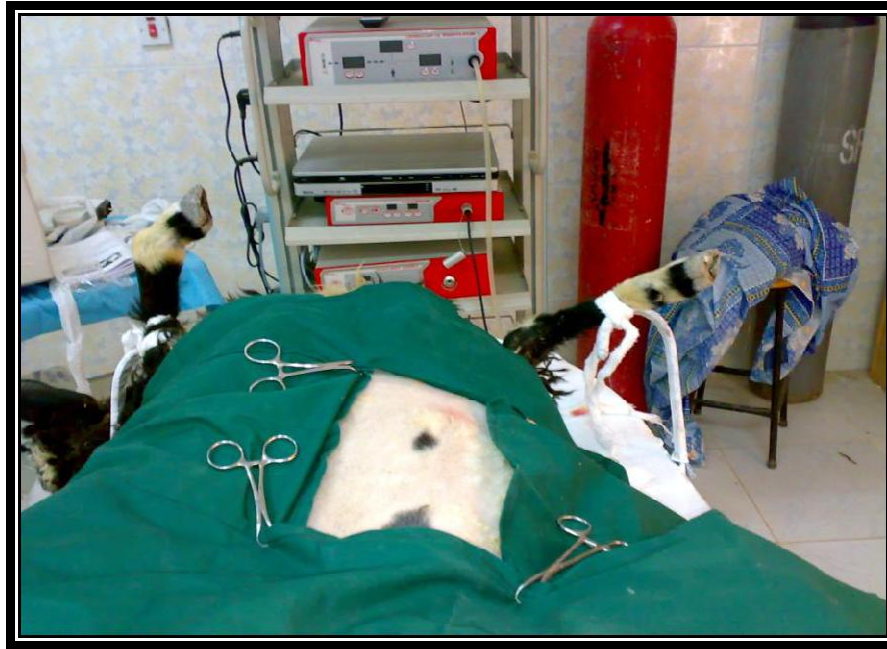

Figure 4. Surgical preparation of animal.

collection (by calibrated collecting tube).

ii) The massive motility was assessed by placing a drop of semen on clean, warm (37°C) microscope slide without a coverslip and the wave motion is observed at low power (40X) (Rawling et al., 2000).

iii) The individual motility was assessed by placing one drop of semen on clean, warm (37°C) microscope slide covered with coverslip and the individual motility was observed under low power (40X).

iv) The morphology of spermatozoa are assessed by placing 1 to 2 drops of stain and a small drop of semen separately on one end of clean, warm (37°C) glass microscope slide. The semen and stain should be mixed and drawn out with the edge of another slide which serves as a spreader to make a thin film.

Semen concentration

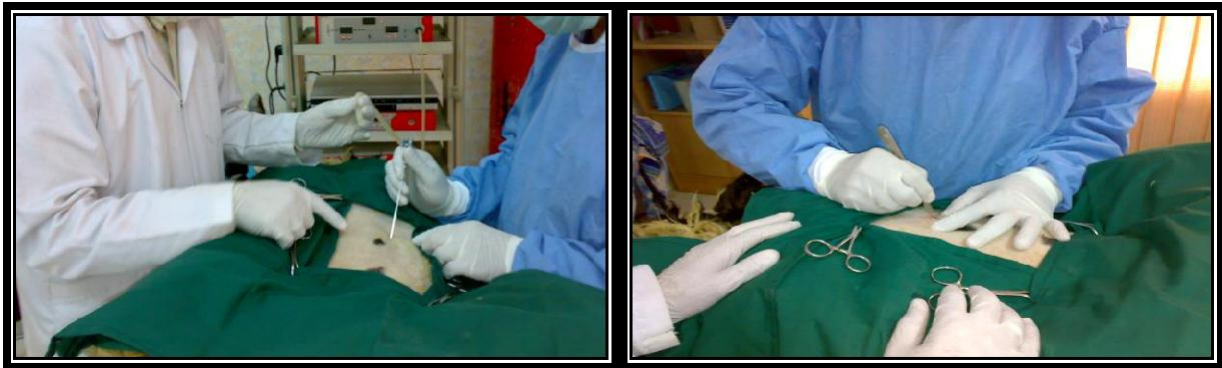Semen concentration represents the number of cells in each ejaculate. By using red pipette of haemocytometer device, the semen was suck up to 0.5 marks, the normal saline solution drawing to 101 then mixing for 5 min, one drop placed on Haemocytometer chamber covered with cover slide after allowing the first drop to down out. The smear was allowed to dry before examination using the high power magnification and counting at least 100 spermatozoa from different field on the slide (Beardon and Fuquay, 1980). Vasectomy (removal of a segment of ductus deferens to render a male animal infertile), vasectomy is usually performed with the aid of local block by 2% lidocaine at the site of operation then make an incision about 2 cm on the neck of scrotum cranially on both side of scrotum. The skin and tunica vaginalis were incised; the ductus deferens is located by palpation because it is firmer than surrounded tissue. Care should be taken to identify the ductus deferens through blunt dissection and remove 3 cm piece of it after 3 to 0 absorbable ligatures had been placed on each end, the procedure is repeated on the opposite side.

Finally, the skin was legated by simple interruption using 2 to 0 non absorbable suture materials as reported by Fubini and Ducharme (2004).

Laparoscopic intra uterine artificial insemination

A veress needle was penetrated into the abdominal cavity at the umbilical region; the CO₂ supplying tubes are connected with veress needle then infuse CO₂ gas to the abdomen at the level of 14. At this degree, the abdominal distention was acceptable to the operation (Donovan et al., 2001) Figure 5a and b. The veress needle is then removed and very small incision is done on the skin (about 0.5 cm), the trocar and sleeve 11 mm introduced at the site of incision (penetrating all the abdominal wall layers even the peritoneum (Figures 3), the CO₂ supplying tube was reconnected but this time at sleeve 11, the Telescope (30) introduced through sleeve 11 extending caudally right or left side of pelvic cavity. When uterus was detected, the Telescope is fixed by an assistant. Another incision was done in the abdominal wall just above the uterus, trocar and sleeve (5.5) introduced in the abdomen and the inseminating gun pushed through the sleeve 5.5 reaching the uterine horn. Sometimes we need to make another opening with another sleeve 5.5 to introduce a grasper to make hold of the uterus. One inseminating dose of 0.1 fresh semen containing 180 million spermatozoa was deposited directly into one uterine horn by using inseminating gun (Gourley and Riese, 1990). After that the instruments were removed and the CO₂ gas was evacuated from the abdomen and 2 stitches of interrupted horizontal mattress suture with 2.0 silk was applied at the site of incision. There was no need for using an antibiotic in this operation (Maxwell and Hewitt, 1986).

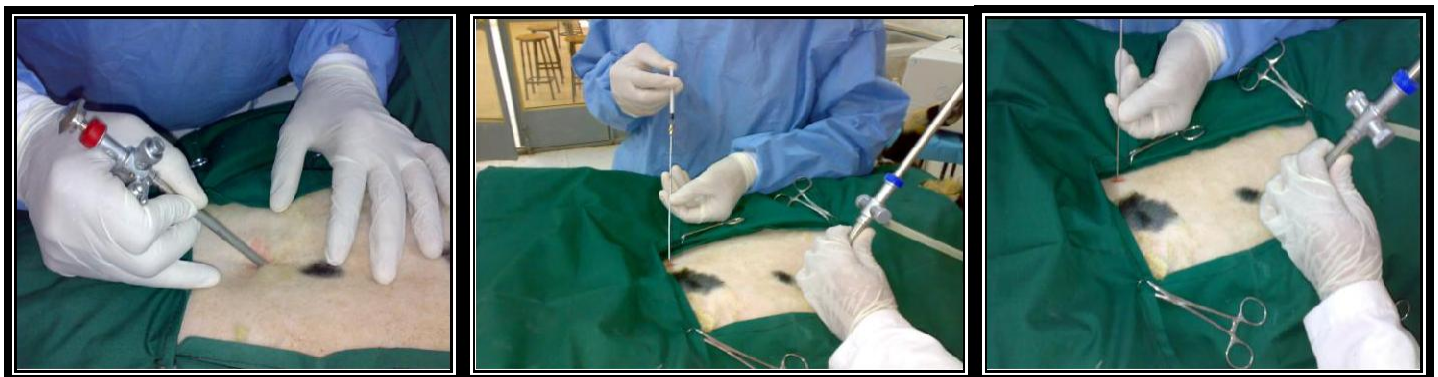
Inside the abdominal cavity the procedure of laparoscopic insemination was assessed in (Figure 6 a, b and c). All animal were kept under observation and good food provided two times/day along the period of the study, good management was taken to maintain the healthy state of the animal (Owolabi et al., 2000). It was made by using ultrasound technique on the abdominal wall, wool was shortened from the abdomen from flank 8 to flank 10 cm in front of the udder (Figures 7). The ultrasonic probe was passed along this line toward the reproductive tract. Positive diagnosis was based on the presence of allantois or the heart beat within the embryonic vesicle during 16 to 90 days of gestation (Al-Rawi, 2005). In this study, the accuracy of the pregnancy diagnosis



(a)

(b)

Figure 5. (a) Introduction of veress needle; (b) Made small incision on skin.



(a)

(b)

(c)

Figure 6. (a) Introduction of Sleeve 5.5; (b) Introduction of Sleeve 11 and Telescope; (c) Introduction of inseminating gun.

was done at 70 days post insemination. The animals were placed at the table after preparation (cleaving and shaving of abdominal wall), the head forelimb tends upward and the hind limb and the back tends downward then examined by placing probe on the abdominal wall (Karen et al., 2003), (Figure 8 a, b and c).

RESULTS AND DISCUSSION

At first and before laparoscopic insemination, all (9) ewes of the study tested in the time of 10 to 12 days after introduction into the farm by using of laparoscopic pregnancy diagnosis, the results showed (2) pregnant ewes and these animals were left as the control, while the other (7) ewes showed no pregnancy, therefore it was prepared for laparoscopic insemination (Table 1). Most of the ewes showed estrus signs after a single dose of 2.5 ml of

Receptal[®] hormone (Buserelin Acetate 0.0042 mg) within 8 to 12 days post administration. The ewes number (4 and 9) were not treated with hormone because they were pregnant normally before the operation. Ewe number 7 did not show signs of estrus after one dose; it was re-injected after 10 days with the same dose with the estrus signs been noticed. Clinical sings of estrus ewes were observed with the help of teaser, the ewes locked to the male with sexual desire; teaser ram follow the estrus ewes after smelling hormones that was released from estrus ewe and attempted to mount. The results of administration of GnRH hormone caused induced estrus; this result is in agreement with Youngquist and Threlfall (2007) and Arthur (1998) when they reported that the GnRH hormone stimulate the interior lobe of pituitary gland to produce FSH and LH hormones; by positive feedback the level of estrogen increase and then the

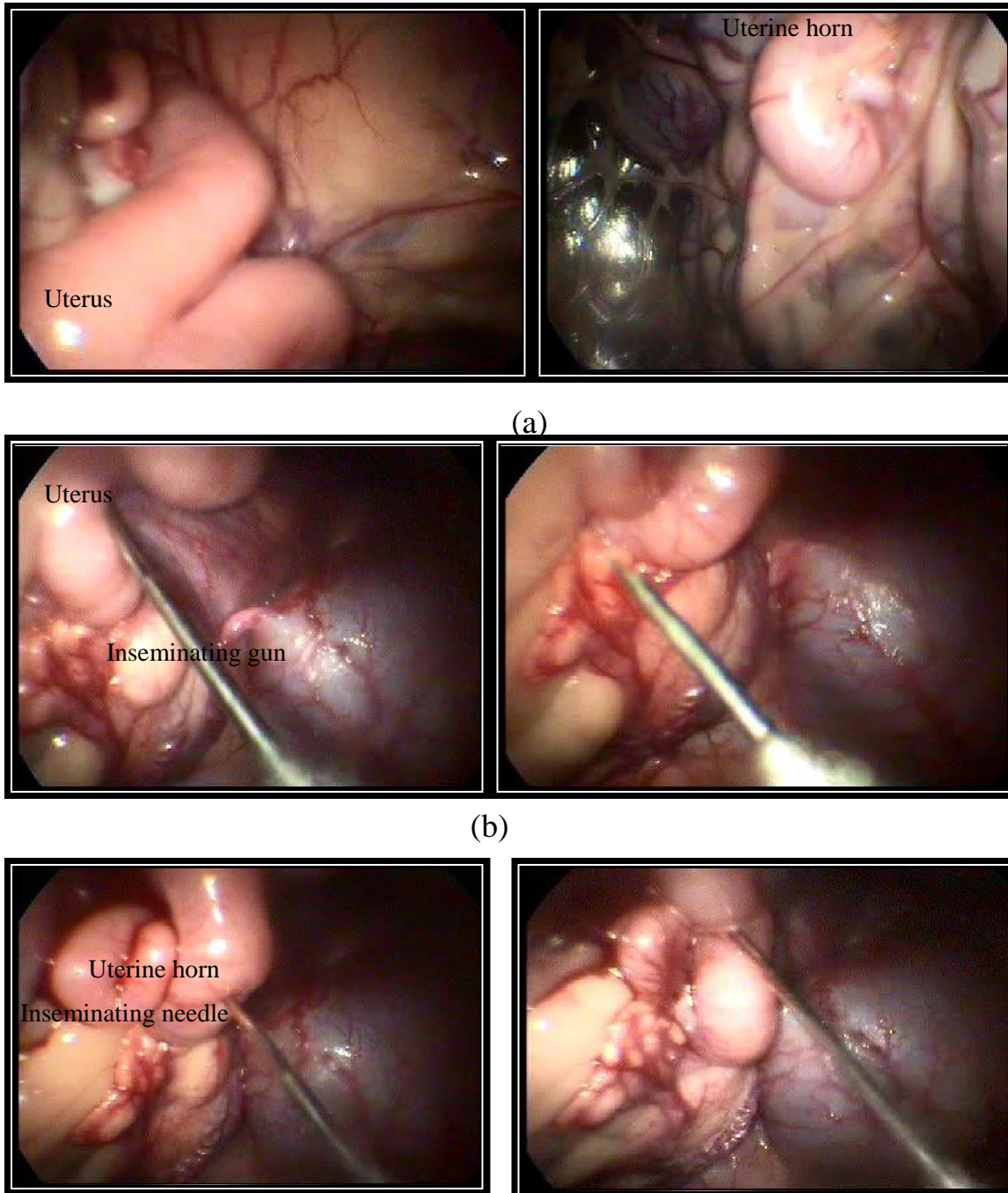
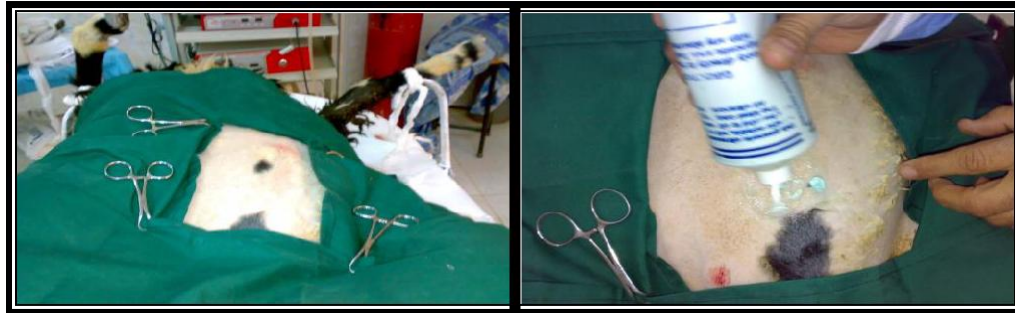

Figure 7. Insemination procedure. a- Uterus visualization, b- Introduction of needle , c- Insemination technique.

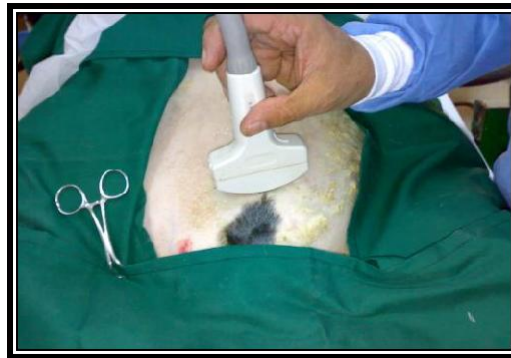estrus signs begins. The estrus signs appeared within the range of 8 to 12 days after GnRH administration. The result is in agreement with the study of Padula and Macmillan (2005) when they reported that the estrus signs appear 7 to 12 days after GnRH treatment due to stimulate release of estrogen hormone from the graafian follicle (Table 2).

The induction of estrus took 7 to 12 days after treatment with GnRH hormone. This maybe because of the normal single wave of the growing graafian follicle which need 7 days to reach maturity that had direct effect on the pituitary gland to release the FSH hormone responsible for the follicle development and LH hormone which is responsible for ovulation. The result of estrus induction



(a)

(b)



(c)

Figure 8. (a) Preparing of animal; (b)-placing of Sonogel C- movement of probe on abdominal wall.

Table 1. Time of pre operative pregnancy diagnosis starting from the 10th day of introduction of ewes into the animal farm.

Time of introduction in the animal farm	Time of testing	Result
3/8 / 2009	13/8/2009	**Negative
3 /8 / 2009	13/8/2009	Negative
3 /8 / 2009	13/8/2009	Negative
3 /8 / 2009	13/8/2009	*Positive
3 /8 / 2009	14/8/2009	Negative
3 /8 / 2009	14/8/2009	Negative
3 /8 / 2009	15/8/2009	Negative
3 /8 / 2009	15/8/2009	Negative
3 /8 / 2009	15/8/2009	Positive

*(+ve) = pregnancy, while the **(-ve) = not pregnant.

by using GnRH hormone agrees with the study of (Kridli and Al-Khatib, 2006) when reported; the behavior of estrus was checked using a fertile ram at 6 h interval for 5 days starting from the 7th day of administration of GnRH. The estrus ewes could not be diagnosed well when the teaser ram was not present, so the teaser ram

played an important role in the diagnosis of estrus in ewes. According to Table 2, the result showed some variation in the time of estrus induction after single dose of GnRH hormone, these differences may be due to the number of times of hormonal administration in different period of estrus cycle. The result agrees with the study of

Table 2. The dose and hormonal administration, the time of estrus signs of 9 ewes.

Dose (ml/animal)	Time of estrus detection
2.5 ml of (Receptal) [®]	10 days after administration
2.5 ml	8 days after administration
2.5 ml	10 days after administration
Not injected	12 days after administration

The semen morphology : after preparation of slides staining with Eosine stain ,the normal morphology of spermatozoa was pronounced (the head had a bilateral ovoid shape contain an acrosome on the tip of head , normal mid piece and normal long tail) (Fig.-9).

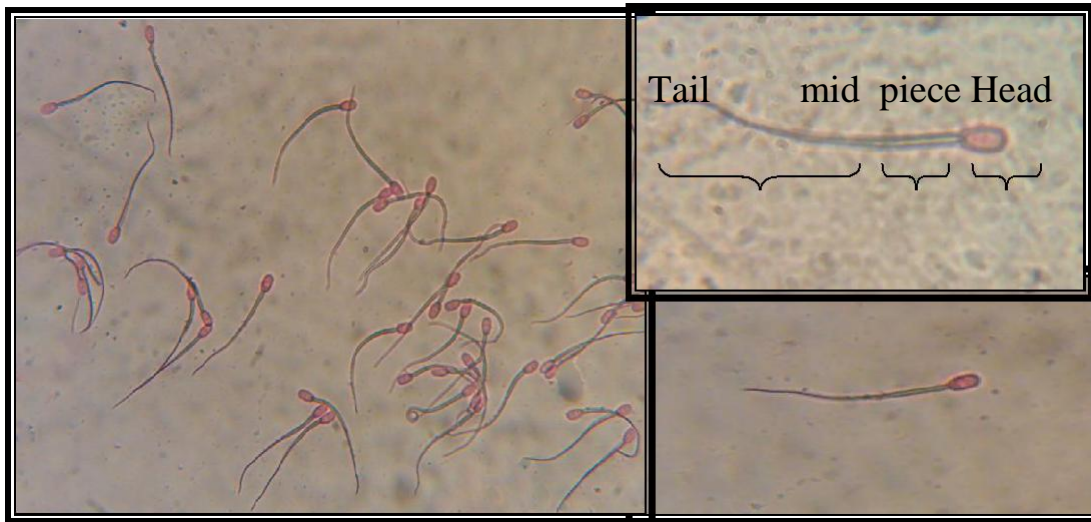

Figure 9. The morphology of sperm cell stained with eosine stain 1.6% (100x).
 Figure 9: The Morphology of sperm of sperm cell stained with Eosine stain 1.6% (100X)

Peters (2005) who injected the GnRH hormone few days

estrus period and improve conception rates.

The semen morphology

After preparation of slides staining with Eosine stain, the normal morphology of spermatozoa was pronounced (the head a bilateral ovoid shape contained an acrosome on the tip of head, normal mid piece and normal long tail) (Figure 9).

Semen concentration (Sc)

The concentration of semen was measured by using Haemocytometer chamber by calculating 5 main large square (4 in corners and 1 in center). The result of the semen concentration was 3450×10^6 spermatozoa per each milliliter of fresh ram semen as follows:

Semen concentration (Sc) = $\frac{\text{No. of sperm in 80 small square} \times \text{dilution rate}}{80 \times \text{volume of small square}}$ before ovulation to accelerate the

No. of sperm in 80 small square = $83 + 78 + 64 + 58 + 62 = 345$

$Sc/mm^3 = \frac{345 \times 1/200}{80 \times 1/4000} = 10000 \times 345 = 3450000$ (sperm in mm^3)

In order to calculate the no. of sperm/each milliliter, the result must be multiplied with 1000.

So the result was = $3450000 \times 1000 = 3450 \times 10^6$ (sperm/ml of fresh semen).

So the dose of 0.1 ml of fresh semen was used to inseminate each ewe containing 345×10^6 spermatozoa.

Semen deformity

The percentage of sperm deformities did not exceed 5%,

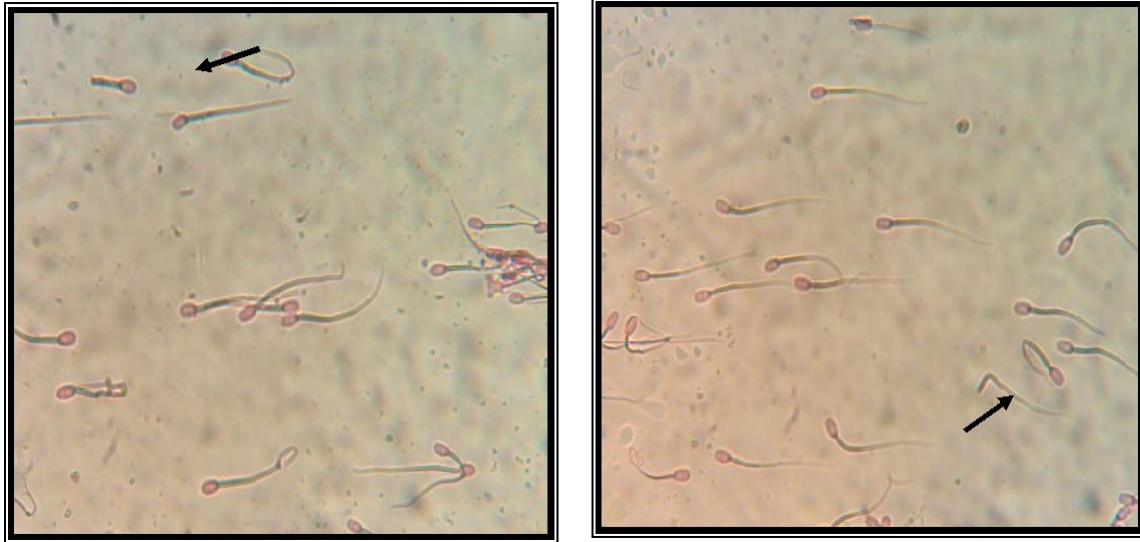


Figure 10. Sperm deformality; the left pointer refer to sperm with head only while the right pointer refer to sperm with tail only (100x).

most deformities were from secondary deformation and there were no aspects of primary deformation, this gave more accuracy about the good semen quality which was used in this technique (Figure 10). The present study demonstrated that the volume of semen collected by artificial vagina varied and ranged from 0.8 to 1.2 ml of fresh semen which is in agreement with Al-Saadi (2001) who reported that the volume of fresh semen ranged from 0.8 to 1.5 ml/each ejaculate. This variation in volume may be due to many factors such as nutrient, healthy state, breed, number of semen collection/day, breed; these factors reported by Donovan et al. (2001) as factors which have effect on the semen volume. The result of semen color was white creamy which represented that the semen had a good quality as reported by Donovan et al. (2001) when they reported that the normal color of ram semen was white – creamy, any variation in this color indicate abnormal semen or semen with bad quality. The result agreed with Ameen (2006) which reported that the white – creamy color is the normal color of ram semen, any other color will give indication of unfavorable semen. Figures 9 and 10 refer to the individual semen motility, the result of individual motility rate ranged from 90 to 100%, this means that all sperm cell were motile and the dominant motility were the progressive forward motility which either gave another good character for semen that was used in LAI.

The result of laparoscopic insemination by penetration of the abdomen did not show any clinical complication observed during the anesthesia, operation and even post operation. During these operations the ewes did not require any course of antibiotic as like in routine surgical operations which need long course of penicillin may extend to 5 to 7 days (during the laparoscopy, the

abdominal content was not exposed to external air so the infection with bacteria or viruses or other micro-organism is rare because the equipment were cleaned and disinfected with standard formalin about 24 h before the operation. The result agrees with Yanmaz et al. (2007) who reported that the laparoscopic surgery in animal may not require an antibiotic and the animals returned to their normal activity just about few minutes post operation, it starts to feed and drink normally when the effect of anesthesia disappeared. The results agree with Immanuel (2002) who showed that the animal returned to normal activity after laparoscopic operation immediately. The complete healing of the abdominal opening occurred after 7 days post operation (the healing effected by heat and cold, increase temperature accelerate the wound healing, the small aged animal heal faster than big one). The result agrees with McKusick et al. (2000) when they reported the advantages of laparoscopic insemination, they said that the complete healing of abdominal openings occurred after 7 days after operation, the result did not agree with Youngquist and Threlfall (2007) whom reported that the complete healing after laparoscopic insemination in ewes ranged from 8 to 12 days due to different factors interfering with healing process.

The results show the possibility of using the laparoscope as a technique used for artificial insemination in ewes. The result agrees with Donovan et al. (2001), McKusick et al. (2000), Lymberopoulos et al. (1999), Ehling et al. (2003), Tanahatue et al. (2005), Avendano-Reyes et al. (2007) and Al-wataar et al. (2009); they reported that laparoscopic artificial insemination could be used as a technique for genetic improvement of sheep breeds. By clinical signs and use of ultrasonography, the diagnosis can easily be made after the first 70 days of

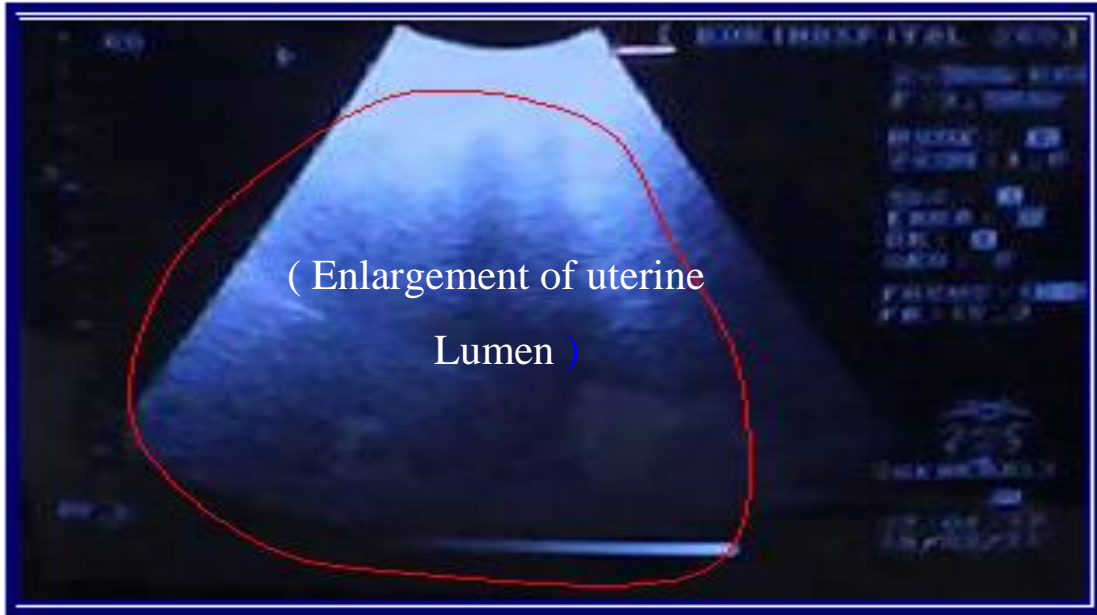


Figure 11. Fetus about 70 days of gestation .

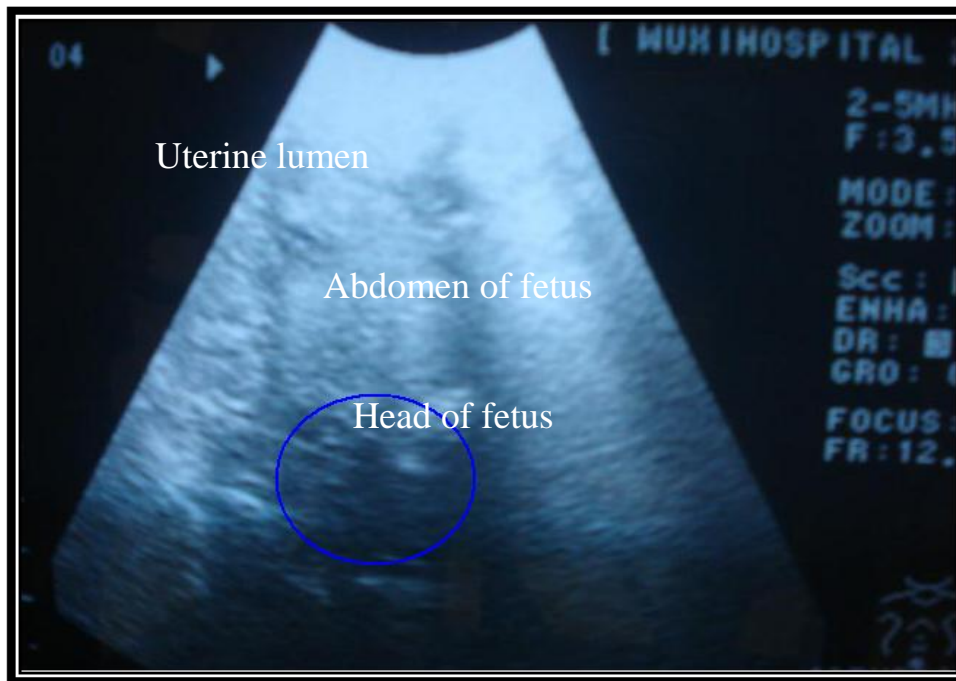


Figure 12. Fetus inside dam uterine lumen up to 90 day of pregnancy.

of gestation (Figures 11 and 12). The tests of pregnancy diagnosis was performed by the use of ultrasonography of the pelvic region depending on the presence of fetus or enlargement of uterine lumen, and also the pregnancy could diagnosed according to the clinical signs of pregnant ewe which were clear enlargement of abdomen, enlargement of udder specially at the last month of gestation, the external genitalia appeared pale and relaxed,

arching of back, the ewe did not except the male (not respond to the natural mount). The result of pregnancy diagnosis after LAI in ewes were described when 7 ewes inseminated laparoscopy, 5 of these ewes showed pregnancy while 2 of them showed negative result of pregnancy test. The test used in the diagnosis of pregnancy in ewes after LAI was done is the ultrasonographic device. The time of pregnancy diagnosis occurred

occurred 70 days after insemination, in this period of time the fetus was observed clearly.

The results agree with Karen et al. (2003) who said that ultrasonic techniques accurately detect pregnancy during the second half of gestation and agree with McKusick et al. (2000) who used ultrasonography to diagnosis pregnant ewes for 60 to 61 days after LAI. The result is not in agreement with Danko (2007), Al-Rawi (2005) and Hussain (2005) who reported that real time ultrasound scanning could detect pregnancy as early as 23 days of gestation by the rectal route and after 40 days of gestation by external trans-abdominal route. The pregnant ewes showed many clinical signs that reflex the activity of pregnant ewes during gestation like enlargement of udder specially during late gestation, pale mucous membrane of external genital opening and enlargement of abdomen and the fetus could be felt by gestation of abdomen in the area toward udder from mid line of the abdomen, this method of pregnancy test can be classified as less practical method for pregnancy diagnosis which agree with Karen et al. (2003).

Pregnancy rate

After laparoscopic insemination of 7 ewes from the total number of 9 ewes, according to the aim of this study, it was important to estimate the pregnancy rate of this method and to know the capability of laparoscope in insemination of ewes artificially. The results show percentage of 71.4% pregnancy in ewes inseminated laparoscopically as shown in Table 3. The results agree with Al-wataar et al. (2009), they reported that the pregnancy rate after laparoscopic insemination was 71%. The result nearly agrees with Ehling et al. (2003) and Scudamore et al. (1991), they reported a range of 72.6 to 73.8% and $72 \pm 24.6\%$ respectively for LAI. These results are not in agreement with Windson et al. (1994), Hill et al. (1998), Lymberopoulos et al. (2001) and Romano et al. (2002); they reported variable pregnancy ranges which were 48, 79, 81, 82 and 62.8%, respectively. This variation may be due to the variation in the number of the animals used, interior studies even variation in breed and the season of study. The present study used fresh semen for laparoscopic insemination with the results of 71.4% pregnancy. It was concluded that we can use laparoscope in artificial insemination in sheep with good result of pregnancies. The results of parturition shows that two pregnant ewe died during the period of study due to infection with pulpy kidney disease, the infection came from the other animal in the same farm, the outbreak accrued with clinical sings of sudden death, polypnea, muco-nasal discharge, animal in last stage of disease lying down show tonic convulsion, kidney appeared soft at necropsy with many small white spot on the cortex and enlargement of liver with some hemorrhagic spot on different surfaces of the intestine.

The result also show 3 cases of abortion; all these cases that underwent abortion in the second half of gestation may be due to the same disease (pulpy kidney), the abortion happened as a result of depression of the healthy state of the animal which made stress factors on the fetus lead to falling down of fetus. The result shows that 2 of the ewes show normal parturition after 150 days of gestation, one of them gave twin fetuses.

REFERENCES

- Al-Rawi HM (2005). Clinical uses of ultrasonic technique in reproductive management in ewes. PhD thesis, College of veterinary medicine – Baghdad University, Iraq. pp. 26 – 42.
- Al-Saadi HA (2001). Puberty and artificial insemination. Second Ed., Ministry of higher education and scientific research, College of Veterinary Medicine, University of Mosul. Iraq. pp. 1 - 347.
- Al-Shaikhali AA, Waaal AA, Zuheer ZM (1989). Veterinary anatomy. Second Ed., Part 1, Al-hekmah House. Iraq. pp. 202 – 242.
- Al-wataar BD, Taha MB, Al-Badrany MS (2009). Co-partion of Laparoscopic intrauterine insemination in synchronized Awassi ewes. *J. Iraqi Vet. Sci.*, 22 (1): 53 - 57.
- Ameen HM (2006). Artificial insemination in sheep advantage and disadvantage. (net.www.arabvet.com).
- Arthur GH (1998). Veterinary reproduction and obstetrics, 7th ed. Saunders Company. London, England. pp. 24 – 245
- Avendano-Reyes L, Alvarez-Valenzuela FD, Molina-Ramirez L, Rangel-Santos R, Correa-Caleron A, Cruz-Villegas M, Robinson PH, Rodriguez-Garcia J, Famula TR (2007). Reproduction performance of Pelibuey ewes in response to estrus synchronization and artificial insemination in North Western Mexico. *J. Anim. Vet. Adv.*, 6(6): 807 - 812.
- Beardon HJ, Fuquay J (1980). Applied animal reproduction, 4th ed., Artlisle Publishers Services. USA. pp. 142 - 200.
- Bonev GB, Vassilev NY, Dimitrov MA, Yotov SA, Penchev P (2005). Adjustment of echography and laparoscopic insemination to the reproductive particularities of eleven black head sheep. *Bulg. J. Vet. Med.*, 9(1): 61 – 65.
- Dally RM (2008). Laparoscopic artificial insemination a means to improve genetics. Animal science department, University of California-Hopland field station. (net.www.topram.com).
- Danko GN (2007). Some practical and biotechnological methods for improving reproduction traits sheep. *J. Cent. Agric. Sci.*, 51(4): 22 – 31.
- Donovan A, Hanrahan JP, Lally T, Boland MP, Byrne GP, Duffy P, Ionergan P, O'Neill DJ (2001). Artificial insemination for sheep using frozen-thawed semen. Faculty of Agriculture University, College of Dublin-Belfield, Dublin.
- Ehling C, Wirth P, Schindler L, Hadelar K, Dopke H, Lemme E, Herrmann D, Niemann H (2003). Laparoscopic intrauterine insemination with different doses of fresh, conserved, and frozen semen for the production of ovine zygotes. *Theriogenology*, 60(4): 777 – 787.
- Freeman LJ, Havan AY, Ali AA (2006). Veterinary endosurgery. Mosby Inc., Saudi Arabia. pp. 3 – 45.
- Fubini SL, Ducharme NG (2004). Farm animal Surgery 1st edition. Pat joiner, New York- United State of America. pp. 363 – 264.
- Gourley DD, Riese RL (1990). Laparoscopic insemination in sheep. *J. Vet. Clin.*, 41: 191 - 193
- Herbert CA (2005). Application of GnRH in the control and management of fertility in female animals. *Anim. Reprod. Sci.*, 88(1): 141 – 153.
- Hill JR, Thompson JA, Perkins NR (1998). Factors effecting pregnancy rates following laparoscopic insemination of 28,447 Merino ewes under commercial conditions. *Theriogenology*, 49(4): 697 – 709.
- Hussain KA (2005). The use of ultrasonography in treated ewes progesterone and ECG. MSc. thesis, College of veterinary medicine- Baghdad University. pp. 26 – 63.
- Immanuel K (2002). Laparoscopic surgery. (net.www.acg.gi.org).
- Karen A, Beckers J, Sulon J, Desousa NM, Szabados K, Reiczigle J, Szenci O (2003). Early pregnancy diagnosis in sheep by

- progesterone and pregnancy associated glycoprotein tests. *Theriogenology*, 59: 1941 – 1948.
- Kridli RT, Al-Khatib SS (2006). Reproductive responses in ewes treated with ECG or increasing doses of royal jelly. *Anim. Reprod. Sci.*, 92(12): 75 – 85.
- Lymberopoulos A, Amiridis G, Kuhholzer B, Besenfelder U, Christodoulou V, Vainas E, Brem G (2001). Fertilization and embryo recovery rates in super ovulated chios ewes after laparoscopic intrauterine insemination. *Theriogenology*, 55(9): 1855 – 1862.
- Lymberopoulos A, Kuhholzer B, Amiridis GC, Christodoulou V, Vainas E (1999). Laparoscopic intra uterine insemination in super ovulated Chios breed ewes. *J. Hell. Vet. Med. Soc.*, 50(4): 321 – 325.
- Maxwell WMC, Hewitt LJ (1986). A comparison of vaginal, cervical and intrauterine insemination of sheep. *J. Agric. Sci.*, 106: 191 – 193.
- McKelvey WAC, Robinson JJ, Aitken RP, Henderson G (1985). The evaluation of laparoscopic insemination technique in ewes. *Theriogenology*, 24(5): 519 – 535.
- McKusick BC, Thomas DL, Gottredson RG, Zelinsky RD, Bager YMA (2000). Comparison of transcervical and laparoscopic intra uterine artificial insemination techniques on reproductive performance of ewes. *Theriogenology*, 26(2): 412 – 423.
- Owolabi T, Frcsc MD, Toronto ON (2000). Minimizing risks of laparoscopy. *J. Soc. Obstet. Gynaecol. Can.*, 22(11): 6 - 97.
- Padula AM, Macmillan KL (2005). Restoration patterns for luteinizing hormone and ovarian function following treatment with GnRH agonist implants (deslorelin) for 7, 14 or 21 days in cycling dairy cows. *Anim. Reprod. Sci.*, 87(1-2): 11 – 24.
- Peters AR (2005). Veterinary clinical application of GnRH questions of efficacy. *Anim. Reprod. Sci.*, 88(1-2): 155 – 167.
- Rawling CA, Steven VL, Chris K, Lyn F, Raymond TD, Cheryl G, Adriene C, Fawzi M, Tien-Min C (2000). Laparoscopic intra uterine insemination of ewes with frozen thawed semen. *J. Amer. Assoc. Lapor. Anim. Sci.*, 50(5): 551 - 555.
- Riebold TW, Goble DD, Geiser DR (1983). Anesthesia in veterinary surgery. 2nd ed. Iowa State Press, Ames, Iowa. pp. 22 - 131.
- Robert S (1971). *Veterinary obstetrics and genital disease (theriogenology)*, 2nd ed. Author Ithaca, New York, USA. pp. 36 – 199.
- Romano D, Terzano MG, Didomenico M, LiGato MS, Pertrone A, Desantis M, Covaliere A F, Noia G (2002). Fertility rate evaluation by Laparoscopic approach in the experimental animal. *Clin. Exp. Obstet. Gynecol.*, 29(2): 110 – 112.
- Sahnrey B, Holtz (2005). Transcervical deep corneal insemination of goats. *J. Anim. Sci.*, 83: 1543 - 1548.
- Scudamore CL, Robinson JJ, Aitken PR, Kennedy DJ, Ireland S, Robertson IS (1991). Laparoscopy for intrauterine insemination and embryo recovery in super ovulated ewes at a commercial embryo transfer unit. *Theriogenology*, 35(2): 329 – 337.
- Tanahatoc SJ, Lamalk CB, Hompes PG (2005). The role of laparoscopy in intra uterine insemination. *J. Hum. Reprod.*, 20(11): 3225 – 3230.
- Windson DP, Szell AZ, Bushbeck C, Edward AY, Milton JJB, Buckrell BC (1994). Transcervical artificial insemination of Australian merino ewes with frozen-thawed semen. *Theriogenology*, 42: 147 – 157.
- Yanmaz LE, Zafer O, Elif D (2007). Laparoscopic surgery in veterinary medicine. *Medwell J.*, 1(1): 23 – 39.
- Youngquist RS, Threlfall WR (2007). *Large animal theriogenology*. Second edition. Saunders, Elsevier Inc. USA. pp. 655 - 687.