

*Full Length Research Paper*

# Management of surgical wounds using crude neem oil in one year old ram: A successful report

Bwala D. G.\*, Elisha I. L., Habu K. A., Dogonyaro B. B. and Kaikabo A. A.

National Veterinary Research Institute, P.M.B. 01, Vom. Plateau State, Nigeria.

Accepted 19 September, 2018

Wound healing effect of crude neem (*AZADIRACHTA INDICA* Juss) oil, processed locally from the seed kernel was assessed on septic surgical wound in a one year old Uda ram. A wound approximately 7 cm in diameter created as a result of surgical drainage of abscess on the left caudal part of the elbow joint was flushed with the crude neem oil. A single application of the crude neem oil to the sutured wound resulted in a complete healing after seven days without systemic or topical application of antibiotics. Wound infection and dehiscence were not observed and the animal's appetite improved significantly after the intervention and treatment. Thus, the study reveals crude neem oil may act as a cheaper, more convenient and effective wound healing oil in animals, especially, in the rural areas where veterinary services and/or orthodox chemically-based animal medicaments may not be readily available.

**Key words:** Neem oil, ram, small ruminant, wound healing.

## INTRODUCTION

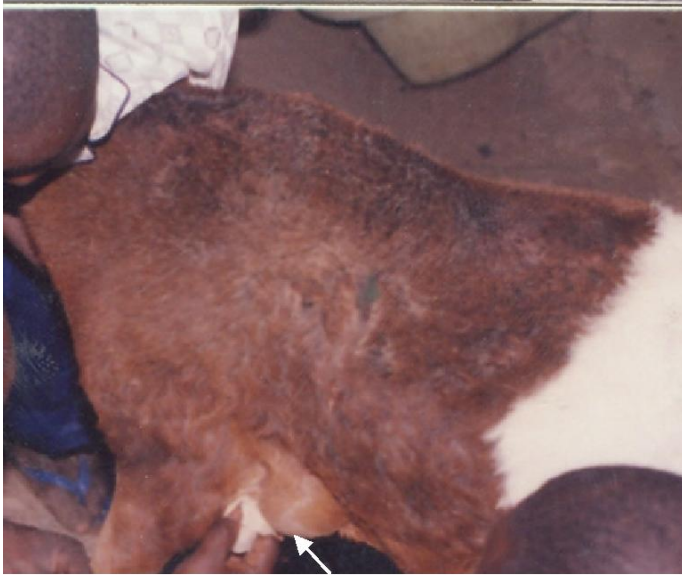Small ruminants (sheep and goats) are one of the major sources of animal protein in Nigeria, and play a very important socioeconomic role in the lives of the people (Opasina and David-West, 1987). High mortality along with low productivity due to prevalent diseases (example, Peste des petit ruminant (PPR), helminthosis, haemoprotozoan infections, skin infections etc), common nutritional disorders and traumatic injuries are a serious setback to small ruminant husbandry in Nigeria (Ojo, 1994). Abscesses cause low productivity among livestock through reduced feed consumption and conversion. Sometimes the production of poisons by invading bacteria into skin lesions and abscesses can cause even mortalities (Brinks et al., 1990; Sargison, 2003; Hassan and Egege, 2004). Abscesses as a result of local collection of pus are mostly caused by any infection (Levy, 2004) as a sequel to penetration through broken surface by pyogenic organisms (Hassan and Egege, 2004).

Wound care using herbal remedies can be traced back to early civilization (Mantle et al., 2001). Fulani herdsmen

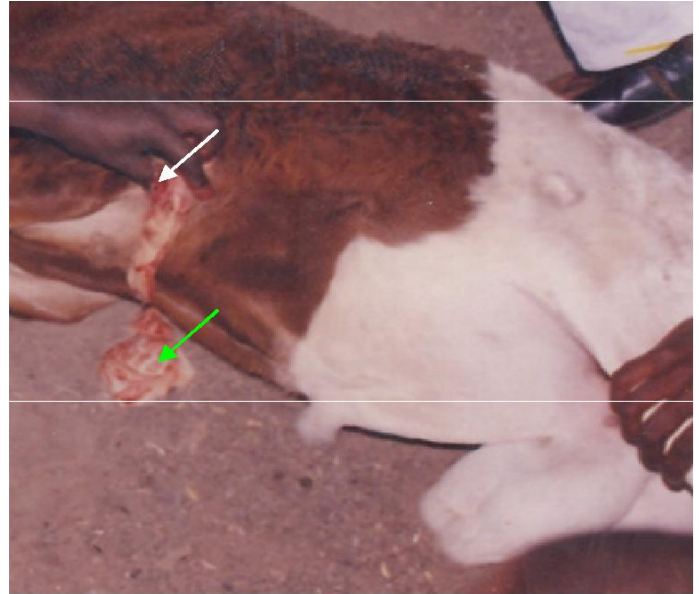
and other natives have been involved in the treatment of animal diseases using herbal remedies before the onset of modern medicine (Nwude, 1986). Approximately one-third of all traditional medicines are used for treating wounds and skin disorders (Abu-Irmaileh and Afifi, 2000; Mantle et al., 2001; Khalil et al., 2007). These plant based products are either used to manage fresh or chronic wounds, and could affect specific phases of wound healing, such as inflammation, coagulation, fibroplasias, collagenation, epithelisation and contraction (Choi et al., 2001; Bairy, 2002; Khalil et al., 2007).

Neem tree (*Azadirachta indica*), a member of the Meliaceae family (Biswas et al., 2002), is grown in many countries of the world including Nigeria (Schumutterer, 1990). It is said to have magical beneficial properties because of its diverse active constituents (Biswas et al., 2002) and has a long history of use in the traditional medical system in India-Ayurvedic *Unani-Tibb* (Schumutterer, 1995). Almost every part: the bark, stem, root bark, young fruits, leaves and seeds are useful in the treatment of different ailments in both man and animals such as fever, digestive problems, intestinal parasites, viral, bacterial and fungal infections, skin diseases, inflammatory diseases, fertility prevention (contraceptive), and as an insecticide (Stix, 1992; Biswas et al., 2002). Today, neem has assumed global importance because it

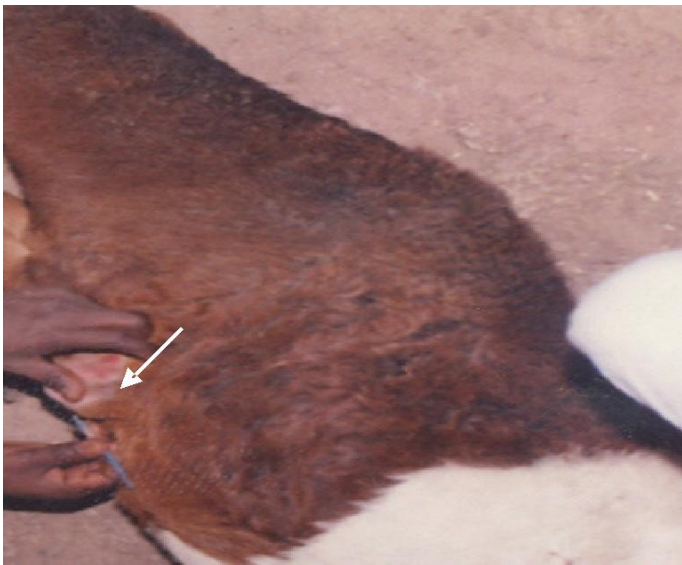\*Corresponding author. E-mail: [dgbwala@yahoo.com](mailto:dgbwala@yahoo.com). Tel: +2348039666479.



**Figure 1.** The abscess – Arrow pointing to the circumscribed swelling.



**Figure 3.** Abscess being expressed after lancing with both arrows pointing to the expressed pus materials.



**Figure 2.** Abscess being infiltrated with Xylocaine before lancing.

offers answers to the major concerns being faced by mankind (Cornborough, 2002). Neem and its products have anti-fungal, anti-bacterial, anti-inflammatory, antiviral, anticancer, antidiabetic and immunomodulatory activities also have been reported to have wound healing properties (Biswas et al., 2002). This case is aimed at reporting the wound healing property/activity of crude neem oil (*A. indica*) in a field situation as there are limited reports on its use in the treatment of septic wounds.

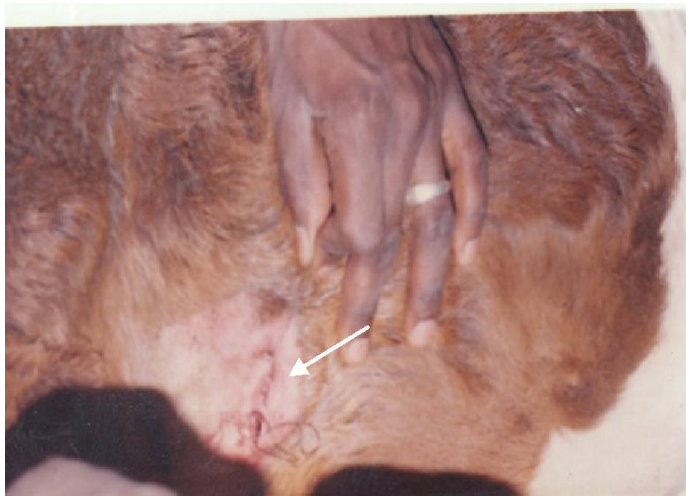## CASE HISTORY

A one year old ram weighing approximately 60 kg of the Uda breed of Sheep was presented to a group of clinicians in Jos, Plateau State, Nigeria, with the principal complaint of swelling on the left side just behind the elbow joint. The owner also complained that the animal has been isolating itself from others, was not feeding well and has been losing weight gradually; lameness of the left forelimb was also reported. The animal was on a fattening ration and intensively managed.

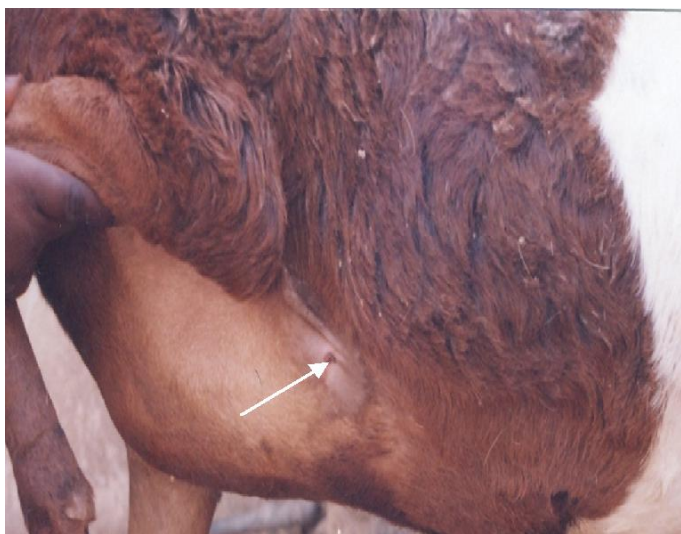Physical examination of the ram revealed a circumscribed swelling of about 7 cm in diameter (Figure 1). The swelling was located caudal to the left elbow joint just below the axilla. It was doughy to touch with a soft fluctuation and pits on pressure. Efforts to aspirate the content using a 5 ml syringe with a 21 Gauge needle yielded no fluid. Rectal temperature was 38.9°C; respiratory rate and pulse rate were 25/min and 80/min respectively. Faecal and blood samples were not collected for laboratory analysis.

## RESULTS

Based on the clinical signs and the physical examination, a tentative diagnosis of abscess was made. Differential diagnoses of haematoma, parasitic nodules and tumour were considered. However, no laboratory diagnosis was carried out to identify the causative organism due to limited facilities under field conditions. The site was prepared aseptically, the area around the incision site was infiltrated with 2% Xylocaine (Figure 2) and using a scapel blade, a straight-line, dorsoventral incision toward the midline was made. The purulent content was pressed and drained (Figure 3). The cavity was cleaned with a sterile cotton wool and then flushed with crude neem oil. The crude neem oil processed locally and manually from



**Figure 4.** Stitched wound – Arrow points to the stitched area with the most ventral aspect of the wound left unstitched for continuous drainage.



**Figure 5.** Healed wound – Arrow points to the scar formed after the wound has healed completely.

the seed kernel was purchased from a local processor/vendor in Gombe State, North Eastern Nigeria. A simple interrupted suture was applied to the wound using a silk non-absorbable suture (Figure 4). The most ventral aspect of the wound was left unsutured to allow for continuous drainage. Crude neem oil was then applied topically to the sutured wound. No repeat application of the neem oil was made and no antibiotic (topical or systemic) was given to the ram or applied to the wound. The animal was then monitored daily for a period of 5 days for re-infection and wound dehiscence. None was observed. Neem oil was found to be highly

effective in wound healing as complete healing with scar formation was achieved within a week without the application of antibiotics. In addition, there was no dehiscence or re-infection of the wound after surgical intervention.

## DISCUSSION

The observations on neem oil as being very effective in wound healing as complete healing with scar formation was achieved within a week agrees with reports that neem oil has the ability to heal wounds without causing any infection (Kareru et al., 2010; Biswas et al., 2002) and also has the ability to help the body rapidly create collagen fibres to close wounds (Bhardwaj and Rajput, 2010; Conrick, 2006) while boosting the body immunity (Upadhyay et al., 1993) by enhancing antibody production and cell-mediated immune response. The enhanced healing of the wound in this case despite being a septic/infected wound, which ideally will require both topical and/or systemic antibiotic therapy and a longer duration to heal (Sanni et al., 2003) can be attributed to the reported medicinal and biological properties of neem oil (Bhardwaj and Rajput, 2010; Kareru et al., 2010; Upadhyay et al., 1993; Biswas et al., 2002; Conrick, 2006). Secondly, the use of a silk suture material and an interrupted suture pattern can predisposes wound to tissue reaction and infection (Sanni et al., 2003; Hassan and Egege, 2004). However, despite these reasons there was still an accelerated healing process with no stitch abscess or re-infection wound observed. This could be attributed to the general antiseptic and antimicrobial properties of neem oil (Kareru et al., 2010; Biswas et al., 2002).

Prior to the surgical intervention and the application of the neem oil, the feeding habit of the ram was greatly affected as the animal was reported to be isolating itself, not feeding well and gradually losing weight. This agrees with reports abscesses have negative effects on animal performance due to depression in daily weight gain of as much as 11% and a decrease in feed efficiency of up to 9.7% (Brink et al., 1990). The resulted decrease in feed consumption by the ram in this case could therefore be a setback to the fattening programme to which the ram was put on due to decreased feed consumption and conversion and the resultant weight loss. The neem oil treatment did not produce any observable untoward reaction from the ram thus confirming reports that neem and its products are non-toxic to animals and people when used at normal dosage (Mantle et al., 2001). The ram showed marked improvement in feeding a day (about 24 h) after the surgical intervention and the treatment. The animal also moved around with less difficulty. The sutures were removed on the 5th day and by the 7th day, complete healing with scar formation was observed (Figure 5). Complete gait and feeding habit were fully returned.

## Conclusion

The verification of the efficacy of neem oil requires controlled and structured experimental studies despite the many recorded scientific facts of the efficacy of neem compounds. Also the changing global scenario toward the use of cheap, available and non-toxic plant products having traditional medicinal uses and the development of modern drugs for the control of various diseases from neem and other plants should be emphasized. In fact the United Nations have declared neem as the 'tree of the 21st century'.

## ACKNOWLEDGEMENTS

The author's wishes to appreciate Enam A. Khalil and his colleagues whose work on the evaluation of the wound healing effect of some Jordanian traditional medicinal plants formulated in pluronic F127 using mice provided us with some of the needed literature and the framework upon which to tailor our write-up. We also wishes to thank Elisha Tiyaknet for the technical assistance rendered.

## REFERENCES

- Abu-Irmaileh B, Afifi FU (2000). Treatment with medicinal plants in Jordan. *Dirasat*, 27: 53-74.
- Bairy KL (2002). Wound Healing Potential of Plant Products. *J. Nat. Rem.*, 2: 11-20.
- Bhardwaj RL, Rajput R (2010). Wound healing properties of neem oil (*Azadirachta indica* Juss) and turmeric powder (*Curcuma longa*). *Ind. J. Vet. Surg.*, 31(1): 59-61.
- Biswas K, Chatlopadhyay J, Bamejee RK, Bandyopadhyay U (2002). Biological activities and medicinal properties of Neem (*Azadirachta indica*). *Curr. Sci.*, 82: 1336-1345.
- Brink DR, Lowry SR, Stock RA, Parrott JC (1990). Severity of liver abscess an efficiency of feedlot cattle. *J. Anim. Sci.*, 68: 1201-1207.
- Choi SW, Son BW, Son YS, Park YI, Lee SK, Chung MH (2001). The wound healing effect of a glycoprotein fraction isolated from *Aloe vera*. *Br. J. Dermat.*, 145: 535-545.
- Conrick J (2006). The miraculous healing herb, Neem Direct, Holdings Inc. [www.neemdirect.com](http://www.neemdirect.com).
- Cornborough J (2004). *Neem: An ancient cure for a modern world*. Positive Health Publications Ltd, 1994-2004.
- Hassan AZ, Egege SC (2004). *Veterinary Clinics for Animal Health and Husbandry*. Ahmadu Bello University Press Limited, pp. 143-193.
- Kareru PG, Keriko JM, Kenji GM, Thiong'o GT, Gachanja AN, Mukiira HN (2010). Antimicrobial activities of skincare preparations from plant extracts. *Afr. J. Tradit. Complement. Altern. Med.*, 7(3): 214-218.
- Khalil EA, Afifi FU, Al-Hussain M (2007). Evaluation of the wound effect of some Jordanian traditional medicinal plants formulated in pluronic F127 using mice (*Mus musculus*). *J. Ethnopharmacol.*, 109: 104-112.
- Levy D (2004). *Infectious diseases*. Greater Baltimore, Adam Health Illustrated Encyclopedia.
- Mantle D, Gok MA, Lennard TWJ (2001). Adverse and beneficial effect of plant extracts on skin and skin disorders: Adverse drug reaction. *Toxicol. Rev.*, 20(2): 89-103.
- Nwude N (1986). Veterinary aspects of medicinal plants research in Nigeria. In: state of medicinal plant Res. Nig. Ed. Sofowora, A: 197
- Ojo SA (1994). A survey of pathological conditions in slaughtered goats in Zaria slaughter houses. *Proceedings of the Third Biennial Conference of African Small Ruminant's Research Network*, pp. 5-9.
- Opasina BA, David-West KB (1987). Position paper on sheep and goat production in Nigeria. *Proceedings of a seminar held in Yamoussoukro, Cote D'ivoire*, pp. 21-25.
- Sanni BD, Elisha IL, Hassan AZ, Adeyanju JB (2003). Complications from students' small animal surgical laboratories. *Nig. Vet. J.*, 24: 57-62.
- Sargison N (2003). Caseous lymphadenitis. *NADIS Sheep Dis. Bulletin*, pp. 1-3.
- Schmutterer H (1990). Properties and potential of natural pesticides from the Neem tree, *Azadirachta indica*. *Ann. Rev. Entomol.*, 35: 271-297.
- Schmutterer H (Ed) (1995). *The Neem tree: Source of unique natural products for integrated pest management, medicine, industry and other purposes*. VCH, Weinheim, Germany, pp. 1-696.
- Stix G (1992). Village Pharmacy: The Neem tree yields products from pesticides to soap. *Sci. Am.*, 266: 132.
- Upadhyay SN, Dhewan S, Gary S, Wali N, Tucker L, Anderson DJ (1993). Immuno-modulatory properties of Neem (*Azadirachta indica*): *Proceedings of the World Neem Conference, Bangalore, India*.