

Case Report

A case of recalcitrant oral lichen planus

Md. Hadiuzzaman¹, M. Hasibur Rahman¹ and Nazma Parvin Ansari²

¹Department of Dermatology and VD, Community Based Medical College, Bangladesh.

²Department of Pathology, Community Based Medical College, Bangladesh.

Accepted 12 December, 2019

Oral lichen planus (OLP) is a chronic inflammatory dermatosis of unknown etiology that often involves the mucous membranes. Most of the non-ulcerative type of OLP improved with topical and systemic medications and recurrence is common. Here, a 52-year-old male presented with a 10-year history of persistent, gray-white oral mucosal discoloration and discomfort that had not improved after empiric treatment with topical triamcinolone acetonide. Histopathologic examination confirmed the diagnosis of OLP. Treatments were given with intralesional triamcinolone acetonide, oral paste and even systemic steroids, but little improvement was noted. Finally, patient was cured by surgical excision. There was no relapse after 2 years follow up.

Key words: Oral lichen planus (OLP), steroids, surgical excision, relapse.

INTRODUCTION

Oral lichen planus (OLP) is a chronic inflammatory condition characterized by mucosal lesions of varying appearance and severity (Setterfield et al., 2000). It affects 1 to 2% of the general adult population (Sousa and Rosa, 2008); the reported prevalence rates in Indian population are 2.6% (Murti et al., 1986). OLP has been reported to be more frequent in females (Ingafou et al., 2006; Pakfetrat et al., 2009; Eisen, 2002; Chainani-Wu et al., 2001) and occurs more predominantly in Asians (Alam and Hamburger, 2001; Laeijendecker et al., 2005).

The clinical presentation of OLP ranges from mild painless white keratotic lesions to painful erosions and ulcerations (Scully and Carrozzo, 2008). OLP is classified into reticular, erosive, atrophic, and bullous types (Greenberg and Glick, 2003). The reticular form is the most common type and is presented as papules and plaques with interlacing white keratotic lines (Wickham striae) with an erythematous border. The striae are typically located bilaterally on the buccal mucosa, mucobuccal fold, gingiva, and less commonly, the tongue, palate, and lips (Edwards and Kelsch, 2002). The reticular type has been reported to occur significantly more often in

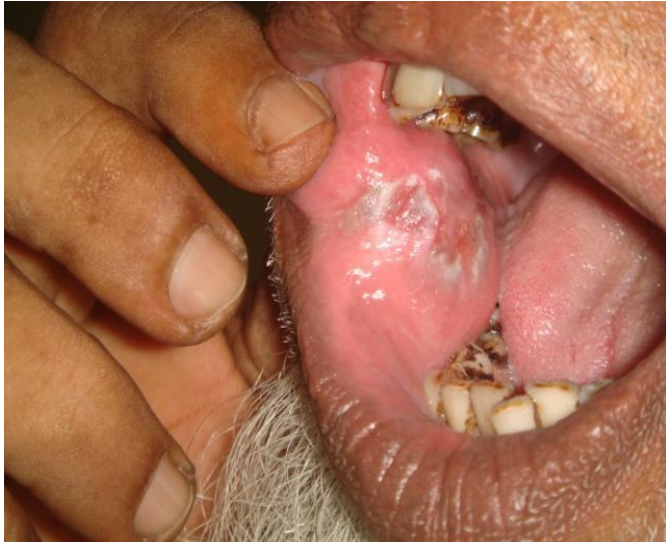men as compared to women (Chainani-Wu et al., 2001) and is usually asymptomatic. Erosive, atrophic, or bullous type lesions cause burning sensation and pain.

OLP affects primarily middle-aged adults and is rare in children (Laeijendecker et al., 2003; Patel et al., 2005). There are few reports of childhood OLP in children in the literature (Pakfetrat et al., 2009; Alam and Hamburger, 2001). Alam and Hamburger (2001) describe a rare case involving a 7-year-old child affected with OLP who was successfully treated with topical application of corticosteroid cream and plaque control regime.

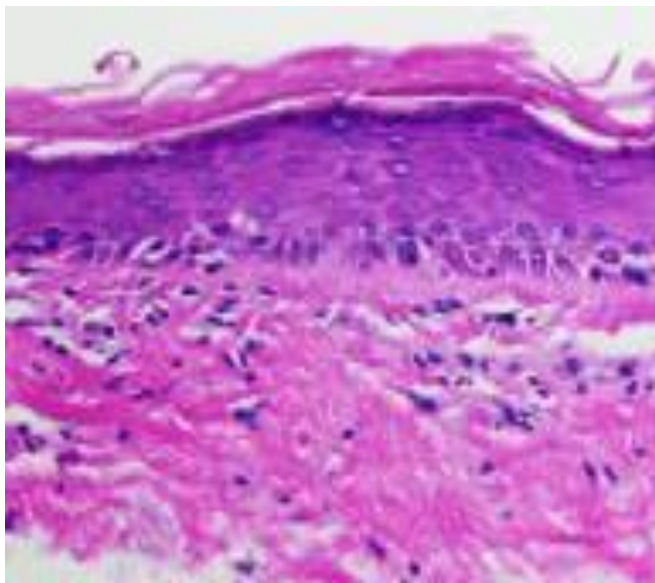
CASE REPORT

A married male of 52-year-old came to the Community Based Medical College Hospital, Mymensingh, in January 2008, with a 10-year history of persistent gray-white oral mucosal ulceration that caused discomfort and fear of cancer. He had been previously treated with a 5-week course of triamcinolone acetonide orabase cream, intralesional triamcinolone and systemic prednisolone, but the improvement was not satisfactory. He also visited many doctors for the remedy and took oral antibiotics and antifungal. Although, some improvement were noted from systemic and local steroids, but it reappears. There were no associated skin and nail changes found. He has no history of exposure other than his wife. The patient had no other medical or dental problems and was otherwise Healthy without any systemic complaints. There was no family

*Corresponding author. E-mail: dr_cosmoderma@yahoo.com.



A. **Figure 1.** Lesion on right oral buccal mucosa.



B. **Figure 2.** Histological features of the lesion.

history of any skin or dental disorders. Although, the patient had lived in village; he did not experience blistering and had no history of skin cancer. The patient is non-smoker and does not have the habit of betel leaf chewing.

A persistent gray-white oral mucosal ulceration was present on the inner surface of the right cheek. The tongue, gingivae, other mucosal areas and nails appeared normal. Total body cutaneous examination including hairs reveals no abnormality. There was no lymphadenopathy.

A complete blood count, comprehensive metabolic panel, hepatic function panel, and thyroid function panel were normal. Hepatitis B virus, hepatitis C virus, antinuclear antibody, and rheumatoid factor were negative. Mucosal biopsy for histopathology reveals positive finding for OLP (Figures 1 and 2).

Topical steroid, systemic steroid, hydroxychloroquine and even intralesional steroid were given to the patient, but the result was not even satisfactory. Finally, we decided to excise the lesion and follow the case for future outcome. After 2 years follow up, we did not find any recurrence.

DISCUSSION

OLP may involve any part of the mouth. Buccal mucosa is involved in 90% of the cases and the gingival in more than 50%. 15% of OLP will also have skin lesions. Exact cause is not yet known. A growing body of evidence supports an immunopathologic mechanism that involves dysregulation of cellular immunity. Postulated initiating events that may trigger OLP include infection, trauma, systemic medication, and contact sensitivity; however,

evidence proving a causal relationship is lacking (Lodi et al., 2005; Ichimura et al., 2006; Carrozzo et al., 2004; Yamamoto and Osaki, 1995; Mazzarella et al., 2006). OLP has a prevalence rate reported between 0.1 and 4%. It most commonly affects patients of ages 30 to 60 years and is found more frequently in women. While OLP is frequently observed in patients with cutaneous lichen planus, it may be the only finding in approximately 25%. The reticulate clinical presentation displaying the characteristic Wickham's striae is the most common; however, numerous clinical forms may be observed in isolation or in combination (e.g. atrophic, erosive, bullous, papular, pigmented, and plaque-like). Diagnosis may be made using clinical features alone or may require clinicopathologic correlation for atypical presentations or to rule out malignant conditions (Eisen et al., 2005; Silverman et al., 1985; Xue et al., 2005; Ingafou et al., 2006). Differential diagnosis includes oral lichenoid reactions and other white or gray-colored oral lesions (Al-Hashimi et al., 2007). Oral lichenoid contact lesions most commonly result from dental amalgams used in restorative procedures (Laeijendecker et al., 2004). Oral lichenoid drug reactions can be caused by hypoglycemic agents, non-steroidal anti-inflammatory agents and less frequently penicillamine or gold salts. Actinic cheilitis typically occurs in older patients and is accompanied by additional manifestations of dermatoheliosis (Al-Hashimi et al., 2007; Juneja et al., 2006). Histopathology features include basal keratinocyte apoptosis and a lichenoid interface lymphocytic reaction. This pattern also can appear in other oral lichenoid reactions, erythema multiforme, discoid lupus erythematosus and graft-versus-host-disease (Al-Hashimi et al., 2007; Laeijendecker et al., 2004; Thornhill et al., 2006). Annual monitoring via clinical examination and/or histopathologic analysis is recommended for potential malignant transformation, which can occur with chronic inflammation (Juneja et al., 2006; Lodi et al., 2005; van der Meij et al., 2007; Laeijendecker et al., 2005; Mignogna et al., 2004; Bascones et al., 2005). Development of oral squamous-cell carcinoma in OLP has been reported at a rate of 0.2

to 0.5% and occur more often in the erosive or bullous forms. Additionally, patients should avoid possible mutagens such as tobacco and alcohol (Montebugnoli et al., 2006; Maraki et al., 2006; Mattila et al., 2007). Routine screening for hepatitis C virus (HCV) is controversial. OLP and HCV have been frequently associated in anecdotal reports. However, a causative role for HCV has not been demonstrated in prospective studies. Testing for HCV in a patient with OLP would be considered reasonable (Buajeeb et al., 2007; Lodi et al., 2004). Management of non-ulcerative OLP typically involves medical modalities, which include topical or intralesional glucocorticoids, topical calcineurin inhibitors, topical or oral retinoids, hydroxychloroquine, and phototherapy (Al-Hashimi et al., 2007; Laeijendecker et al., 2005).

REFERENCES

- Setterfield JF, Black MM, Challacombe SJ (2000). The management of oral lichen planus. *Clin. Exp. Dermatol.* 25:176-82.
- Sousa FA, Rosa LE (2008). Oral lichen planus: Clinical and histopathological considerations. *Braz. J. Otorhinolaryngol.* 74:284-92.
- Murti PR, Daftary DK, Bhonsle RB, Gupta PC, Mehta FS, Pindborg JJ (1986). Malignant potential of oral lichen planus: Observations in 722 patients from India. *J. Oral Pathol.* 15:71-7.
- Ingafou M, Leao JC, Porter SR, Scully C (2006). Oral lichen planus: A retrospective study of 690 British patients. *Oral Dis.* 12:463-8.
- Pakfetrat A, Javadzadeh-Bolouri A, Basir-Shabestari S, Falaki F (2009). Oral lichen planus: A retrospective study of 420 Iranian patients. *Med. Oral Patol. Oral Cir. Bucal* 14:E315-8.
- Eisen D (2002). The clinical features, malignant potential, and systemic associations of oral lichen planus: A study of 723 patients. *J. Am. Acad. Dermatol.* 46:207-14.
- Chainani-Wu N, Silverman S Jr, Lozada-Nur F, Mayer P, Watson JJ (2001). Oral lichen planus: Patient profile, disease progression and treatment responses. *J. Am. Dent. Assoc.* 132:901-909.
- Alam F, Hamburger J (2001). Oral mucosal lichen planus in children. *Int. J. Paediatr. Dent.* 11:209-14.
- Laeijendecker R, Van Joost T, Tank B, Oranje AP, Neumann HA (2005). Oral lichen planus in childhood. *Pediatr. Dermatol.* 22:299-304.
- Scully C, Carrozzo M (2008). Oral mucosal disease: Lichen planus. *Br. J. Oral Maxillofac. Surg.* 46:15-21.
- Greenberg MS, Glick M (2003). *Burket's Oral Medicine*, 10th ed., Hamilton: BC Decker Inc. pp. 89-95.
- Edwards PC, Kelsch R (2002). Oral lichen planus: Clinical presentation and management. *J. Can. Dent. Assoc.* 68:494-9.
- Patel S, Yeoman CM, Murphy R (2005). Oral lichen planus in childhood: A report of three cases. *Int. J. Paediatr. Dent.* 15:118-22.
- Lodi G, Scully C, Carrozzo M, Griffiths M, Sugerman PB, Thongprasom K (2005). Current controversies in oral lichen planus; Report of an international consensus meeting-Part 1. Viral infections and aetiopathogenesis. *Oral Surg. Oral Med. Oral Pathol. Radiol. Endod.* 100:40-51.
- Ichimura M, Hiratsuka K, Ogura N, Utsunomiya T, Sakamaki H (2006). Expression profile of chemokines and chemokine receptors in epithelial cell layers of oral lichen planus. *J. Oral Pathol. Med.* 35:167-174.
- Carrozzo M, Uboldi de Capei M, Dametto E, Fasano ME, Arduino P, Broccoletti R, Vezza D, Rendine S, Curtoni ES, Gandolfo S (2004). Tumor necrosis factor-alpha and interferon-gamma polymorphisms contribute to susceptibility to oral lichen planus. *J. Invest. Dermatol.* 122(1):87-94.
- Yamamoto T, Osaki T (1995). Characteristic cytokines generated by keratinocytes and mononuclear infiltrates in oral lichen planus. *J. Invest. Dermatol.* 104:784-788.
- Mazzarella N, Femiano F, Gombos F, De Rosa A, Giuliano M (2006). Matrix metalloproteinase gene expression in oral lichen planus: Erosive vs. reticular forms. *J. Eur. Acad. Dermatol. Venereol.* 20:953-957.
- Eisen D, Carrozzo M, Bagan Sebastian JV, Thongprasom K (2005). Oral lichen planus: Clinical features and management. *Oral Dis.* 11:338-349.
- Silverman S Jr, Gorsky M, Lozada-Nur F (1985). A prospective follow-up study of 570 patients with oral lichen planus: Persistence, remission, and malignant association. *Oral Surg. Oral Med. Oral Pathol. Oral Radiol. Endod.* 60:30-34.
- Xue JL, Fan MW, Wang SZ, Chen XM, Li Y, Wang L (2005). A clinical study of 674 patients with oral lichen planus in China. *J. Oral Pathol. Med.* 34:467-472.
- Ingafou M, Leao JC, Porter SR, Scully C (2006). Oral lichen planus: A retrospective study of 690 British patients. *Oral Dis.* 12:463-468.
- Al-Hashimi I, Schifter M, Lockhart PB, Wray D, Brennan M, Migliorati CA, Axéll T, Bruce AJ, Carpenter W, Eisenberg E, Epstein JB, Holmstrup P, Jontell M, Lozada-Nur F, Nair R, Silverman B, Thongprasom K, Thornhill M, Warnakulasuriya S, van der Waal I (2007). Oral lichen planus and oral lichenoid lesions: diagnostic and therapeutic considerations. *Oral Surg. Oral Med. Oral Pathol. Oral Radiol. Endodontol.* 103:S25.e1-12.
- Laeijendecker R, Dekker SK, Burger PM, Mulder PG, Van Joost T, Neumann MH (2004). Oral lichen planus and allergy to dental amalgam restorations. *Arch. Dermatol.* 140:1434-1438.
- Thornhill MH, Pemberton MN, Simmons RK, Theaker ED (2006). The role of histopathological characteristics in distinguishing amalgam-associated oral lichenoid reactions and oral lichen planus. *J. Oral Pathol. Med.* 35:233-240.
- Juneja M, Mahajan S, Rao NN, George T, Boaz K (2006). Histochemical analysis of pathological alterations in oral lichen planus and oral lichenoid lesions. *J. Oral Sci.* 4:185-193.
- Lodi G, Scully C, Carrozzo M, Griffiths M, Sugerman PB, Thongprasom K (2005). Current controversies in oral lichen planus: Report of an international consensus meeting-Part 2. Clinical management and malignant transformation. *Oral Surg. Oral Med. Oral Pathol. Oral Radiol. Endodontol.* 100:164-178.
- Van der Meij EH, Mast H, van der Waal I (2007). The possible premalignant character of oral lichen planus and oral lichenoid lesions: A prospective five-year follow-up study of 192 patients. *Oral Oncol.* 43(8):742-748.
- Laeijendecker R, van Joost T, Kuizinga MC, Tank B, Neumann HA (2005). Premalignant nature of oral lichen planus. *Acta Derm. Venereol.* 85:516-520.
- Mignogna MD, Fedele S, Lo Russo L, Adamo D, Satriano RA (2004). Immune activation and chronic inflammation as the cause of malignancy in oral lichen planus: Is there any evidence? *Oral Oncol.* 40:120-130.
- Bascones C, Bascones C, Gonzalez-Moles MA, Esparza G, Bravo M, Acevedo A, Gil-Montoya JA, Bascones A (2005). Apoptosis and cell cycle arrest in oral lichen planus: Hypothesis on their possible influence on its malignant transformation. *Arch. Oral. Biol.* 50:873-881.
- Montebugnoli L, Farnedi A, Marchetti C, Magrini E, Pession A, Foschini MP (2006). High proliferative activity and chromosomal instability in oral lichen planus. *Int. J. Oral Maxillofac. Surg.* 35:1140-1144.
- Maraki D, Yalcinkaya S, Pomjanski N, Megahed M, Boecking A, Becker J. (2006). Cytologic and DNA-cytometric examination of oral lesions in lichen planus. *J. Oral. Pathol. Med.* 35:227-232.
- Mattila R, Alanen K, Syrjänen S (2007). Immunohistochemical study on topoisomerase II alpha, Ki-67 and cytokeratin-19 in oral lichen planus lesions. *Arch. Derm. Res.* 298:381-388.
- Buajeeb W, Kraivaphan P, Amornchat C (2007). Frequency of micronucleated exfoliated cells in oral lichen planus. *Mutat. Res.* 627:191-196.
- Lodi G, Giuliani M, Majorana A, Sardella A, Bez. C, Demarosi F, Carrassi A (2004). Lichen planus and hepatitis C virus: A multicentre study of patients with oral lesions and a systematic review. *Br. J. Dermatol.* 151:1172-1181.
- Laeijendecker R, Van Joost T, Tank B, Neumann HM (2005). Oral lichen planus and hepatitis C virus infection. *Arch. Dermatol.* 141:906-907.