

Full Length Research Paper

Phytochemical screening and histopathological effects of single acute dose administration of *ARTEMISIA ANNUA* L. on testes and ovaries of Wistar rats

P. O. Ajah^{1*} and M. U. Eteng²

¹Institute of Oceanography, University of Calabar, Calabar, Cross Rivers, Nigeria.

²Department of Biochemistry, University of Calabar, Calabar, Cross Rivers, Nigeria.

Accepted 08 April, 2018

ARTEMISIA ANNUA L. is a medicinal plant whose derivatives are used in the treatment of malaria. Phytochemical screening and histopathological effects of single acute intraperitoneal dose of the alcoholic extract of *A. ANNUA*, were investigated in Wistar rats in this study. Thirty five adult albino Wistar rats (109 - 307 g) of both sexes used for the study were randomly assigned on the basis of weight and litter origin into seven study groups of five rats per group. The control (group A) was administered placebo (2 ml of pure olive oil) while test groups B to G received single graded doses of 0.18, 0.35, 0.52, 0.70, 0.86 and 1.05 g/kg body weight of extract in olive oil vehicle, respectively. Twenty four hours after the single acute dose administration, animals were sacrificed and testes and ovary tissues obtained for histological evaluation using standard methods. Results of phytochemistry of the alcoholic extract assessed by standard methods identified the presence of alkaloids, glycosides (presence of these in *A. ANNUA* is questionable), flavonoids, reducing compounds and polyphenols present in different concentrations. Histopathological changes showed adverse lesions on the ovary ranging from atretic-degenerating corpus luteum, with loss of connective substance, arrest of ovarian follicle maturation to complete absence of ovarian follicle. No adverse histopathological changes were observed in the testes. The result suggests arrest of ovulation and a predisposition to infertility (add in the female animals). The possible roles of phytoestrogenic constituents in the favonoid fraction of the phytochemicals are discussed.

Key words: *Artemisia annua*, phytochemistry, histopathology, testes and ovaries.

INTRODUCTION

Artemisia annua L. (add,) also known as sweet wormwood, annual wormwood or sweet Annie (add,) is an aromatic annual herb which is the source of artemisinin and essential oils (Simon et al., 1990). The secondary plant product artemisinin known in Chinese folk medicine as qinghasu is an antimalarial with reduced side effects compared to quinine, chloroquine or other antimalarials (Klayman, 1985). The quinolines and sulphadozine-pyrimethamine have reduced clinical effectiveness in Africa owing to biocidal resistance to them by malarial parasites. Artemisinin is effective in cases where there is biocidal resistance.

However, monotherapy with artemisinin results in high recrudescence rates and fears of possible biocidal resistance developing have been expressed. The World Health Organisation therefore recommended the use of artemisinin drugs in combination with other effective antimalarials. Such artemisinin based combination therapies are increasingly in use in Africa (WHO, 1981).

Jellin et al. (2000) has reported that the herb is unsafe for use during pregnancy due to its uterine and menstrual stimulating effects. And although there is no sufficient or reliable information in this regards, it should not also be used during lactation. In the light of the above, the present study undertook the phytochemical screening and evaluation of the possible histopathological effects of the herb on the testes and ovary, the primary reproductive organs of albino Wistar rats and hence the

*Corresponding author. E-mail: ajapaulo@yahoo.com.

fertility status.

MATERIALS AND METHODS

Plant material

Fresh leafy biomass of *A. annua* L. was obtained courtesy of Prof. E. A. Brisibe of the Department of Genetics and Biotechnology, University of Calabar, Calabar, Nigeria, who has worked extensively on the plant and help to authenticate it for this study. The sample was air dried and the leaves were harvested and ground into coarse powder to give a pulverised sample of 50 g. This was extracted using 200 ml of 95% ethanol in a soxhlet equipment. The extract obtained was concentrated in vacuo at 4°C to give a 10.3 g mass representing 29.43% yield. The extract was divided into two portions, one of which was immediately subjected to phytochemical screening based on Sofowora (1982) to test for the presence of different phytochemical constituents such as alkaloids, glycosides, tannins, saponins, (Sofowora, 1982), flavonoids, polyphenols, reducing compounds (Harbone, 1973), phlobatannins, anthraquinones, and hydroxymethyl (Trease and Evans, 1978). The second portion of the extract was suspended in pure olive oil as vehicle and from these stock appropriate graded doses was obtained for administration.

The single intraperitoneal administration was done using a sterile syringe and needle between 08.00 and 09.00 a.m. daily.

Animals and treatments

Permission for use of animal was obtained from the College of Medical Sciences animal ethics committee. Handling and treatment of animal's protocol adhered strictly to the laid down rules in the ethical guide. Thirty two adult albino Wistar rats consisting of 19 females and 13 males weighing between 109 and 307 g were obtained from the animal facility of Department of Zoology and Environmental Sciences, Faculty of Science, University of Calabar, Calabar, Nigeria and used for the study. The animals were transferred to the Animal House facility of the Animal Science Department, Faculty of Agriculture, University of Calabar, Calabar, Nigeria and following acclimatisation for one week, they were randomly assigned into seven study groups of five rats per group with each group consisting of three females and two males. They were housed in plastic cages with wire screen top and kept under adequate ventilation and the environmental temperature ($28 \pm 2^\circ\text{C}$) and relative humidity ($50 \pm 5\%$) with a 12 h light/dark cycle. The animals were maintained on a commercial rat chow with tap water and food provided *ad libitum* throughout the experimental period.

Animals in group A (control) were treated with a placebo of pure olive oil as a vehicle while those in groups B to G were administered graded doses of the *A. annua* ethanolic extracts of 0.18, 0.35, 0.52, 0.70, 0.86 and 1.05 g/kg body weight, respectively. The single acute dose intraperitoneal administration was done using syringe and needle.

Collection of tissues and histological analysis

Twenty four hours after the single acute dose administration, male and female animals were collected from each group, anaesthetised in chloroform vapour and dissected. The ovaries and testes were collected and immediately fixed in Bouins fluid for 6 h and transferred to 70% alcohol for histological processing according to Drunny and Wallington (1990). Briefly, following fixation of the right side testes and ovaries from both control and test animals, tissue sections were processed by dehydration in 95% and absolute alcohol, cleared in xylene and embedded in pure clean molten

Table 1. Phytochemical profile of *Artemisia annua* L. extract.

Chemical constituent	ARTEMISIA ANNUA
Alkaloids	+
Glycosides (free anthraquinones)	(This is questionable)
Saponins	-
Tannins	-
Flavonoids	++
Reducing compounds	+
Polyphenols	+++
Phlobatannins	(This is questionable)
Anthraquinones	-

Key: +++ = Much excess, ++ = excess, + = slight presence, - = not present.

paraffin wax from which blocks of tissues were made for sectioning. Ribbon slices of about 5.0µm in thickness were made with the aid of a microtome (delete machine) and the sections picked with slides which were dried in oven. The slices were then stained with Haematoxylin and Eosin, and then mounted using DPX onto a light microscope (delete magnification x 40 for testes and x 10 for ovary) for histopathological and morphological changes. The changes observed were recorded and photomicrographs of the most prominent pathological lesions taken.

RESULTS

Phytochemical screening

The phytochemical profile of *A. annua* is summarized in Table 1. The results identified (delete with exception of saponins, tannins, phlobatannins or anthraquinones) the presence of alkaloids, glycosides (presence of these compounds is questionable), flavonoids, reducing compounds and polyphenols with flavonoids and polyphenols present in excess and much excess (add levels), respectively.

Histological studies

Graded concentrations (add of *A. annua* ethanolic extract namely:) 0.18, 0.35, 0.52, 0.70, 0.86 and 1.05g per kg body weight were administered to the rats in a single acute dose and histological changes evaluated in ovarian and testicular tissues obtained from treated and control rats. The histological changes are summarised in Figures 1 to 3.

Plate 1a. The control Group A shows well layered cells of the seminiferous tubules which vary greatly in size and shape of cells. The nuclei lack defined laminal margin and inconspicuous cell boundary. The photo-micrograph shows the effect of pure olive oil on the histology of gonad section of Group A (control).

In Plate 1a, the control testes, the interstitial cells are prominent, well distinct and vascularized with interstitial

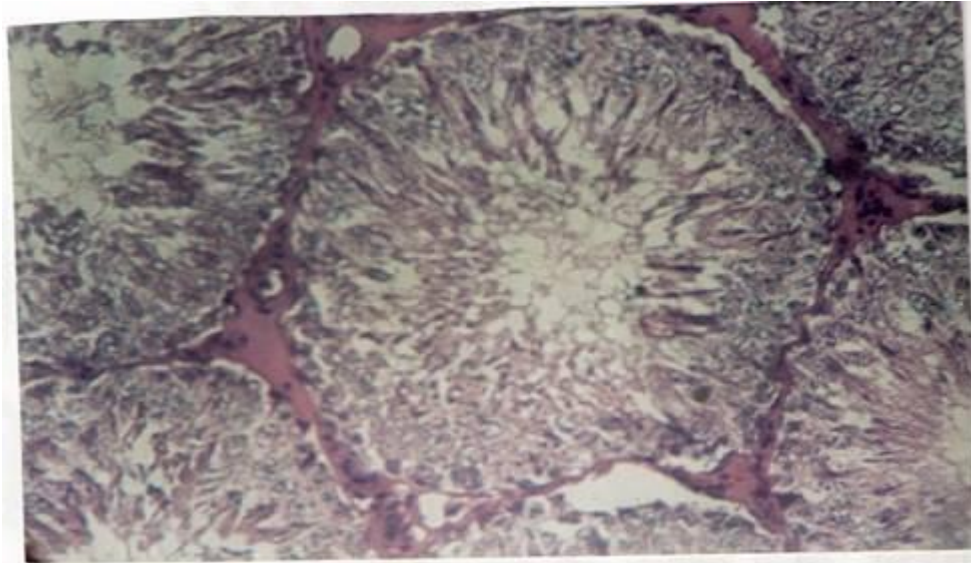


Plate 1a. Control male albino rat (X 10).

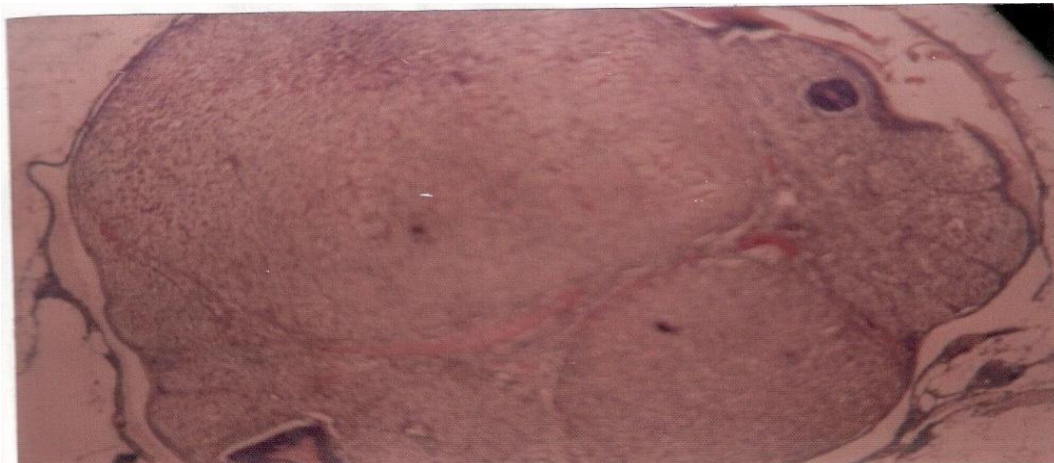

Plate 1b. Control female albino rat (X 10).

spaces adequately filled up with connective tissue. The seminiferous tubules vary greatly in size and shape of the cells and nuclei (Plate 1a).

Histological effect of ethanolic extracts of *A. ANNUA* on gonadal tissues (testis of albino Wistar rats)

Plate 2a treated with *A. annua* at dose 0.52 g/kg body weight showed spermatogenic series of cells seen at the various stages of transformation and differentiation with central tubule showing marked spermatogenic transformation of spermatids into spermatozoa. The supporting cells (Sertoli cells) are intact.

Plate 3a (delete photomicrograph) shows that the basal lamina placed spermatogonia are intact and spermatids at various stages of differentiation filled up the central lumen of the tubules (add when the extract is administered at a) dose of 1.05 g/kg body weight. The features all point to an increased activity of spermatogenesis.

Histological effect of ethanolic extracts of *A. ANNUA* on gonadal tissues (ovum of albino Wistar rats)

The control ovary Plate 1b also shows normal architecture with no lesion. In Plate 2c, regressing corpus

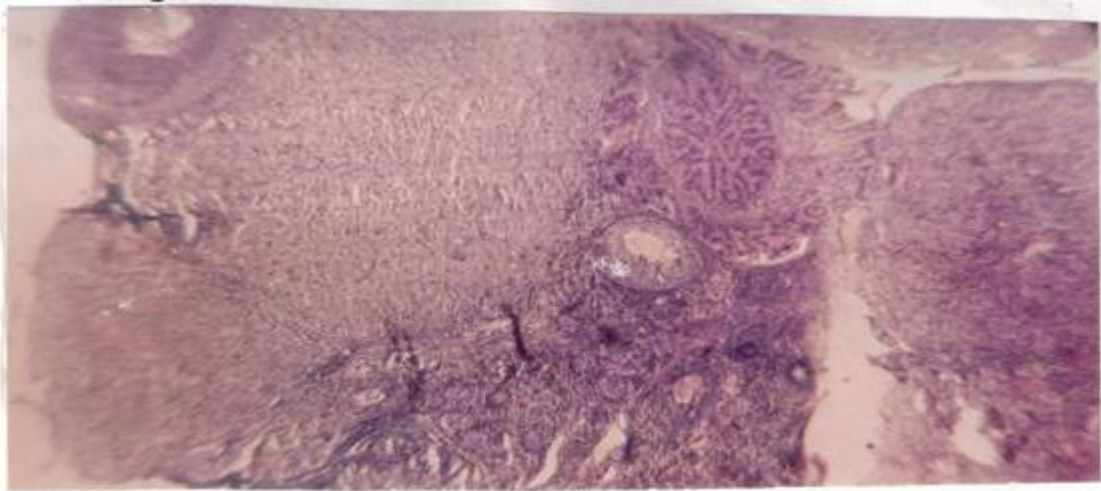
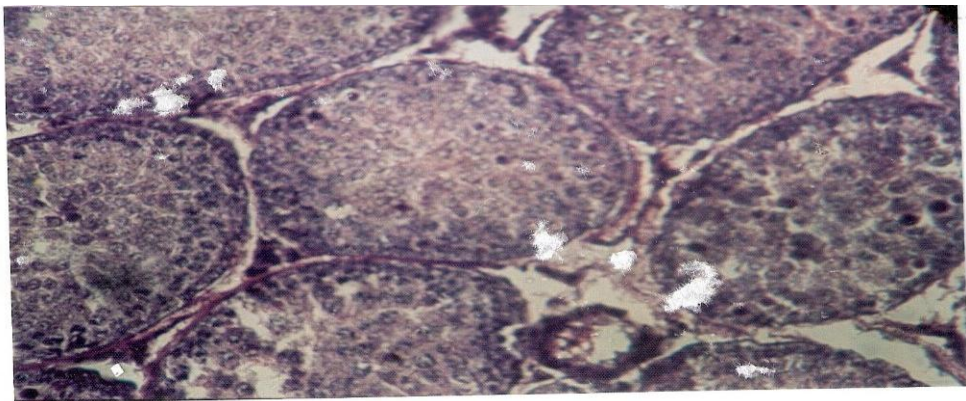
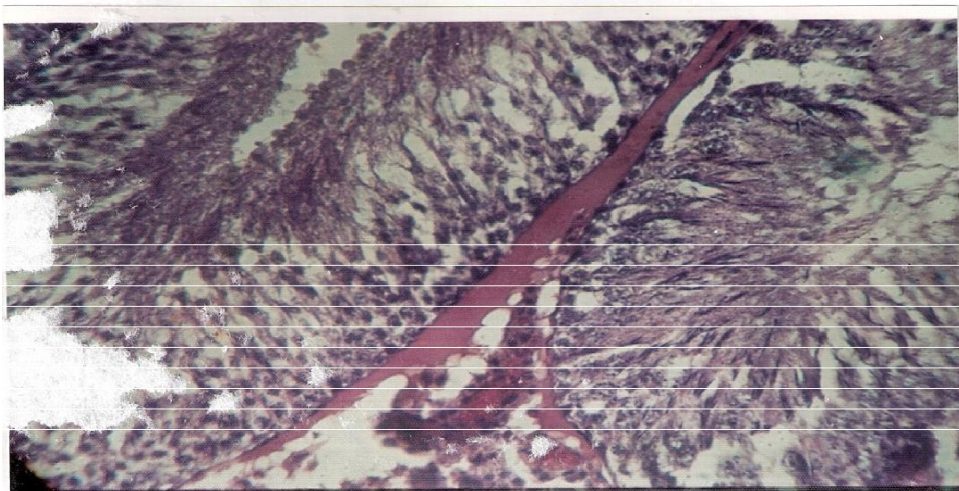


Plate 2a. Treated with *A. annua* at dose 0.52 g/kg body weight showed spermatogenic cells with central tubule showing marked spermiogenic transformation.



2b



2c

Plate 2b. 0.18 g/Kg body weight of extract. In plate 2c, regressing corpus luteum is observed; cells are gradually shrinking with atretic and degenerating follicles even at 0.18 mg/kg body weight of the extract administered.

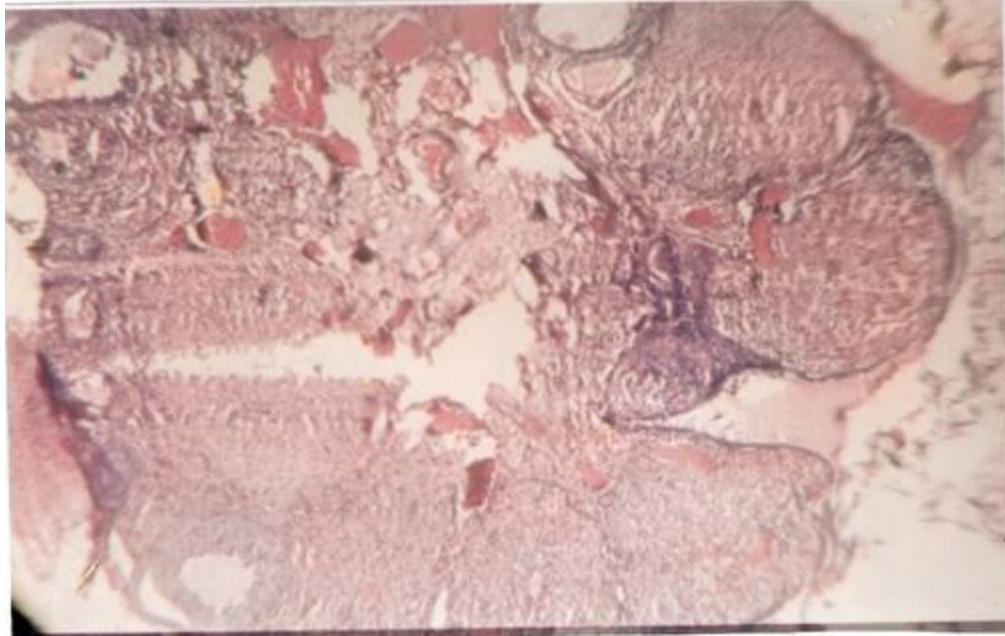


Plate 3a. Photomicrograph shows that the basal lamina placed spermatogonia are intact and spermatids at various stages of differentiation filled up the central lumen of the tubules at dose of 1.05 g/kg body weight. The features all point to an increased activity of spermatogenesis.

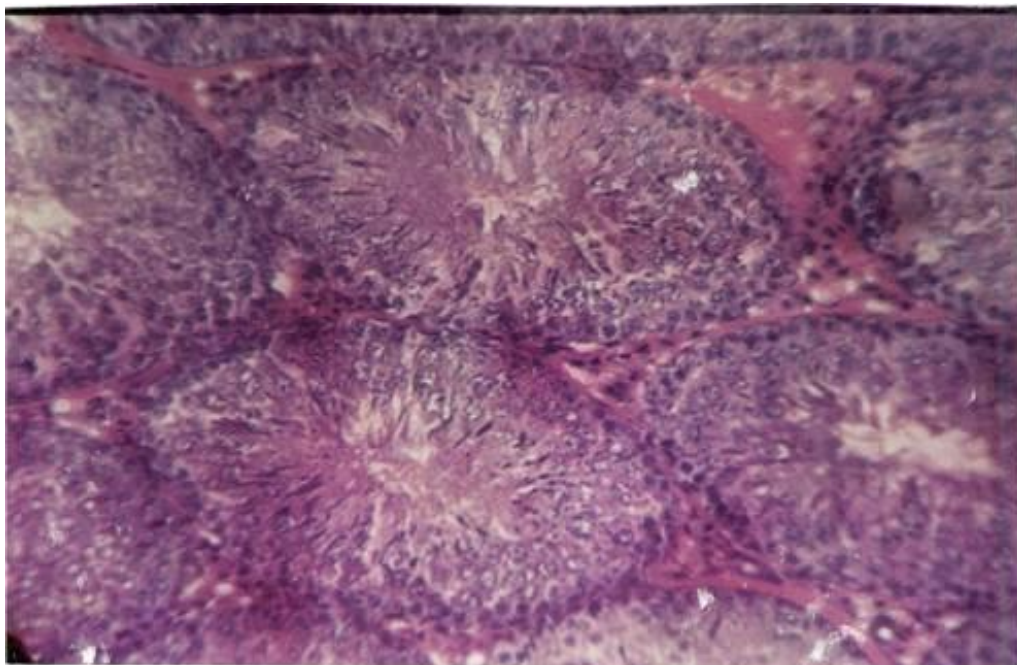


Plate 3b. Dosage of 0.35 g/kg body weight.

luteum is observed; cells are gradually shrinking with atretic and degenerating follicles even at 0.18 mg/kg body weight of the extract administered.

Plate 3b shows degeneration and avulsion of the ovum from most follicles at dose of 0.35 g/kg body weight.

Plate 4 shows further degeneration and avulsion of the ovum from most follicles at dose of 1.05 g/kg body weight.

Plate 5 shows almost total degeneration and avulsion of the ovum from most follicles at dose of 2.5 g/kg

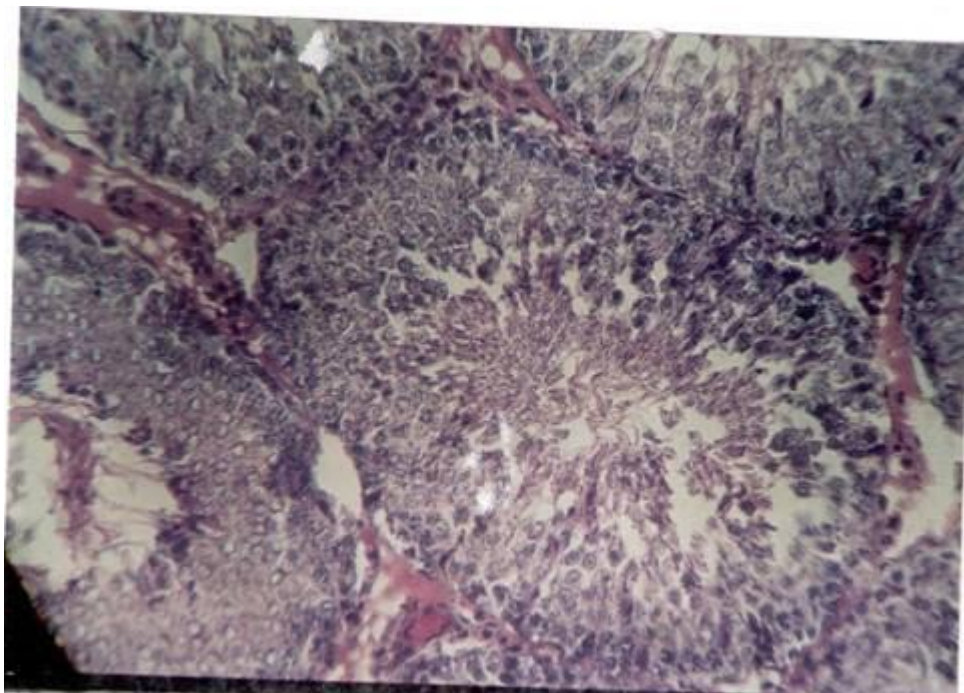


Plate 4. Dosage of 1.05 g/kg body weight.

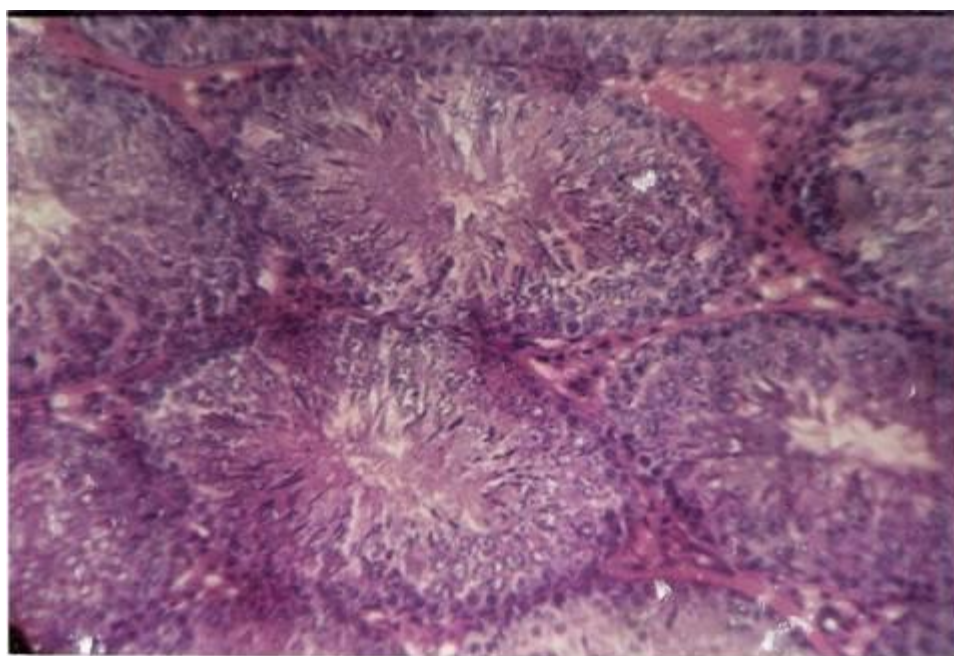


Plate 5. Dosage of 2.5 g/Kg body weight.

g/kg body weight.

Histological effect of ethanolic extracts of *A. annua* on gonadal tissues (testis and ovum) of albino Wistar rats are given in Table 1.

DISCUSSION

Neurological damage following administration of artemisinin in high doses has been reported in animal

studies (Zhu and Woerdenbag, 1995). Although toxicity is a function of dose, the neurological effects have not yet been reported in humans using artemisinin for managing ailments at the therapeutic dose. However, the use of the herb is not safe during pregnancy because of its uterine and menstrual stimulating effects (Jellin et al., 2000). From the results of our study, in the male testis of all treated groups, there was no adverse histopathological change; rather there was marked proliferation of spermatogenic cell lines, transformation from primordial cells to spermatids and further to spermatozoa at a high rate. The seminiferous tubules were moderately enlarged, the central lumen inclusive. There was increased vascularity of interstitial and leydig cells which secrete the male hormone-testosterone. The hyperplasia of leydig cells correlate with increased spermatogenic activity.

On the other hand, the medulla of the ovum in the ovary was highly vascularized but with no ovarian follicle. The corpus luteum appeared degenerative, signifying lack of evidence of proliferation of the ovarian follicle. The follicles in most instances were alterative and gradually merging in the connective substance of the ovary. The stomal cells and the primordial follicles were indistinct. The picture connotes a lack of increased reproductive activity, tending towards degeneration of follicles (corpus luteum) arrest of maturation of ovarian follicle and hence ovulation. A comparison of the histological changes of testis and ovary following a single acute dose of administration shows that there are adverse lesions on the ovary but not on the testes. This may predispose (the female animals) to infertility.

Histology provides conclusive evidence from internal cell characteristics that other techniques fail to highlight. The failure of the gonads to mature as shown by degeneration of follicles may be due to insufficient stimuli for normal gonadal development particularly for the ovary (Msiska, 2002).

The probable reason for the observed histological effects (add in the ovaries) may be due to phytoestrogenic constituents in *A. annua* which may interact with steroids sex hormone metabolism and also the hypothalamic-pituitary-gonadal axis (HPA) of the female reproductive tract. Phytoestrogenic activity is due to such bioactive secondary metabolites as isoflavonoid, sterols, lignans and essential oils (Miksicak, 1993). This may explain a tendency towards atrophy and degeneration. This may not be observed in the testes because of higher estrogenic activity in females compared to males. It is also probable that the ovary may have target receptors for binding with the phytochemical components in the extract which may be lacking in the testes.

In conclusion, intraperitoneal administration of graded single acute doses of *A. annua* L. induced adverse histological changes on the ovaries which may predispose (add the animals) to infertility, but the testes were not affected and retained their normal architecture and normal spermatogenic activity. The phytochemistry revealed the presence amongst others of flavonoids in the extract whose bioactivity may explain the observed effects. The present result suggests that caution should be exercised in the use of *A. annua* and its derivatives in pregnancy.

REFERENCES

- Drunny RAB, Wallington EA (1990). *Histological Techniques* 5th edition London, Oxford University Press, pp 199-220.
- Jellin J, Batz F, Hitchens K (2000). *Natural Medicines Comprehensive Database*. Third Edition. Stock, California: Therapeutic Research Faculty.
- Klayman DL (1985). Quinghasosu (artemisinin), an antimalarial drug from China. *Science*, 228: 1049-1055.
- Miksicak R (1993). Commonly occurring plant flavonoids have estrogenic activity. *Mol. Pharmacol*, 44(1): 37-43.
- Msiska DV (2002). The histology of *Oreochromis* (Nyasalapia) Karongal (Trewaves). *Afr. J. Ecol.* 40(2): 164.
- Simon KV, Charles DJ, Wood KV, Heinsteins P (1990). Germplasm variation in artemisinin content of *Artemisia annua* L. using an alternative from crude plant extract. *J. Nat. Prod.*, 3: 157-160.
- Sofowora EA (1982). *Medicinal Plants and Traditional Medicine in Africa*. New York. John Wiley and Sons.
- Trease GE, Evans EC (1978). *Pharmacognosy* Cassel and Coller. London. Macmillan Publishers.
- WHO (1981). Report of the Fourth Meeting of the Scientific Working Group on the Chemotherapy of Malaria. Beijing, People's Republic of China, October 6-10.
- Zhu YP, Woerdenbag HJ (1995). Traditional Chinese Herbal Medicine. *Pharm. World Sci.*, 17: 103-112.