

Full Length Research Paper

Hepatoprotective effects of vitamin C and micronized vitamin C against paracetamol induced hepatotoxicity in rats: a comparative study

Kamel M. A. Hassanin¹, Khalid S. Hashem¹, Samraa H. Abdel-Kawi²

¹Biochemistry Department, Faculty of Veterinary, Beni-Suef University, Egypt.

²Histology Department, Faculty of Medicine, Beni-Suef University, Egypt.

Accepted 26 June, 2013

This study aimed to investigate the efficacy of micronized vitamin C against paracetamol-induced liver damage and to compare its effect with that of ordinary vitamin C. **METHODS:** 40 male rats were divided into four groups; 10 rats for each: control group; phosphate-buffered physiological saline (0.5 mL orally); paracetamol group (paracetamol 600 mg/kg, orally); paracetamol-vitamin C treated group (paracetamol 600 mg/kg, orally & vitamin C 500 mg/ /kg, orally); paracetamol-micronized vitamin C treated group (paracetamol 600 mg/kg, orally & micronized vitamin C 500 mg/kg, orally). In all groups, potential liver injuries were evaluated by using biochemical, oxidant-antioxidant, histopathological and immunohistochemical parameters. **RESULTS:** Paracetamol administration significantly increased the liver enzymes and decreased total protein level. It also increased hepatic lipid peroxidation "MDA" and the activities of both catalase and SOD while it decreased GSH content and glutathione reductase (GR) activity. It also increased liver DNA fragmentation and expression of caspase-3 in hepatocytes. Histopathological and immunohistochemical investigations proved the hepatic degeneration and centrilobular necrosis in rats exposed to paracetamol. Vitamin C and micronized vitamin C restored the measured parameters nearly to their normal levels. Histopathological changes indicated the protective nature of the Vitamin C and micronized vitamin C against paracetamol-induced hepatic damage. **CONCLUSION:** The present study demonstrated that, micronized vitamin C has a more potent effect than ordinary vitamin C against paracetamol induced hepatotoxicity in rats.

Key words: Vitamin C, micronized vitamin C, paracetamol, hepatotoxicity, antioxidants, DNA fragmentation, caspase-3.

INTRODUCTION

Paracetamol or acetaminophen is a widely used analgesic (pain reliever) and antipyretic (fever reducer) all over the world. It is commonly used for the relief of headaches, other minor aches and pains, and is a major ingredient in numerous cold and flu remedies. In combination with opioid analgesics, paracetamol can also be used in the management of more severe pain such as post surgical pain and providing palliative care in advanced cancer patients (SIGN, 2008).

Paracetamol is a member of the class of drugs known as

"aniline analgesics"; it is the only such drug that is still in use till now (Bertolini et al., 2006). It is classified as a nonsteroidal anti-inflammatory drug (NSAID) by some authors (Keith et al., 2001) and not as NSAID by others (Acetaminophen. chemicaland21.com, 2011). Paracetamol has few anti-inflammatory effects in comparison to NSAIDs. However, aspirin, paracetamol and other NSAIDs all act by the same mechanism (inhibition of prostaglandin synthesis). All of them show varying levels of analgesic, anti-inflammatory, antipyretic and antiplatelet effects (Byrant et al., 2007).

The onset of analgesia is approximately 11 minutes after oral administration of paracetamol and its half-life is 1- 4 hours. While generally safe for use at the recommended doses (1,000 mg per single dose and up to 4,000 mg per

*Corresponding author. E-mail:kamelmagha@hotmail.com

day for adults)^[4], acute overdoses of paracetamol can cause potentially fatal liver damage and, in rare individuals, a normal dose can do the same; the risk is heightened by alcohol consumption. Paracetamol toxicity is the foremost cause of acute liver failure in the Western world and accounts for most drug overdoses in the United States, the United Kingdom, Australia and New Zealand (Daly et al., 2008; Khashab et al., 2007).

Vitamin C (ascorbic acid) is a naturally occurring, water-soluble vitamin. It is the most abundant antioxidant in plants and is used in agriculture to enhance plant stress-resistance (Smirnoff, 2000). Vitamin C and its derivatives are not endogenously produced and must be obtained from dietary sources. It is widely distributed in many natural products, as fresh fruits and leafy vegetables which are the richest sources of vitamin C (Haytowitz, 1995). Vitamin C is also one of the most important water soluble antioxidant in animal and human (Mandl et al., 2009). It is recorded that vitamin C reduces oxidative stress in many tissues exposed to oxidative stressors (Acharya, 2008). It is known to promote collagen synthesis and wound healing. Although vitamin C is not a sunscreen, it has a protective effect against ultraviolet (UV) light exposure (Colvon et al., 1996).

Micronization is the process of reducing the average diameter of a solid material's particles. Usually, the term micronization is used when the particles that are produced are only few micrometers in diameter. Traditional micronization techniques are based on friction to reduce particle size. Such methods include milling, bashing and grinding. Methods like crushing and cutting are also used for reducing particle diameter, but produce more rough particles. Cutting uses sharp blades to cut the rough solid pieces into smaller ones. Modern methods use supercritical fluids in the micronization process. The most widely applied techniques of this category include the RESS process (Rapid Expansion of Supercritical Solutions), the SAS method (Supercritical Anti-Solvent) and the PGSS method (Particles from Gas Saturated Solutions) (Wikimedia foundation, 2012). Micronization enhances the solubility and the bioavailability of many compounds by increasing the dissolution rate of these compounds (Micron technologic, 2011). Although some studies are available about the protective effect of ordinary vitamin C against paracetamol-induced hepatotoxicity, no available studies concerning the effect of micronized vitamin C against paracetamol-induced liver injury. So the present study aimed to investigate the effects of two different Vitamin C formulations (ordinary vitamin C and micronized vitamin C) on liver in order to find which formulation show a better hepatoprotective role by performing in vivo and in vitro tests.

MATERIALS AND METHODS

Chemicals

Paracetamol was purchased as a commercial drug From Aventis Company, Egypt. (Novaldol 1000)^R each tablet contains 1gm paracetamol.

Vitamin C was purchased from Sigma Aldrich, UK. Micronized vitamin C was purchased from Coophavet representative office, Egypt.

Experimental animals

This study was approved by the Committee of Scientific Ethics at Beni-Suef University, Egypt, and was carried out in accordance with its guidelines for animal use.

Forty male Albino Wistar rats weighing average 200-250 grams were used in this study. They were obtained from the Animal House of the Research Institute of Ophthalmology (Giza, Egypt). They were kept under suitable conditions for one week for adaptation. They were maintained in stainless steel cages in a well-ventilated animal house at normal temperature (22 ± 5 °C) under 12:12 h light dark cycle. They were fed with standard diet and given water ad libitum. The rats were maintained under standard conditions in an animal house as per the guidelines of Beni-Suef University Committee for the Purpose of Control and Supervision on Experiments on Animals. The rats were randomly divided into four equal groups (10 rats each).

Group I: (Control group) was orally given a dose of sterile phosphate-buffered physiological saline (0.5 mL) in two successive doses 24 hours interval.

Group II: (Paracetamol treated group): rats were orally given paracetamol (paracetamol) at a dose of 600 mg/kg body weight in two doses with 24 hours interval (Pandey, 2008).

Group III: (Vitamin C-paracetamol treated group): rats were orally administered vitamin C at a dose of 500 mg/ /kg body weight/ day for six successive days (Adikwu and Deo, 2013) and they were also orally given paracetamol at a dose of 600 mg/kg body weight on the third and fourth days of administration.

Group IV: "Micronized vitamin C-paracetamol treated group" rats were orally administered micronized vitamin C 500 mg/kg body weight every 24 hours for six successive days and they were also orally given paracetamol at a dose of 600 mg/kg body weight on the third and fourth days of administration. The rats of all groups were scarified after 24 hours of the last administration. Blood samples were collected for biochemical studies and liver sections were taken for histological examination.

METHODS

Biochemical studies

The following parameters were measured in either serum or tissue homogenate of the four tested rat groups according to the instructions of their referred methods; serum ALT, AST, ALP and total protein were measured by using Diamond measuring kits (Egypt). After scarification of rats, liver was collected and kept in the deep freezer for homogenization. 0.5 gm of liver was homogenized in 5 ml normal saline by using homogenizer (Ortoalresa, Spain). The homogenates were centrifuged at 1000 X g for 15 minutes. The supernatant were collected in epindorff tubes that were kept

in the deep freezer (at - 20°C) for further biochemical investigations. Reduced glutathione (GSH), Catalase, superoxide dismutase (SOD), glutathione reductase (GR) and Malondialdehyde (MDA) were measured in tissue homogenates by using Bio diagnostic colorimetric assay kits (Biodiagnostic, Cairo, Egypt). Liver DNA fragmentation was measured by method described by Burton, (1956).

Histopathological studies

Liver sections were fixed in 10% formol saline and were processed to prepare 5- μ m thick paraffin sections for hematoxylin and eosin to verify the histological details (Bancroft and Gamble, 2002). Other sections were used for immunohistochemical staining for anticlaved caspase-3 (Gown and Willingham, 2002). Immunohistochemistry procedure for active caspase-3 (AB3623, Millipore, Temecula, CA, USA,) and Polyclonal antibody was also performed. After deparaffinization and rehydration, sections were then treated with 10 mM citrate buffer (Cat No. AP-9003-125 LabVision) (pH 6) in a microwave oven for 5 minutes. Then sections were washed with PBS and incubated in a solution of 3% H₂O₂ for 5 min at room temperature to inhibit endogenous peroxidase activity. After washing with PBS sections were incubated with normal serum blocking solution at 37°C for 30 min. Sections were again incubated in a humid chamber for 18 h at +4°C with antibody active caspase-3 (1/100); thereafter with biotinylated IgG, and then with streptavidin conjugated to horseradish peroxidase at 37°C for 30 min each prepared according to kit instructions (Invitrogen-Plus Broad Spectrum 85-9043). Sections were finally stained with DAB (Roche Diagnostics, Mannheim, Germany) and counter-stained with mayer hematoxylin and analyzed by using a light microscope.

Image capture

Tissue sections were examined and images were digitally captured using a hardware consisting of a high resolution color digital camera mounted on a Leica microscope (Leica, Germany), connected to a computer, and then analyzed using Adopen Photoshop.

Morphometry

Caspase-3 immunolabeled cells were counted in 10 adjacent non-overlapping fields of the tissue sections of each rat. The total number of hepatocytes was also assessed by counting their nuclei in the same fields. The ratio between numbers of caspase-3-immunolabeled hepatocytes to the total number of hepatocytes was calculated in each experimental group (Gown and Willingham, 2002). The percentage range was calculated for each group.

Data handling and statistics

Analysis of the data was carried out using SPSS version 13 (SPSS Inc., Chicago, Illinois, USA). Data were expressed as

means and standard errors of means. Student's *t*-test was used to compare between each two groups. Differences were considered statistically significant when the probability (*p* value) is less than 0.05.

RESULTS

Measurement of liver enzymes (ALT, AST and ALP) and total proteins in the serum of rats of the four tested groups revealed that there was a significant increase in liver enzymes ($P < 0.001$) in paracetamol treated group as compared to each of the control, paracetamol-vitamin C and paracetamol-micronized vitamin C treated groups. On the other hand, there was a significant decrease in total proteins ($P < 0.001$) in paracetamol treated group in comparison with each of the other three groups. It was noticed that no significant variations in biochemical parameters between paracetamol-micronized vitamin C and control groups, while there was a significant difference in biochemical parameters between paracetamol-vitamin C and paracetamol-micronized vitamin C treated groups (Table 1).

Measurement of liver tissue homogenates contents of lipid peroxidation "MDA" and antioxidant parameters "GSH, catalase, GR and SOD" showed that there was a significant decrease of GSH and GR activity ($P < 0.001$) in paracetamol treated group compared to each of the other three groups. On contrary, there was a significant increase in MDA, catalase and SOD ($P < 0.001$) in paracetamol treated group as compared to each of the other three groups. Our results showed that no significant alterations in oxidative and antioxidant parameters between paracetamol-micronized vitamin C and control groups, while there was a significant difference in oxidative and antioxidant parameters between paracetamol-vitamin C treated and paracetamol-micronized vitamin C treated groups (Tables 2 and 3).

Measurement of the liver DNA fragmentation percent of the rats of the four tested groups revealed that paracetamol administration significantly increased liver DNA fragmentation percent ($P < 0.05$) in paracetamol treated group when compared to that of the control group. Vitamin C treatment significantly decreased liver DNA fragmentation percent ($P < 0.05$) to be approximately near that of the control. Micronized vitamin C treatment also decreased liver DNA fragmentation percent to be exactly similar to that of the control (Figure 1).

Histological and immunohistochemical studies

Hematoxylin and eosin-stained sections

Tissue sections of control group presented a normal lobular architecture (Figure 2 A). The hepatocytes radiated from the central vein forming anastomosing plates of liver cells, separated from each other by

Table 1. Changes in serum ALT, AST, ALP activities and total proteins concentration in response to paracetamol, vitamin C and micronized vitamin C administration.

Item	ALT (U/L)	AST (U/L)	ALP(U/100mL)	Total proteins (g/dl)
Control group	19.48± 0.62	49.6 ± 2.2	95.08 ± 2.9	5.7 ± 0.18
Paracetamol treated group	64.97 ± 3.24	150 ±1. 36	190.5 ± 4.5	2.36 ± 0.44
Paracetamol - vitamin C treated group	34.52 ± 1.78	76.5 ± 4.2	110.4 ± 2.9	3.85 ± 0.28
Paracetamol - micronized vitamin C treated group	21.26 ± 2.1	48.22 ± 3.5	94.82 ± 2.5	5.63 ± 0.22
Stastical analysis				
Control VS				
paracetamol	<i>P</i> < 0.001	<i>P</i> < 0.001	<i>P</i> < 0.001	<i>P</i> < 0.001
Paracetamol + Vit. C	<i>P</i> < 0.001	<i>P</i> > 0.05	<i>P</i> < 0.05	<i>P</i> < 0.001
Paracetamol + Micronized Vit. C	ns <i>P</i> > 0.05	ns <i>P</i> > 0.05	ns <i>P</i> > 0.05	ns <i>P</i> > 0.05
Paracetamol VS				
Paracetamol + Vit. C	<i>P</i> < 0.001	<i>P</i> < 0.001	<i>P</i> < 0.001	<i>P</i> < 0.01
Paracetamol + Micronized Vit. C	<i>P</i> < 0.001	<i>P</i> < 0.001	<i>P</i> < 0.001	<i>P</i> < 0.001
Paracetamol + Vit. C VS				
Paracetamol + Micronized. Vit. C	<i>P</i> < 0.001	<i>P</i> < 0.05	<i>P</i> < 0.05	<i>P</i> < 0.001

These values represent means and standard errors, VS means versus.

irregular vascular spaces, hepatic sinusoids. The hepatocytes appeared polyhedral with acidophilic cytoplasm and large central rounded vesicular nuclei with prominent nucleoli (Figure 2B). Portal tracts contained many structures including branches of portal vein with large diameter and thin wall, branches of hepatic artery with small diameter and thick wall and branches of bile duct (inset of Figure 2B).

In paracetamol treated group; marked morphological changes appeared. It exhibited disrupted lobular architecture with hemorrhage. There was marked hepatic injury, especially in the pericentral region, characterized by hepatocellular degeneration. The periportal injury was weak. Central vein seemed to be congested. (Figs. 2C, D, E).

In paracetamol-vitamin C treated group, livers preserved the general architecture and lacked evidence of major morphological injury. Hepatocytes degeneration appeared to be remarkably reduced, but congestion still appear in blood sinusoids. (Figure 2F).

In paracetamol-micronized vitamin C treated group, livers also preserved the general architecture and lacked evidence of major morphological injury. Almost hepatocytes appear normal with acidophilic cytoplasm and vesicular nuclei (Figure 2G).

Figure 2. Photomicrographs of rat liver tissues of (A) the control group showing normal lobular architecture. with

hepatocytes radiated from the central vein (CV). Portal tracts contained branches of portal vein (PV) (H&E: X 10), (B) the control group showing the central vein (CV) from which hepatocytes with acidophilic cytoplasm and vesicular nuclei (black arrows) are radiated from in plates separated by sinusoids (white arrows) (arrow). Portal tracts contained branches of portal vein (PV), hepatic artery (HA) and bile duct (BD) (inset) (H&E x40, inset X 40), (C) Paracetamol treated group showing disrupted lobular architecture with dilated blood sinusoids (white arrows) and degenerated hepatocytes (black arrows) around central vein (CV) (H&E X40), (D) Paracetamol treated group showing dilated congested central vein (CV) degenerated hepatocytes (white arrows) some hepatocytes with pyknotic nuclei and acidophilic cytoplasm (black arrows) (H&E X40), (E) paracetamol treated group showing dilated degenerated hepatocytes (black arrows) and some hepatocytes with hemorrhage (black arrows) (H&E X40), (F) paracetamol-vitamin C treated group showing dilated congested central vein (CV). Almost hepatocytes are normal except few with vacuolated cytoplasm (black arrows). Congested blood sinusoids also appear (white arrows) (H&E X40), (G) Paracetamol-micronized vitamin C treated group showing retained lobular architecture. Hepatocytes retained their normal appearance with acidophilic cytoplasm and vesicular nucleus (H&E X40).

Table 2. Changes in liver reduced glutathione (GSH), catalase and malonaldehyde (MDA) in response to paracetamol, vitamin C and micronized vitamin C administration.

Item	GSH (mg/gm tissue)	Catalase (U/gm tissue)	MDA (nmol/gm tissue)
Control group	68.26 ± 1.8	2.31 ± 2.8	28.6 ± 0.82
Paracetamol treated group	34.02 ± 3.12	6.6 ± 0.38	55.76 ± 4.7
Paracetamol - vitamin C treated group	50.28 ± 1.77	3.89 ± 0.37	41.24 ± 1.06
Paracetamol - micronized vitamin C treated group	65.62 ± 1.89	2.38 ± 0.23	28.56 ± 0.48

♀ Stastical analysis

Control VS

paracetamol	$P < 0.001$	$P < 0.001$	$P < 0.001$
Paracetamol + Vit. C	$P < 0.001$	$P < 0.01$	$P < 0.01$
Paracetamol + Micronized Vit. C	ns $P > 0.05$	ns $P > 0.05$	ns $P > 0.05$

Paracetamol VS

Paracetamol + Vit. C	$P < 0.001$	$P < 0.001$	$P < 0.01$
Paracetamol + Micronized Vit. C	$P < 0.001$	$P < 0.001$	$P < 0.001$

Paracetamol + Vit. C VS

Paracetamol + Micronized. Vit. C	$P < 0.001$	$P < 0.05$	$P < 0.01$
----------------------------------	-------------	------------	------------

These values represent means and standard errors, VS means versus.

Immunolabeled sections

Liver sections of control group displayed normal lobular architecture with no detectable immunolabeling for activated caspase-3 (apoptotic marker) (Figure 3A). Paracetamol treated group showed obvious high immunolabeling for activated caspase-3 especially around central vein (Figure 3B). Pretreatment of rats with vitamin C resulted in decreased caspase-3-immunolabeled cells which were mainly localized in the pericentral area (Figure 3C). Pretreatment of rats with micronized vitamin C completely abolished the positive immunolabeling for activated caspase-3 (Figure 3D).

Figure 3. Rat liver tissues labeled for activated caspase-3 in (A) the control group showing no detectable immunolabeling. CV, central vein (Immunohistochemistry counterstained with H X 40), (B) Paracetamol treated group showing extensive positive reaction of hepatocytes clustered around central vein (CV). Immunolabeling in most positive cells was both cytoplasmic and nuclear (Black arrows), whereas some cells showed nuclear immunolabeling (white arrows) (Immunohistochemistry counterstained with H X 40). (C) Paracetamol-vitamin C treated group showing few

positive cells (black arrow) around central vein (CV) (Immunohistochemistry counterstained with H X 40). (D) Paracetamol-micronized vitamin C treated group showing negative reaction. CV, central vein (Immunohistochemistry counterstained with H X 40).

Morphometric results

There was a significant increase in positivity of caspase-3-immunolabeled hepatocytes in paracetamol treated group compared with the control, whereas a significant decrease was observed in paracetamol-vitamin C treated and paracetamol-micronized vitamin C treated groups. The expression of caspase 3 in hepatocytes of paracetamol- micronized vitamin C treated group is significantly lower than that of ordinary vitamin C (Table 4).

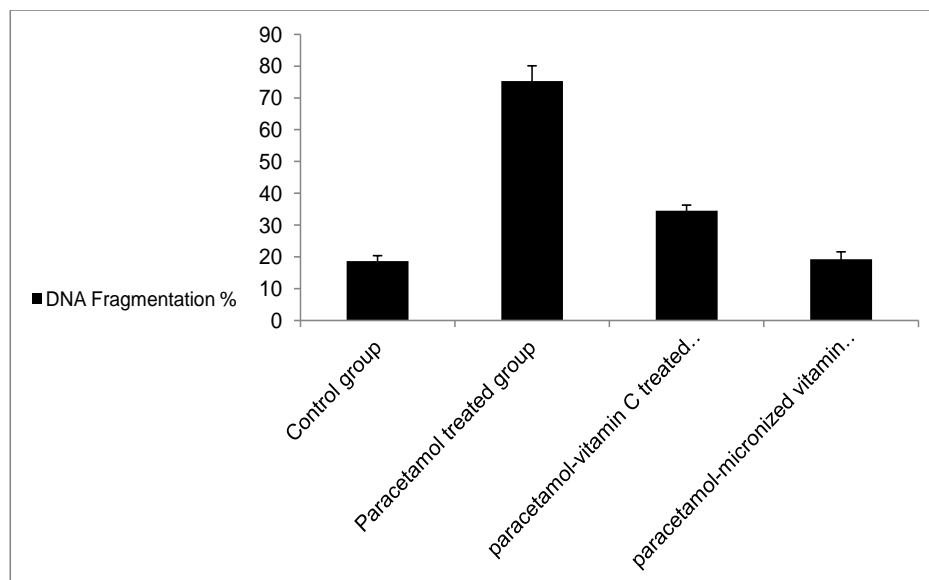
DISCUSSION

Various studies have proven the protective effects of vitamin C against paracetamol induced hepatotoxicity

Table 3. Changes in liver superoxide dismutase (SOD) and glutathione reductase (GR) activities in response to paracetamol, vitamin C and micronized vitamin C administration.

Item	SOD (U/gm tissue)	GR (U/gm tissue)
Control group	113.2 ± 4.69	352.9 ± 14.16
Paracetamol treated group	322.5 ± 12.69	123.9 ± 11.22
Paracetamol - vitamin C treated group	227.9 ± 13.36	266.3 ± 14.59
Paracetamol - micronized vitamin C treated group	125 ± 7.26	326.6 ± 15.37
Stastical analysis		
Control VS		
paracetamol	$P < 0.001$	$P < 0.001$
Paracetamol + Vit. C	$P < 0.001$	$P < 0.001$
Paracetamol + Micronized Vit. C	ns $P > 0.05$	ns $P > 0.05$
Paracetamol VS		
Paracetamol + Vit. C	$P < 0.001$	$P < 0.001$
Paracetamol + Micronized Vit. C	$P < 0.001$	$P < 0.001$
Paracetamol + Vit. C VS		
Paracetamol + Micronized. Vit. C	$P < 0.001$	$P < 0.05$

These values represent means and standard errors, VS means versus.

**Figure 1.** Changes in liver DNA fragmentation percent in response to paracetamol, vitamin C and micronized vitamin C administration.

(Kon, et al., 2007; Green, 2000; Jonker et al., 1988; Mitra et al., 1988; Miller and Jollow, 1984; Peterson and Knodell, 1984; Hargreaves et al., 1982; Lake et al.,

1981). However, there were no available studies to evaluate the effect of micronized vitamin C on paracetamol-induced liver injury. The aim of this study

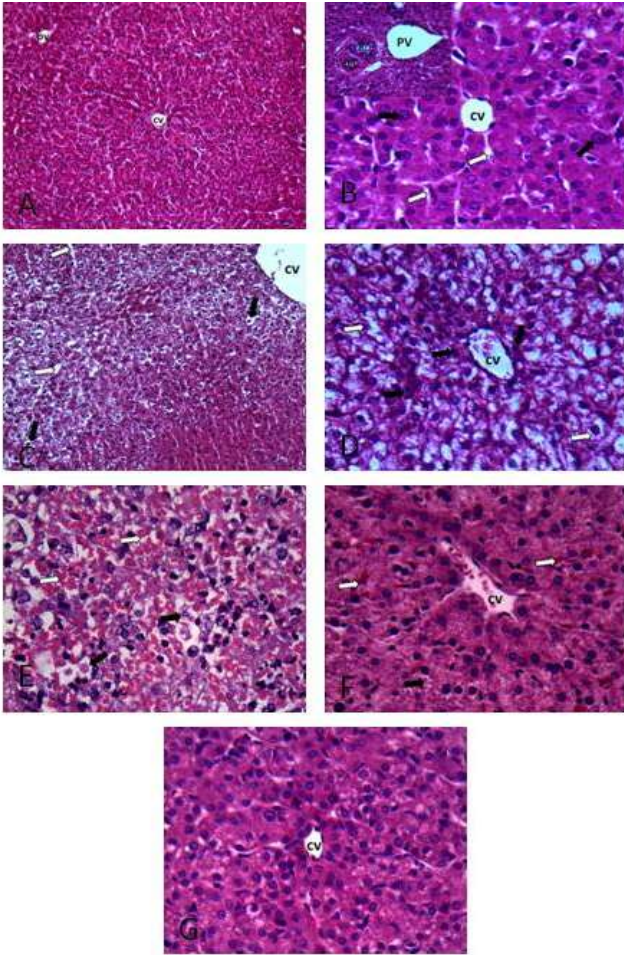


Figure 2.

was to assess the protective effect of micronized vitamin C against paracetamol induced liver injury and compare it with hepatoprotective effect of the ordinary vitamin C.

Serum ALT and AST are the most sensitive markers used in the diagnosis of hepatic damage. They are cytoplasmic enzymes released into circulation after cellular damage in acute hepatotoxicity (Mitra et al., 1991). Our results showed that paracetamol caused a significant increase in activities of liver enzymes (ALT, AST and ALP) when compared with rats of control group (Table 1). In addition, paracetamol administration caused a marked decrease in total proteins (Table 1). These findings supported the hepatotoxic effect of paracetamol taking in consideration that liver is the main factory for albumin synthesis which represents the major fraction of serum total proteins. These findings come in agreement with Kanbur et al. (2009) who found that administration of paracetamol caused a significant release of liver enzymes into circulation.

As ALT is an enzyme specific to liver damage, and is used routinely for the determination of liver damage, the observed increase in the serum ALT activity is

considered to be a significant indicator of paracetamol-induced acute liver damage as confirmed by Sener et al. (2005).

In addition, our results showed that administration of paracetamol caused a significant increase in hepatic lipid peroxidation level (MDA), depletion of GSH contents (Table 2) and decreased GR activity (Table 3) as compared to that of rats of control group. In addition, paracetamol administration caused a significant increase in hepatic catalase "CAT" (Table 2) and SOD (Table 3) activities.

These findings come in agreement with the results obtained by Manimaran et al. (2010) who found that paracetamol induced hepatic oxidative damage and alteration of hepatic GSH contents, GR and GPXs activities.

Wallace (2004) suggested that liver damage is not due to the paracetamol itself but to its toxic metabolite (*N*-acetyl-*p*-benzoquinone imine NAPQI) which is produced by cytochrome P-450 enzymes in the liver. The resulting metabolite covalently binds to oxidized lipids and sulphhydryl groups of the liver tissue, and thereby leads to the severe damage of cell membranes (Kupeli et al., 2006).

It is believed that, when 70% of hepatic GSH is consumed, NAPQI (the reactive metabolite of paracetamol) becomes available for inducing a cascade that may result in hepatic cell death (Larson, 2007). Paracetamol reduced hepatic GSH by 60–90%, indicating inefficient detoxification of NAPQI and its eventual availability for interaction with the cellular macromolecules. Moreover, GSH is consumed for detoxification of ROS and peroxides. Therefore, conjugation of GSH with these electrophiles and free radicals could be another cause for GSH depletion. Paracetamol mediated increase in SOD activity indicates the occurrence of oxidative stress. This coupled with the reductions in GR and increased CAT activities, that neutralize H_2O_2 , imply accumulation of H_2O_2 and more production of the ultimate toxicant hydroxyl radical (OH^\cdot) via Fenton reaction. The increase in LPO, a free radical-dependent mechanism, further supports the excess generation of intracellular ROS – considered as a critical event in the development of acetaminophen hepatotoxicity (Larson, 2007).

Hence a toxic dose of paracetamol causes a 90% depletion of total hepatic GSH level and as a result the metabolite binds to cysteine in protein, forming paracetamol proteins adducts (Cohen and Khairallah, 1997). However, once GSH reserves are depleted, multiple perturbations ensure that ultimately culminate in cell death. Events that produce hepatocellular death following paracetamol application are poorly understood. Another possible mechanism of paracetamol induced cell death is that covalent binding to cellular proteins results in subsequent loss of activity or function and eventual cell lysis. Primary targets have been concluded to be mitochondrial proteins, with resulting loss of energy

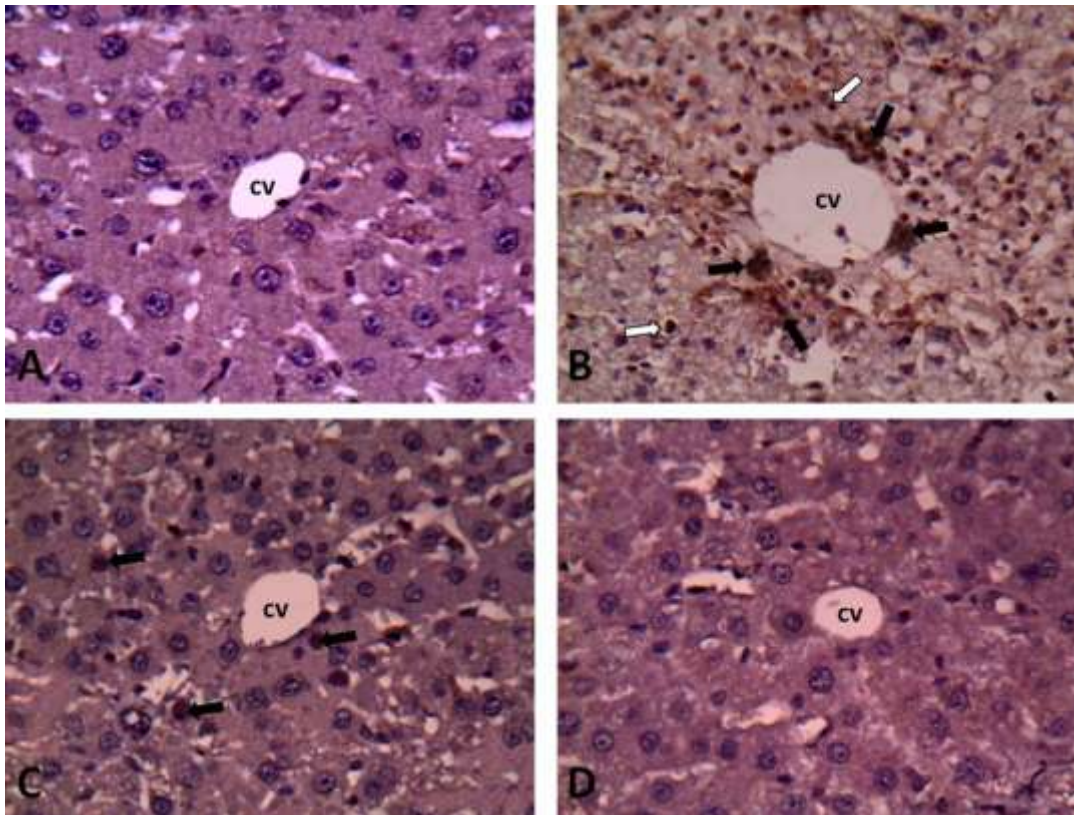


Figure 3.

production as well as proteins involved in cellular ion control (Nelson, 1990).

Paracetamol caused a significant increase in hepatocytes DNA damage as compared to normal rats (Fig. 1). These results are in agreement with the results obtained by Ghosh and Sil (2009) who reported that DNA damage caused by oxygen-derived species including free radicals that can produce a multiplicity of modifications in DNA including base and sugar lesions, strand breaks, DNA-protein cross-links and base-free sites. If left unrepaired, oxidative DNA damage can lead to detrimental biological consequences in organisms, including cell death, mutations and transformation of cells to malignant cells. Our findings are parallel to those recorded by Ramachandran et al. (2011) who found that administration of paracetamol caused a significant increase in DNA fragmentation.

DNA fragmentation is a hallmark of paracetamol hepatotoxicity (Larson, 2007). The frequently reported DNA ladder formation suggests that the DNA fragmentation is an endonuclease-mediated process (Gujral et al., 2002).

The study showed that liver injury by paracetamol had marked hepatocellular degeneration. These morphological findings were in accordance with the results of Matsunaga et al. (2004). Amaral et al. (2013) confirmed these results with *in vitro* paracetamol

administration to primary mouse hepatocytes that caused cell death in a dose-dependent manner. They showed that, exposure of hepatocytes to paracetamol elicited significant release of ATP to the supernatant in levels that were high enough to promote direct cytotoxicity to healthy hepatocytes. The concentration of the previous changes in the pericentral area (zone three) could be explained by the fact that the cells in zone three are especially rich in enzymes involved in drug metabolism (Matsunaga et al., 2004).

Caspase-3 activation is a hallmark of almost all paracetamol induced toxicity (Green, 2000). The expression of activated caspase-3 in hepatocytes was enhanced by paracetamol, indicating the involvement of activated caspase-3 in the intrinsic pathway of apoptosis induced by paracetamol (Kon et al., 2007). In this study, it was found that paracetamol administration markedly increased the expression of active caspase-3 in rat liver tissues. In terms of expression, these results coincide with Kon et al. (2007), who found numerous hepatocytes positively stained for activated caspase-3 in liver sections of mice treated with paracetamol for 6 hours. The labeling distribution pattern for activated caspase-3 in rat liver sections of paracetamol treated group also coincided with hematoxylin and eosin findings where the observed numbers of positive cells (apoptotic cells) were increased in the pericentral area.

Table 4. Active caspase-3 immunolabeled hepatocytes of different experimental groups (n= 10 animals per group).

Group	Mean \pm SEM	Range (%)
Control group	0.16 \pm 0.3	0-0.31
Paracetamol treated group	35.17 \pm 5.4	9-20.3
Paracetamol - vitamin C group	4 \pm 3.55	1-2.5
Paracetamol - micronized vitamin C group	1 \pm 0.41	0-0.8
Stastical analysis		
Control VS		
paracetamol	$P < 0.001$	
Paracetamol + Vit. C	ns $P > 0.05$	
Paracetamol + Micronized Vit. C	ns $P > 0.05$	
Paracetamol VS		
Paracetamol + Vit. C	$P < 0.001$	
Paracetamol + Micronized Vit. C	$P < 0.001$	
Paracetamol + Vit. C VS		
Paracetamol + Micronized. Vit. C	ns $P > 0.05$	

These values represent means and standard errors, VS means versus.

The enhanced expression of activated caspase-3 in hepatocytes during paracetamol induced hepatotoxicity confirmed the involvement of the caspase-activated DNase, which is the classical endonuclease responsible for apoptotic DNA fragmentation (Nagata et al., 2003).

Our results showed that administration of vitamin C decreased activities of liver enzymes in serum as compared to paracetamol treated group (Table 1). In addition, vitamin C modulated the antioxidant status of liver by increasing GSH content and decreasing the LPO level (Table 2), catalase (Table 2) and SOD activities (Table 3). Moreover, vitamin C administration returned the DNA fragmentation % of the Paracetamol-vitamin C treated group to nearly that of the control group.

Administration of vitamin C before paracetamol showed marked reduction in the histopathological changes. These results are in agreement with Peterson and, Knodell (1984) who reported the reducing effect of vitamin C on hepatocellular damage observed with administration of paracetamol evidenced by the slow plasma disappearance of paracetamol suggesting that in vivo metabolism of paracetamol was altered by vitamin C treatment. Jonker et al. (1988) demonstrated that vitamin C co-administered orally with the analgesic is an effective inhibitor of paracetamol-induced hepatotoxicity in the mouse. They added that the mechanism by which vitamin C prevents liver injury appears to involve destruction of reactive paracetamol metabolites which is associated with a sparing action on liver toxicity.

In this study, Vitamin C administration abolished the immunolabeling for activated caspase-3 caused by paracetamol; this is in agreement with Singh and Rana

(2010) who attributed restriction of apoptosis to caspase-3 inhibition. They added that vitamin C could protect DNA from the attack of reactive oxygen species generated by paracetamol.

Administration of micronized vitamin C showed significant decrease activities of liver enzymes (ALT, AST and ALP) in serum and marked increase of serum total protein as compared to ordinary vitamin C treated group (Table 1). Moreover, Micronized vitamin C posses more protective effect against paracetamol hepatic induced oxidative damage through increasing GSH concentration, (Table 2) and activity of GR (Table 3), decreasing activities of catalase, SOD and MDA concentration. In addition, micronized vitamin C has a more potent effect on DNA fragmentation that ordinary vitamin C (Fig. 1).

In the present study, when micronized vitamin C was administered prior, during and after a toxic dose of paracetamol (600 mg/kg), rats were dramatically protected against hepatotoxicity, as revealed by H&E-stained liver sections showing no significant liver damage compared with rats only treated with paracetamol.

It is noticed that micronized vitamin C (Fig. 2G) has a more potent protective effects against histopathological damage induced by paracetamol (Figs. 2C, D, E) than ordinary vitamin C (Fig. 2F). Our study revealed that micronized vitamin C retained the measured hepatotoxic markers into its normal levels. The more protective effect of micronized vitamin C could be contributed to the benefits of micronization as micronization increases the bioavailability of vitamin C than ordinary macromolecule. This work is a novel as there is a very few available literature about the application and uses of micronized

vitamin C.

CONCLUSION

In conclusion, the results of this study provide evidence for the protective and curative effect of vitamin C against paracetamol induced hepatotoxicity in rats. The protective effect of micronized vitamin C is more

effective than ordinary vitamin C. The antiapoptotic effect of Vitamin C was evident. In spite of the promising results of this study, further studies including different doses of vitamin C and micronized vitamin C are required in order to look for the dose able to restore the liver to its exact normal appearance. Also detailed studies concerning the therapeutic efficacy, safety and stability of a combined fixed dose of vitamin C and paracetamol are needed.

REFERENCES

- Acetaminophen. chemicalland21.com (2011). doi:10.1158/0008-5472.CAN-07-6257b.
- Acharya UR, Mishra M, Patro J, Pana MK (2008). Effect of vitamin C and E on spermatogenesis in mice exposed to cadmium. *Reprod. Toxicol.*, 25: 84- 88.
- Adikwu E, Deo O (2013). Hepatoprotective Effect of Vitamin C (Ascorbic Acid). *Pharmacology and Pharmacy*, 4 (1): 84 – 92.
- Amaral SS, Oliveira AG, Marques PE, Quintão JL, Pires DA, Resende RR, Sousa BR, Melgaço JG, Pinto MA, Russo RC, Gomes AK, Andrade LM, Zanin RF, Pereira RV, Bonorino C, Soriani FM, Lima CX, Cara DC, Teixeira MM, Leite MF, Menezes GB (2013). Altered responsiveness to extracellular ATP enhances acetaminophen hepatotoxicity. *Cell Commun Signal*, 11(1):10.
- Bancroft JD, Gamble M (2002). *Theory and practice of histological techniques*. 5th ed. New York, London, Philadelphia: Churchill Livingstone.
- Bertolini A, Ferrari A, Ottani A, Guerzoni S, Tacchi R, Leone S (2006). Paracetamol: new vistas of an old drug. *CNS Drug Rev.*, 12: 250–275.
- Burton K (1956). A study of the conditions and mechanism of the diphenylamine reaction for the colorimetric estimation of deoxyribonucleic acid. *Biochem J.* 62: 315-327.
- Byrant B, Knights K, Salerno E (2007). *Pharmacology for health professionals*. Elsevier, ISBN 9780729537872, pp. 270.
- Cohen SD, Khairallah EA (1997). Selective protein arylation and acetaminophen-induced hepatotoxicity. *Drug Metab. Rev.*, 29 : 59–77.
- Colvon RM, Pinnell SR (1996). "Topical Vitamin C in Aging" in *Clinics in Dermatology, Skin Aging, and Photoaging*. Antonio Ledo. ed., 14: 227–234.
- Daly FF, Fountain JS, Murray L, Graudins A, Buckley NA (2008). Guidelines for the management of paracetamol poisoning in Australia and New Zealand explanation and elaboration. A consensus statement from clinical toxicologists consulting to the Australasian poisons information centres". *Med. J. Aust.*, 188 (5): 296–301.
- Ghosh A, Sil PC (2009). Protection of acetaminophen induced mitochondrial dysfunctions and hepatic necrosis via Akt-NF- κ B pathway: Role of a novel plant protein. *Chemico-Biological Interactions*, 177 (2009) 96–106
- Gown AM, Willingham MC (2002). Improved detection of apoptotic cells in archival paraffin sections: immunohistochemistry using antibodies to cleaved caspase 3. *J Histochem Cytochem*, 50:449-454.
- Green DR (2000). Apoptotic pathways: paper wraps stone blunts scissors. *Cell*, 102: 1- 4.
- Gujral JS, Knight TR, Farhood A, Bajt ML, Jaeschke H (2002). Mode of cell death after acetaminophen overdose in mice: apoptosis or oncotic necrosis? *Toxicol. Sci.*, 67: 322–328.
- Hargreaves RJ, Evans JG, Pelling D, Butterworth KR (1982). Studies on the effects of L-ascorbic acid on acetaminophen-induced hepatotoxicity. II. An in vivo assessment in mice of the protection afforded by various dosage forms of ascorbate. *Toxicol Appl Pharmacol.*, 64(3):380-92.
- Haytowitz DB (1995). Information from USDA's Nutrient Data Bank. *J. Nutr.*, 125: 1952- 1955.
- Jonker D, Lee VS, Hargreaves RJ, Lake BG (1988). Comparison of the effects of ascorbyl palmitate and L-ascorbic acid on paracetamol-induced hepatotoxicity in the mouse. *Toxicology.*, 52(3):287-95.
- Kanbur M, Gokhan E, Latife B, Sibel S, Bilal CL, Sule A, Ayhan A (2009). The effects of royaljelly on liver damage induced by paracetamol in mice. *Experimental and Toxicologic Pathology*, 61: 123–132.
- Keith H, Derek JW, Andrew R (2001). *Medical pharmacology and therapeutics*. Philadelphia: W.B. Saunders. ISBN 0-7020-2272-1,
- Khashab M, Tector AJ, Kwo PY (2007). Epidemiology of acute liver failure. *Curr Gastroenterol Rep.*, 9 (1): 66–73.
- Kon K, Ikejima K, Okumura K, Aoyama T, Arai K, Takei Y, Lemasters JJ, Sato N (2007). Role of apoptosis in acetaminophen hepatotoxicity. *J Gastroenterol Hepatol.*, 22(1): 49-52.
- Kupeli E, Orhan DD, Yesilada E (2006). Effect of *Cistus laurifolius* L. leaf extracts and flavonoids on a

- acetaminophen-induced hepatotoxicity in mice. *J. Ethnopharmacol.* 103: 455-460.
- Lake BG, Harris RA, Phillips JC, Gangolli SD (1981). Studies on the effects of L-ascorbic acid on acetaminophen-induced hepatotoxicity. 1. Inhibition of the covalent binding of acetaminophen metabolites to hepatic microsomes in vitro. *Toxicol Appl Pharmacol*, 60(2):229-40.
- Larson AM (2007). Acetaminophen hepatotoxicity. *Clin. Liver Dis.*, 11: 525-548.
- Pandey G, Srivastava DN, Madhuri S (2008). A standard hepatotoxic model produced by paracetamol in rat. *Toxicology International*, 15 (1): 69-70.
- Peterson FJ, Knodell RG (1984). Ascorbic acid protects against acetaminophen- and cocaine-induced hepatic damage in mice. *Drug Nutr Interact.*, 3 (1):33-41.
- Nagata S, Nagase H, Kawane K, Mukae N, Fukuyama H (2003). Degradation of chromosomal DNA during apoptosis. *Cell Death Differ.*, 10: 108-116.
- Nelson, SD (1990): Molecular mechanisms of the hepatotoxicity caused by acetaminophen, *Semin. Liver Dis.*, 10 : 267-278.
- Mandl J, Szarka A, Banhegyi G (2009). Vitamin C update on physiology and pharmacology. *Br. J pharmacol.*, 157: 1097-1110. .
- Matsunaga N, Nakamura N, Yoneda N, Qin T, Terazono H, To H, Higuchi S, Ohdo S (2004). Influence of feeding schedule on 24-h rhythm of hepatotoxicity induced by acetaminophen in mice. *J Pharmacol Exp Ther.*, 311(2):594-600.
- Manimaran A, Sarkar SN, Sankar P (2010).. Influence of repeated preexposure to arsenic on acetaminophen-induced oxidative stress in liver of male rats. *Food Chem Toxicol*, 48 : 605-610.
- Micron technologies (2011). WWW.microtech.com.
- Miller MG, Jollow DJ (1984). Effect of L-ascorbic acid on acetaminophen-induced hepatotoxicity and covalent binding in hamsters. Evidence that in vitro covalent binding differs from that in vivo. *Drug Metab Dispos.*, 12(3):271-9.
- Mitra A, Kulkarni AP, Ravikumar VC, Bourcier DR (1991). Effect of ascorbic acid esters on hepatic glutathione levels in mice treated with a hepatotoxic dose of acetaminophen. *J Biochem Toxicol.*, 6(2):93-100.
- Mitra A, Ravikumar VC, Bourn WM, Bourcier DR (1988). Influence of ascorbic acid esters on acetaminophen-induced hepatotoxicity in mice. *Toxicol Lett.*, 44(1-2):39-46.
- Ramachandran A, Margitta L, Steven AW, Hartmut J (2011). The impact of partial manganese superoxide dismutase (SOD2)-deficiency on mitochondrial oxidant stress, DNA fragmentation and liver injury during acetaminophen hepatotoxicity, 25: 226-233.
- Scottish Intercollegiate Guidelines Network (SIGN) (2008). Scotland: National Health Service (NHS). ISBN 978 1 905813 38 4. <http://www.sign.ac.uk/pdf/SIGN106.pdf>.
- Sener G, Sehirli O, Cetinel S, Yegen BG, Gedik N, Ayanoglu-Dulger G (2005). Protective effects of MESNA (2-mercaptoethane sulphonate) against acetaminophen-induced hepatorenal oxidative damage in mice. *J Appl Toxicol.*, 25: 20-9.
- Singh S, Rana SV (2010). Ascorbic acid improves mitochondrial function in liver of arsenic-treated rat. *Toxicol Ind Health*, 26(5):265-72.
- Smirnoff N (2000). Ascorbic acid: metabolism and functions of a multi-faceted molecule. *Curr Opin Plant Biol.*, 3(3): 229-235.
- Wallace JL (2004). "Acetaminophen hepatotoxicity: NO to the rescue". *Br. J. Pharmacol.*, 143 (1): 1-2.
- Wikimedia foundation, (2012). <http://en.wikipedia.org/wiki/Micronization>.