

Full Length Research Paper

## Hepatoprotective activity of leaves of *Rhododendron arboreum* in CCl<sub>4</sub> induced hepatotoxicity in rats

T. Prakash<sup>1\*</sup>, Snehal Dayalal Fadadu<sup>1</sup>, Uday Raj Sharma<sup>1</sup>, V. Surendra<sup>1</sup>, Divakar Goli<sup>1</sup>, Perfect Stamina<sup>1</sup> and D. Kotresha<sup>2</sup>

<sup>1</sup>Department of Pharmacology, Acharya and BM. Reddy College of Pharmacy, Bangalore-560 090, Karnataka, India.

<sup>2</sup>Department of Biochemistry, Indian Institute of Science, Bangalore-560 012, Karnataka, India.

Accepted 17 October, 2019

The study was designed to evaluate the hepatoprotective activity of pre-treatment with ethanolic extract of leaves of *Rhododendron arboreum* against carbon tetrachloride-induced hepatotoxicity in Wistar rat model. Liver damage was induced in experimental animals by administering CCl<sub>4</sub>. The ethanolic extract of *R. arboreum* (40, 60 and 100 mg/kg, po) was given for five days. Silymarin (100 mg/kg, po) was given as the reference drug. Hepatoprotective effect was studied by assaying the activities of serum marker enzymes like SGPT, SGOT, ALP, direct and total bilirubin, triglycerides, cholesterol and estimation of ascorbic acid in urine. The activities of all the marker enzymes registered a significant elevation in CCl<sub>4</sub> treated rats, which were significantly recovered towards an almost normal level in animals co-administered with ethanolic extract of leaves of *R. arboreum* at a dose of 60 and 100 mg/kg. Ethanolic extract of leaves of *R. arboreum* prevented decrease in the excretion of ascorbic acid in CCl<sub>4</sub> induced hepatotoxicity in rats. Histopathological analysis confirmed the biochemical investigations. The results indicate that leaves of *R. arboreum* possess hepatoprotective property possibly because of its reported anti-oxidant activity. This property may be attributed to the quercetin related flavonoids, saponins and phenolic compounds present in the leaves of *R. arboreum*.

**Key words:** Hepatoprotective, *Rhododendron arboreum*, ascorbic acid, carbon tetrachloride, flavanoids

### INTRODUCTION

Liver is considered the key organ in the metabolism, detoxification and secretory functions in the body and its disorders are numerous with no effective remedies however the search for new medicines is still ongoing. Many folk remedies from plant origin have been long used for the treatment of liver diseases. Liver regulates various important metabolic functions. Hepatic damage is associated with distortion of these metabolic functions. Liver disease is still a world wide health problem. Unfortunately, conventional or synthetic drugs used in the treatment of liver diseases are inadequate and sometimes can have serious side effects. This is one of the reasons for many people in the world over including those in developed countries turning complimentary and alternative medicine. Many traditional remedies employ herbal drugs for the treatment of liver ailments.

*R. arboreum* is an important medicinal plant which is

used for treatment of various ailments in Ayurvedic system of medicine. The leaves of *R. arboreum* were reported to contain Quercetin 3-O- beta -D-glucopyranosyl [1->6]-O- alpha -L-rhamnopyranoside, pectolinarigenin 7-O-rutinoside, 7,2'-dimethoxy-4',5'-methylenedioxyflavanone (Kamil et al., 1995). Flavonoids, isolated from the leaves of *R. arboreum* were found to have potent antioxidant property (Dhan et al., 2007), the plant *R. arboreum* have been reported for anti- inflammatory (Shyam and Kalpana, 1988). In the absence of reliable liver protective drugs in modern medicine, there are numbers of medicinal preparations in the Ayurvedic system of Indian medicine re-commended for the treatment of liver disorders. Their usage is in vogue since centuries and are quite often claimed to offer significant relief. However, no scientific information is available regarding the hepatoprotective effect of *R. arboreum*. Since, antioxidants are known to reduce the development of chemically induced liver damage, the effect of ethanolic extract of leaves of *R. arboreum* has been evaluated for hepatoprotective activity.

\*Corresponding author. E-mail: [prakash\\_tigari@yahoo.com](mailto:prakash_tigari@yahoo.com)

## MATERIALS AND METHODS

### Plant material

Leaves of the plant *R. arboreum* were collected (in the month of October) from the surrounding fields of Meghalaya. The identification of plant was made by Mrs. J. M. Q. Lyngdoh, Lecturer, Department of Botany, K. N. G. College, Jowai, India. The voucher specimen (Ref No: 08/P.colog/2006-2007) of the plant material has been deposited in the Department of Pharmacology.

### Preparation of extract

The leaves of *R. arboreum* were washed thoroughly in tap water, shade dried and powdered. This powder was packed into Soxhlet column and extracted with petroleum ether (60 - 80°C) for 24 h. The same marc was successively extracted with chloroform (50 - 60°C) and later with ethanol (68 - 78°C) for 24 h. The extracts were concentrated on water bath (50°C). After concentrated preparation, the dried powder extract was stored at 4 C. The yield of the petroleum extract, chloroform extract and ethanolic extract were found to be 5% (w/w), 2.5% (w/w) and 12.5% (w/w) respectively. Ethanolic extract were used for the experimental study.

### Animals

Wister Albino rats (150 - 200 g) and Albino mice (20 - 25 g) of either sex procured from Bioneds animal house, Dhavas pet, Tumkur, were used for the study. The animals were kept in polypropylene cages and maintained at a temperature of  $26 \pm 2^\circ\text{C}$ . They were fed with standard diet supplied by Pranav agro industries Ltd. Sangli. The study has got the approval (Ref: IAEC/PP/08/2006-2007) from the Institutional Animal Ethical Committee (IAEC). All the animal experiments are conducted in accordance with the guidelines of the CPCSEA (Reg No. 997/c/06/CPCSEA), guide for care and use of laboratory animals. After procuring the animals were acclimatized for 10 days under standard husbandry conditions as: Relative humidity 45 - 55%, and 12 h light and dark cycle.

### Preliminary phytochemical screening

The preliminary phytochemical Screening was carried out on the petroleum ether, chloroform, and ethanolic extracts of leaves of *R. arboreum* for qualitative identification. Tests for common phytochemicals were carried out by standard methods described in practical Pharmacognosy by Khandelwal (2000).

### Acute toxicity study

The albino mice of 20 - 25 g body weight of either sex

were selected to find out the acute toxicity study of ethanolic extract of *R. arboreum* leaves. The dose of 5, 50, 300 and 2000 mg/kg were selected based on the fixed dose (OCED Guideline No. 420) method of CPCSEA. The extract was administered by intraperitoneally. The animals were continuously observed for 24 h to detect changes in autonomic or behavioral responses. Mortality in each group was observed for 7 days.

### Assessment of hepatoprotective activity

The animals were divided into six groups of six Wistar albino rats each. The animals were fasted for 24 h prior to carbon tetrachloride treatment. Group I was main-tained as normal control received normal saline 5 ml/kg orally. All the animals of group II to VI received carbon tetrachloride diluted with olive oil (1:1) at dose of 1 ml/kg, subcutaneously for two successive days (2<sup>nd</sup> and 3<sup>rd</sup> day). Group II animals were maintained as carbon tetrachloride control without any drug treatment. Group III, IV and V animals were treated with 40, 60 and 100 mg/kg etha-nolic extract respectively by or all route. Group VI animals were treated with Silymarin (100 mg/kg, orally) which served as standard group. The vehicle or drug treatment was carried out orally from 1<sup>st</sup> day to 5<sup>th</sup> day with con-current administration of carbon tetrachloride on 2<sup>nd</sup> and 3<sup>rd</sup> day. During the period of drug treatment the rats were maintained under normal diet and water *ad libitum*.

The animals of all the groups were sacrificed by light ether anesthesia on 6<sup>th</sup> day. The blood sample of each animal was collected separately by carotid artery into sterilized dry centrifuge tubes and allowed to coagulate for 30 min. Serum was separated by centrifugation 3000 rpm for 15 min. The serum was used to estimate serum glutamate pyruvate transaminase (SGPT), serum glutamate oxaloacetate transaminase (SGOT) (Henry et al., 1974), serum direct bilirubin and total bilirubin (Gambino, 1965), serum alkaline phosphatase (ALP) (Walter and Schutt, 1974), serum triglycerides (Fossati and Principe, 1982) and serum cholesterol (Deeg and Ziegenhorn, 1983). Livers were removed and preserved in 10% formalin solution for histopathological studies.

### Estimation of ascorbic acid in urine

Wister albino rats of either sex were divided into six groups each consisting of six animals. They were kept in metabolic cages for collection of urine. They were supplied with standard diet and water *ad libitum*, one week before and during the experimental period. Urine sample collected separately form each group in 5 ml of 10% oxalic acid solution and analyzed for ascorbic acid by the method of Roe and Kuether (1943) and their average value were taken as controls. Group I served as normal control, normal saline (10 ml/kg, orally) was given.

The rats of group II were treated with 0.7 ml/kg, orally of CCl<sub>4</sub>. Group II, III and IV were treated with ethanolic extract of *R. arboreum* at dose of 40, 60 and 100 mg/kg, orally, Group V served as Silymarin treated and after 1 h extract administration all the group were challenged with CCl<sub>4</sub> (0.7 ml/kg, po). The collection of 24 h urine samples was continued for a further period of 7 days for all groups and the sample were analysed for ascorbic acid.

### Histopathological observation

Liver tissue collected were used for the preparation of histopathological slides by using microtome and were suitably stained and observed under microscope for architectural changes seen during CCl<sub>4</sub> challenge in ethanolic extract of *R. arboreum* treated and control groups.

### Statistical analysis

The mean  $\pm$  S.E.M. was calculated for each parameter. Total variations, present in a set of data were estimated by one way analysis of variance (ANOVA), followed by Dunnet's't' test.  $P < 0.05$  was considered as statistically significant when compared to control group. The percentage of the protection is calculated as  $100 \times (\text{Values of CCl}_4 \text{ control} - \text{Values of test sample}) / (\text{Values of CCl}_4 \text{ control} - \text{Values of normal control})$ .

## RESULTS

Preliminary phytochemical investigations of different extracts of leaves of *R. arboreum* were studied. The petroleum ether extract contains phytosterols, saponins and fixed oils. The chloroform extract contains proteins. The ethanolic extract contains carbohydrates, saponins, flavonoids, phytosterols, tannins and phenolic compounds. In the acute toxicity study ethanolic extract of leaves of *R. arboreum* were found to be toxic (2/3 mice died) at a dose of 300 mg/kg, intraperitoneally. Hence, LD<sub>50</sub> cut off value of ethanolic extract was fixed as 300 mg/kg body weight. So, that 1/7<sup>th</sup>, 1/5<sup>th</sup> and 1/3<sup>rd</sup> of the LD<sub>50</sub> cut off value that is, 40, 60 and 100 mg/kg body weight were selected as screening dose for hepatoprotective activity.

Effect of ethanolic extract of *R. arboreum* on CCl<sub>4</sub> induced liver damage in rats with reference to biochemical changes in serum are shown in Table 1. At the end of the 5<sup>th</sup> day treatment, blood sample of CCl<sub>4</sub> treated control animals showed significant increase in the level of SGPT, SGOT, ALP, triglycerides and cholesterol compare to normal control. Pretreatment with *R. arboreum* extract at 60 and 100 mg/kg showed marked decreased of SGPT, SGOT, ALP, triglycerides and cholesterol as compared to the CCl<sub>4</sub> treated group. The maximum pro-

tection was shown by ethanolic extract at the dose of 100 mg/kg body weight (Table 1).

Bilirubin levels (total and direct) are shown in Table 1. The rats exposed to CCl<sub>4</sub> showed significant increased levels of bilirubin as compare to control. Pretreatment with *R. arboreum* extract showed significant ( $P < 0.01$ ) decreased level of total and direct bilirubin to the near normal which is comparable to the values registered in the standard drug treated (Silymarin) group of animals, indicating the protection of hepatic cells. Protection against CCl<sub>4</sub> induced hepatic damage at 40 mg/kg dose of extract was negligible in all these biochemical markers.

Figure 1 shows a magnification of the changes of liver histopathology from the normal control. Under the electronic microscope, normal cellular architecture with distinct hepatic cells, sinusoidal spaces and a central vein were observed in the normal control group (Figure 1A). However, CCl<sub>4</sub>-intoxicated treatment exhibited severe histopathological changes, such as centrilobular hepatic necrosis, fatty change, kupffer cell, ballooning degeneration, and infiltrating lymphocytes (Figure 1B). Pretreatment with 60 and 100 mg/kg of ethanolic extract of *R. arboreum* prevented these histopathological changes associated with the hepatotoxicity from CCl<sub>4</sub>-intoxicated treatment (Figure 1D and 1E). But the dose of 40 mg/kg treatment did not reverse these histopathological changes, when compared to CCl<sub>4</sub> control group (Figure 1C).

The daily excretion of ascorbic acid by different groups of rats before and after treatment is summarized in Figure 2. A dose of 0.7 ml/kg carbon tetrachloride produced significant reduction in ascorbic acid excretion. The group of rats treated with ethanolic extract of *R. arboreum* at a dose of 60 and 100 mg/kg prevented carbon tetrachloride induced reduction in ascorbic acid significantly ( $P < 0.01$ ). The standard reference drug Silymarin prevented CCl<sub>4</sub> induced reduction in ascorbic acid significantly.

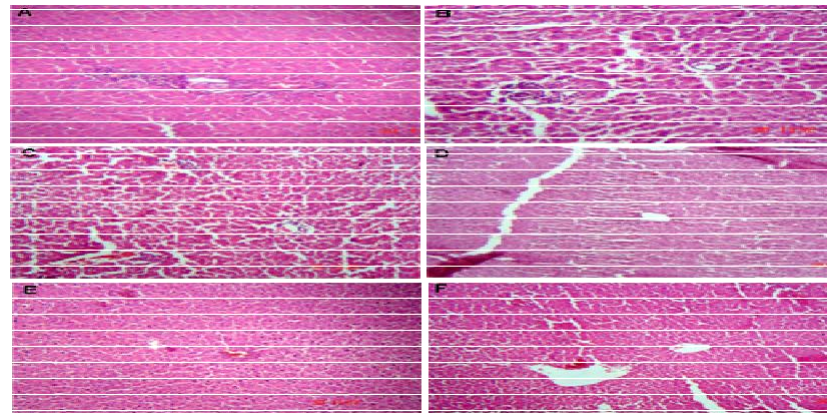
## DISCUSSION

The hepatotoxicity induced by CCl<sub>4</sub> is due to its metabolite CCl<sub>3</sub>·, a free radical that binds to lipoprotein and leads to peroxidation of lipids of endoplasmic reticulum (Recknagel, 1967). The ability of a hepatoprotective drug to reduce the injurious effects or to preserve the normal hepatic physiological mechanisms, which have been disturbed by a hepatotoxin, is the index of its protective effects. Although serum enzyme levels and ascorbic acid in urine are not a direct measure of hepatic injury, they show the status of the liver. The lowering of enzymes level are definite indication of hepatoprotective action of the drug. The present investigation also revealed that the given dose of CCl<sub>4</sub> (1ml/kg, sc) produced significant elevation in SGPT, SGOT, ALP, bilirubin (direct and total), triglyceride and cholesterol indicating all impaired liver

**Table 1.** Effects of ethanolic extract of leaves of *Rhododendro arboreum* on certain serum biochemical parameters in CCl<sub>4</sub> induced hepatotoxicity in rats

Groups	Biochemical Parameters						
	SGPT(IU/L)	SGOT(IU/L)	Bilirubin (mg/dl)		ALP(IU/L)	TGL(mg/dl)	Cholesterol (mg/dl)
			Total	Direct			
Normal group (5 ml/kg, po)	45.16±1.25	39.61± 0.60	0.1173± 0.0011	0.0274± 0.0013	108.01± 0.87	177.07± 0.77	196.28± 1.11
CCl <sub>4</sub> control (1 ml/kg, sc)	216.27±2.45**	214.07±2.69**	1.4334±0.0048**	0.3357±0.0022**	319.03± 2.89**	280.82± 1.30**	284.74± 2.96**
<i>R. arboreum</i> + CCl <sub>4</sub> (40 mg/kg, po)	207.36±0.81 <sup>ns</sup> (5.21%)	205.92±0.704 <sup>ns</sup> (4.67%)	1.3784± 0.0297 <sup>ns</sup> (4.17%)	0.3303± 0.0014 <sup>ns</sup> (1.75%)	313.31± 0.69 <sup>ns</sup> (2.71%)	276.84± 1.03 <sup>ns</sup> (3.84%)	273.47± 1.79 <sup>ns</sup> (12.74%)
<i>R. arboreum</i> + CCl <sub>4</sub> (60mg/kg, po)	98.27± 1.88** (68.96%)	71.82± 1.68** (81.54%)	0.5042±0.0267** (70.60%)	0.1481±0.0019** (60.85%)	277.04± 0.46** (19.90%)	244.27± 0.96** (35.23%)	214.39± 1.16** (79.52%)
<i>R. arboreum</i> + CCl <sub>4</sub> (100mg/kg,po)	46.58± 0.77** (99.17%)	43.05± 1.02** (98.03%)	0.1008±0.0177** (101.25%)	0.0290±0.0016** (99.45%)	119.35± 0.40** (94.63%)	216.82± 0.42** (61.69%)	203.66± 0.50** (91.66%)
Silymarin+ CCl <sub>4</sub> (100mg/kg,po)	46.10± 1.08** (99.45%)	41.12± 1.03** (99.13%)	0.1330±0.0182** (98.81%)	0.0315±0.0022** (98.67%)	110.45± 0.42** (98.84%)	180.83± 0.54** (96.37%)	198.79± 1.45** (97.16%)

Values are Mean ± SEM, (n = 6 in each group). Figures in parenthesis are percent protection as compared to CCl<sub>4</sub> control. CCl<sub>4</sub> control group was compared with normal group and all values were significantly different (P< 0.01). Experimental groups were compared with CCl<sub>4</sub> control: \*P<0.05 and \*\*P<0.01, ns = non significant



**Figure 1.** The photomicrographs (×200) of liver section taken from rats. (A) Group I, Liver cells of normal rats (5 ml/kg, po). (B) Group II, Liver cells of rats intoxicated with CCl<sub>4</sub> (1 ml/kg, ip). (C) Group III, Liver cells of rats treated with leaves of ethanolic extract of *R. arboreum* (40 mg/kg, po) + intoxicated with CCl<sub>4</sub>. (D) Group IV, Liver cells of rats treated with leaves of ethanolic extract of *R. arboreum* (60 mg/kg, po) + intoxicated with CCl<sub>4</sub>. (E) Group V, Liver cells of rats treated with leaves of ethanolic extract of *R. arboreum* (100 mg/kg, po) + intoxicated with CCl<sub>4</sub>. (F) Group VI, Liver cells of rats treated with Silymarin (100 mg/kg, po) + intoxicated with CCl<sub>4</sub>.

function and these parameters have been reported to sensitive indicator of liver injury (Molander et al., 1955; Zimmerman and Seeff, 1970). The massive production of reactive species may lead to depletion of protective physiological moieties (glutathione and tocopherols etc) and ensuing widespread propagation of the alkylation's as well as peroxidation, causing damage to the macromolecules in vital biomembranes. The present study reveals that the effect of pretreatment of ethanolic extract of leaves of *R. arboreum* had been effective in offering protection, which is comparable to Silymarin (Table 1).

CCl<sub>4</sub> treatment caused classical fatty liver as indicated by significant in tissue cholesterol. The tissue cholesterol levels reduced after natural recovery and Silymarin treatment. *R. arboreum* treatment caused significant reduction in tissue cholesterol and triglyceride in CCl<sub>4</sub> treated animals. The disturbance in the transport function of the hepatocytes as a result of hepatic injury causes the leakage of enzymes from cells due to altered permeability of membrane (Rechnagel, 1983). Hepatotoxic action of CCl<sub>4</sub> begins with changes in endoplasmic reticulum which result in loss of metabolic enzymes located in the intracellular structure (Conney and Burns, 1959).

The ethanolic extract of leaves of *R. arboreum* when administered orally to rats showed a significant dose dependent hepatoprotective activity at 60 and 100 mg/kg. The extract at 40 mg/kg does not alter the enzymes marker intoxicated group. A very important observation with this *R. arboreum* extract at dose of 100 mg/kg is highly effective in decreasing the elevated level of serum total bilirubin (101.25%) and direct bilirubin (99.45%).

The histopathological studies are the evidence of efficacy of drug as protectant. Simultaneous treatment of ethanolic extract with CCl<sub>4</sub> exhibits less damage to the hepatic cells as compared to the rats treated with CCl<sub>4</sub> alone. Intralobular veins though are damaged but to a lesser extent. Endothelium is disrupted at places. Hepatic cells adjoining to intralobular vein show atrophy. The sections of the liver treated with ethanolic extract of leaves of *R. arboreum* and CCl<sub>4</sub> reveals better hepatoprotective activity. Almost negligible damage to a few hepatocytes present in the close vicinity of intralobular vein is observed. Endothelium lining is almost smooth except one or two places. Hepatocytes show normal appearance only some cells show higher numbers of vacuoles in the cytoplasm. The results of histopathological study also support the results of biochemical parameters.

Ascorbic acid is formed as a metabolite of glucose and galactose in rat liver microsomes via the glucuronic acid pathway and is excreted in urine. The enzyme UDP glucose dehydrogenase and UDP glucuronide transferase are responsible for its formation in the liver microsomes. Its formation and excretion is altered by several drugs and substances that affect the drug metabolizing enzyme systems (Conney and Burns, 1959; Satyanarayana et al., 1988). Reduction in ascorbic acid excretion in CCl<sub>4</sub> treated rats may reflect the inhibition of such enzymes. Altera-

tion in urinary ascorbic acid excretion appears to be reflecting ascorbic acid level in liver. Hence, the reduction in urinary ascorbic acid excretion can be used as an index for CCl<sub>4</sub> produced hepatotoxicity (Hesse and Klinger, 1969). The ethanolic extract of *R. arboreum* it might antagonize CCl<sub>4</sub> produced inhibition of enzymes responsible for ascorbic acid formation similar to Silymarin (94.06%). The results in the present study indicate that reduction in urinary ascorbic acid excretion by *R. arboreum* extract as an index for hepatoprotective activity against CCl<sub>4</sub> induced hepatotoxicity. The leaves of *R. arboreum* extract (60 and 100 mg/kg) increased ascorbic acid excretion by 86.15 and 93.08% respectively.

Further, in the present investigation, preliminary phytochemical analysis of leaf extract revealed the presence of flavonoids, phytosterol, saponins, tannins and phenolic compounds and carbohydrates. flavanoids (Yoshikawa et al., 2003) and saponins (Baek et al., 1996) are well known for their antioxidant and hepatoprotective activities. The literature has already documented the flavanoids are isolated from the leaves of Himalayan rhododendrons were found to have potent antioxidant property. Since Quercetin 3-O- beta -D-glucopyranosyl [1->6]-O-alpha-L-rhamnopyranoside, pectolinarigenin 7-O-rutinoside, 7,2'-dimethoxy-4',5-methylenedioxyflavanone and related flavonoids are present in *R. arboretum* (Kamil et al., 1995). The mechanism by which quercetin, a natural antioxidant, inhibit lipid peroxidation by blocking the enzyme xanthine oxidase (Cheng and Breen, 2000), Chelating iron (Da Silva et al., 1998) and directly scavenging hydroxyl, peroxy and superoxide radicals (De Whalley et al., 1990) reveals its antioxidant properties. Quercetin also protects antioxidative defense mechanism by increasing the absorption of Vitamin C (Vinson and Bose, 1998). Quercetin has been shown to inhibit structural damage to proteins (Salvi et al., 2001), the release and the protection of oxidative products generated by the respiratory burst in phagocytes (Zielinska et al., 2000). Quercetin has recently shown to be an INOS inhibitor, resulting in reduced nitric oxide (NO) and peronitrate generation (Autore et al., 2001).

It is concluded that treatment with ethanolic extract decreases the CCl<sub>4</sub>-induced elevation in biochemical parameters. These findings suggest that the ethanolic extract was effective in bringing about functional improvement of hepatocytes. The healing effect of this extract was also confirmed by histological observations. The study demonstrates that, leaves of *R. arboreum* contain flavanoids and phenolic compounds may have a potential therapeutic approach to hepatoprotective properties.

## ACKNOWLEDGEMENT

The authors would like to express their gratitude to Premnath Reddy, Chairman and Shalini Reddy, Director, Acharya Institute, Bangalore for providing necessary specialties and support.

## REFERENCES

- Autore G, Rastrelli L, Lauro MR, Marzocco S, Sorrentino R, Sorrentino U (2001). Inhibition of nitric oxide synthase expression by methanolic extract of *Crescentia alata* and its derived flavonols, *Life Sci.* 70: 523-534.
- Baek NL, Kim YS, Kyung JS, Park KH (1996). Isolation of Anti-hepatotoxic agent from the roots of *Astragalus membranaceus*, *Korean J Phamacog.* 27: 111-117.
- Cheng LE, Breen K (2000). On the ability of four flavonoids, baicilein, luteolin, naringenin and quercetin to suppress the fenton reaction of the iron-ATP complex, *Boimetal.* 13: 77-83.
- Conney AH, Burns JJ (1959). The stimulatory effects of foreign compounds on ascorbic acid biosynthesis and on drug metabolising enzymes, *Nature.* 184: 363-364.
- Da Silva EJ, Diskala MK, Yamamoto N, Moon JH, Tero J (1998). Quercetin metabolites inhibit copper ion induced lipid peroxidation in rat plasma, *FEBS Lett* 430: 405-409.
- De Whalley CY, Rankin JF, Rankin SM (1990). Flavonoids inhibit the oxidative modification of low density lipoproteins. *Biochem Pharmacol.* 39: 1743-1749.
- Deeg R, Ziegenhorn J (1983). Kinetic enzymatic method for automated determination of total cholesterol in serum, *Clin Chem.* 29: 1798-1802.
- Demetrius JA, Drewes PA, Gin JB (1974). Enzymes, *Clinical Chemistry Principles and Techniques* (Harper and Row, New York), pp 927.
- Dhan P, Garima U, Singh BN, Ruchi D, Sandeep K, Singh KK (2007). Free radical scavenging activities of Himalayan rhododendrons, *Curr Sci.* 92: 526-532.
- Fossati P, Principe L (1982). Serum triglycerides determined colorimetrically with an enzyme that produces hydrogen peroxide, *Clin Chem* 28: 2077-2080.
- Gambino SR (1965). *Standard method of Clinical Chemistry*, (Academic Press, New York) p. 55.
- Henry RJ, Cannon DC, Winkelman JW (1974). *Clinical Chemistry Principles and Techniques*, (Harper and Row, New York) pp 822.
- Hesse V, Klinger W (1969). Early effect of CCl<sub>4</sub> on the ascorbic acid concentration in the liver and ascorbic acid excretion in the urine of the rats, *Arch Toxicol.* 25: 306-317.
- Kamil M, Shafiullah Ilyas M (1995). Flavonoidic constituents of *Rhododendron arboreum* leaves, *Fitoterapia.* 66: 371-372.
- Khandelwal KR (2000). *Practical Pharmacognosy techniques and experiments*, (Nirali Prakashan, Pune), p. 149.
- Molander DW, Wroblewski F, La Due JS (1955). Transaminase compared with cholinesterase and alkaline phosphatase an index of hepatocellular integrity. *Clinical Research Proceedings.* 3: 20-24.
- Recknagel R (1967). Carbontetrachloride hepatotoxicity. *Pharmacol Rev.* 19,145-196.
- Recknagel RO (1983). Carbontetrachloride hepatotoxicity status quo and future prospects, *Trends Pharmacol Sci.* 4: 129-130
- Roe JH, Kuether KA (1943). The determination of Ascorbic acid in whole blood and urine through 2, 4 - di-nitrophenylhydrazine derivatives of dehydroascorbic acid, *J Biol chem.* 147: 399-408.
- Salvi A, Carrapt P, Tillement J, Testa B. (2001). Structural damage to protein and influence of protein binding, *Biochem Pharmacol.* 61: 1237-1245.
- Satyanarayana S, Suneeta T and Visweswara D (1988). Comparative study of Imidazole and SKF-525A on the urinary excretion of ascorbic acid in rats, *Ind J Pharm Sci.* 50: 52-54.
- Shyam SA, Kalpana S (1988). Anti-inflammatory activity of flowers of *Rhododendron arboreum* (SMITH) in rat's hind paw edema induced by various phlogistic agents, *Indian J Pharmacol.* 20: 86-89.
- Vinson JA and Bose P (1998). Comparative bioavailability to humans of ascorbic acid alone or in a citrus extract, *Am J Clin Nutr.* 48: 601-604.
- Walter K, Schutt C (1974). Acid and alkaline phosphatases in serum. In: Verlag Chemie Weinheim, In: Hans Ulrich Bergmeyer (Ed.), *Methods of Enzymatic Analysis*, vol. 2. Academic Press Inc., New York, pp. 856- 864.
- Yoshikawa M, Morikawa T, Kashima Y, Ninomiya K, Matsuda H (2003). Structure of new dammarane- type triterpene Saponins from the flower buds of *Panax notoginseng* and hepatoprotective effect of principal ginseng Saponins, *J Nat Product.* 66: 922-927.
- Zielinska M, Kostrzewa A, Lcgnatowicz E (2000). Antioxidative activity of flavonoids in stimulated human neutrophils, *Folia Histochem Cytobiol.* 38: 25-30.
- Zimmerman HJ, Seeff LB (1970) *Enzymes in hepatic disease*, Diagnostic Enzymology (Lea and Febiger, Philadelphia). pp1