

Full Length Research Paper

Investigations on the phytochemical activities and wound healing properties of *Adhatoda vasica* leave in Swiss albino mice

Subhashini S.¹ and Kantha D. Arunachalam^{2*}

¹Department of Biotechnology, School of Bioengineering, SRM University, Kattankulathur, Chennai, Tamil Nadu, India.

²Centre for Inter Disciplinary Research, SRM University, Kattankulathur, Chennai, Tamil Nadu, India.

Accepted 16 April, 2020

Adhatoda vasica has been used in many ayurvedic formulations. In order to evaluate the wound healing activity of *A. vasica*, five different solvent extracts were prepared from the leaves of the plant. Methanol, ethanol, ethyl acetate, chloroform and hexane were used for the extraction of the active ingredients. Excision wound model on Swiss albino mice was used to assess the wound healing activity of the leaves. Remarkable wound healing activity was observed with the ointment formulation of the methanol extract at 1% concentration. Wound contraction was calculated as percentage of the reduction in wound area. A specimen sample of tissue was isolated from the healed skin of each group of mice for the histopathological examination. The results of histopathological examination also supported the outcome of excision wound models. Hematoxylin and Eosin stained sections and Van Gieson's stained sections were checked for collagen deposition. Toluidine blue stained sections were checked for metachromatic staining of mast cells. The present study demonstrated that the aerial parts of *A. vasica* promote wound healing activity in mice as a preclinical study.

Key words: *Adhatoda vasica*, phytochemical analysis, excision wound model, wound healing activity, histopathological examination.

INTRODUCTION

The concept of developing herbal drugs from medicinal plants used in indigenous medicine is followed from time immemorial. In some cases direct link between a local person and a medical practitioner exists. In other cases the relationship is much more diverse and complex (Heinrich and Gibbons, 2001). Wounds and especially chronic wounds are major concerns for the patient as well as the clinician. Chronic wounds affect a large number of patients and seriously reduce their normal life and life span. Worldwide the herbal industry is picking up at a fast pace. Herbs and botanicals now appear in more products and have more medicinal applications than ever before. India is blessed with diverse agro-climatic conditions and is a major source for a wide variety of medicinal plants.

But the production potential is largely underexploited.

In the recent years, there is a tremendous research interest in the possible role of phytochemical in the prevention and treatment of many diseases. In this context, antioxidants especially those that are derived from natural sources such as Indian medicinal plants and herbal drugs derived from plants require special attention. Antioxidants derived from such sources play an important role in neutralizing the toxic free radicals that are produced in the body. Antioxidants have many important medicinal applications, in relation to human health, both in terms of prevention and treatment of diseases (Sies, 1996; Halliwell and Gutteridge, 1997).

Pharmaceuticals, nutraceuticals, food and cosmetic industries are the major buyers of herbal products. Herbal products are in demand in the form of standardized plant extracts or botanical ingredients or semi finished products. The modern allopathic system of medicine has made great strides and contribution to the understanding

*Corresponding author. E-mail: kanthadarunachalam@gmail.com.

of human physiology and cellular metabolic pathways and brought out methodologies for handling acute diseases and infections. However, worldwide, we face the problem of incurable chronic diseases and ageing associated ailments.

When we look back over 250 years ago, people of many continents for the most part resorted to herbal and traditional medicine. Likewise in India too, Ayurveda systems offered botanical medicines and took care of the health of our nation. Almost 25 to 40% of the active components of the synthetic medicine of allopathic medicine had origins from higher flowering plants of the world and the clues to discover them came from folklore medicines of various cultures.

Although the allopathic medicines are extremely effective in handling short term and emergency health conditions, it has been largely ineffective in treating some of the multifactorial chronic diseases. The relative strength of modern system of medicine over the traditional system is in its vast pharmacopoeia, technological advancement in surgical tools or procedures and in handling of acute diseases. Despite the fact that many new medicines are being added in allopathy, only about 30% of the known 2000 diseases are cured, and other 50% are being treated only symptomatically. Approximately, 20% of the allopathic medicines have considerable side effects.

The medicinal value of the medicinal plants lies in the bioactive phytochemical compounds that produce normal physiological action on the human body (Akinmoladun et al., 2007). Some of the most valuable bioactive phytochemical constituents are alkaloids, essential oils, flavonoids, tannins, terpenoids, saponins, phenolic compounds and many more compounds (Edeoga et al., 2005). These natural bioactive compounds formed the foundations of the modern prescription drugs as we know today (Goh et al., 1995).

Adhatoda vasica

Adhatoda vasica is a species of plant in the *Acanthaceae* family. It is a shrub growing throughout India especially in the lower Himalayan regions. The plant has potent antiperiodic, astringent, diuretic and purgative action. It is a highly valued Indian medicinal plant which is used in the treatment of respiratory diseases like asthma, cough, bronchitis and tuberculosis (Jain, 1991; Nadakarni, 1976). The flowers, leaves and root have antispasmodic property. The activities against tuberculosis were reported by many researchers quite early (Barry et al., 1955; Gupta and Chopra, 1954). It has been used extensively as an important herbal drug in treating a wide variety of diseases and the leaves of the plant are the main source of drug formulation. For instance, the source of the drug 'vasaka' is well known in the indigenous system of medicine for its beneficial health effects, particularly in treating bronchitis (Kumar et al., 2005).

Traditionally, *A. vasica* has been used for the treatment of respiratory disorders namely acute and chronic cough, bronchitis and asthma. It is also used as an expectorant in the treatment of acute and chronic bronchial catarrh and pulmonary diseases. The leaves, as well as, the flowers, fruits and roots are extensively used for the treatment of cold, whooping cough, asthma and as antihelminthic and the leaf extract is known to cure diarrhea, dysentery and glandular tumor. The different parts of the plant is used in the Indian traditional medicine for the treatment of various diseases like asthma, joint pain, lumber pain and sprains, cough, eczema, malaria, rheumatism, swellings, venereal diseases (Kirtikar and Basu, 1935; Chopra et al., 1956, Rastogi et al., 1994). In homeopathy, *A. vasica* has been used in the treatment of cold, cough, pneumonia, spitting of blood, fever, jaundice, catarrh, whooping cough and asthma (Asolkar et al., 1992).

MATERIALS AND METHODS

Plant material

The plant material, *A. vasica* was collected from Chennai, Tamil Nadu. The leaves of the plant were shade dried and powdered.

Preparation of extract

The aerial part of the plant that was powdered was used for the extraction process. 5 g of the powdered sample was submitted to successive solvent extraction separately with 100 ml each of methanol, ethanol, ethyl acetate, chloroform and hexane at room temperature for 24 h. This was repeated three times and 300 ml of the solvent extract was collected for each of the solvent. The solvent extract thus obtained was evaporated at 40°C to dryness in a rotary evaporator in vacuum (Ipek et al., 2009).

Percentage yield

The percentage yield was calculated from the product that was obtained after evaporation.

Percentage yield = $\frac{\text{Weight of the product obtained after evaporation}}{\text{Weight of the powdered sample taken initially}} \times 100$

Preliminary phytochemical investigation

Test for saponins

300 mg of extract was boiled with 5 ml of water for two minutes. The mixture was cooled and mixed vigorously and left for three minutes. The formation of frothing indicates the presence of saponins.

Test for tannins

An aliquot of the extract was added to sodium chloride to make 2% strength. It was filtered and mixed with 1% gelatine solution. Precipitation indicates the presence of tannins.

Test for triterpenes

300 mg of extract was mixed with 5 ml of chloroform and warmed for 30 min. The chloroform solution is then treated with a small volume of concentrated sulphuric acid and mixed properly. The appearance of red colour indicates the presence of triterpenes.

Test for alkaloids

300 mg of extract was digested with 2 M hydrochloric acid. This acidic filtrate was mixed with amyl alcohol at room temperature and the alcoholic layer was examined for the appearance of pink colour which indicates the presence of alkaloids.

Test for flavonoids

The presence of flavonoids was determined using 1% aluminium chloride solution in methanol, concentrated hydrochloric acid, magnesium chloride and potassium hydroxide solution.

Chromatographic analysis

The five different solvent extracts obtained was analysed using HPTLC to find out which solvent extract contains the maximum active ingredients. The solvent having maximum number of peaks is the one with maximum active ingredients.

Gel formulation

50 g of the powdered sample was submitted to successive solvent extraction with 1000 ml methanol at room temperature for 24 h. This was repeated three times and 3000 ml of the solvent extract was collected. The methanol extract thus obtained was evaporated at 40°C to dryness in a rotary evaporator in vacuum. The product thus obtained was used for gel formulation. 1 g of the dried solvent extract was made up to 100g using Vaseline and a paste was made.

Animals

The animal experiments conducted during the present study were approved by the Institutional Animal Ethical Committee (IAEC), SRM University (Ethics Clearance Number: 07/IAEC/09). Male albino Swiss mice weighing 25 to 30 g were used in the wound healing model experiments. The study was performed according to the international rules considering the animal experiments and biodiversity right. The animals were left for 15 days for acclimatization. They were maintained on standard pellet diet and water throughout the experiment. The mice were divided into three groups of six animals each (n = 6). Six animals were used for the treatment group, six for the positive control group and six for the negative control group. 1% (w/w) *Adhatoda vasica* ointment was applied on the treatment group. 5% (w/w) povidine iodine ointment was applied on the positive control group (Kalyon et al., 2009). Plain Vaseline was applied on the negative control group.

Excision wound model

Excision wound models were used to evaluate the wound healing activity. Excision wound model was employed to have information about wound contraction and wound closure time on the three groups of animals. The back hairs of the animals were depilated by

shaving. A wound was created on the dorsal interscapular region of each animal by excising a predetermined area of 7 x 7 mm skin under ether anaesthesia (Suguna et al., 1996). Wounds were left open and the medicine was applied topically twice a day (once in the morning and once in the evening) on to each mouse till the wound was completely healed (Tramontina et al., 2002).

Measurement of wound area

The progressive changes in wound area were monitored by a camera every fourth day. The size of the wound was also measured using a scale daily and the wound area was calculated. Wound contraction was calculated as percentage of the reduction in wound area (Werner et al., 1994).

Percentage of wound contraction = [(Initial wound area – Specific day wound area) / Initial wound area] x 100

Histopathological examination

A specimen sample of the tissue was isolated from the healed skin of each group of mice for the histopathological examination (Sadaf et al., 2006). The cross sectional full thickness skin specimens from each group were collected at the end of the experiment to evaluate the histopathological alterations. Samples were fixed in 10% buffered formalin, processed and blocked with paraffin and then sectioned into 5 µm thick sections. The sections were stained with Hematoxylin and Eosin stain (HE), Van Gieson's stain (VG) and Toluidine blue stain (TB). Hematoxylin and Eosin stained sections and Van Gieson's stained sections were checked for collagen deposition. Toluidine blue stained sections were checked for metachromatic staining of mast cells (Jagetia and Rajanikant, 2005).

Statistical analysis of the data

The data on the percentage of wound contraction was statistically analysed using one-way analysis of variance (ANOVA) followed by Dunnett's test. The values of P 0.001 were considered to be statistically significant. The data on histopathological examination were considered to be non-parametric and so no statistical tests were performed.

RESULTS

Percentage yield

The percentage yield of various extracts of *A. vasica* was calculated (Table 1). From the percentage yield it was observed that the methanol extract gave the maximum amount of yield and the hexane extract gave the minimum amount of yield.

Preliminary phytochemical analysis

Methanol extract was evaluated for presence of various phytochemical constituents by performing different qualitative chemical tests that are reported. It showed the presence of anthraquinone, glycosides, saponins, tannins and phytosterols (Khandelwal, 2005) (Table 2). From the phytochemical analysis it was observed that *A. vasica*

Table 1. Percentage yield of various extracts of *A. vasica*.

S/No.	Extracts	Nature of extracts	Colour	Yield(% w/w)
1	Methanol	Semisolid	Dark green	23.4
2	Ethanol	Semisolid	Dark green	21.3
3	Ethyl acetate	Semisolid	Dark green	16.6
4	Chloroform	Semisolid	Dark green	8.9
5	Hexane	Semisolid	Dark green	8.1

Table 2. Phytochemical analysis of methanol extract of *A. vasica*.

Phytochemical	Confirmation
Carbohydrate	+
Terrapins	+
Triterpenoids	+
Flavonoids	+
Saponins	-
Tannins	-
Amino acids	+
Glycosides	+
Alkaloids	+
Steroids	+

Key: + Present, - Absent.

preliminarily contains amino acids, carbohydrates, alkaloids, lipids and glycosides. Histopathological observation suggested that the phytochemical content of the methanol extract might be responsible for the collagen formation at the proliferative state which is contributed by increased fibroblasts content.

HPTLC analysis

The HPTLC results are shown in Figures 1 to 5. From the HPTLC analysis it was observed that the methanol extract contains the maximum amount of phytochemical compounds and the hexane extract contain the minimum amount of phytochemical compounds. Therefore, the methanol extract of *A. vasica* was used in the treatment of wounds on Swiss albino mice by using excision wound models to verify the claimed traditional use of the plant on a scientific procedure. More over, histopathological examination of the animal tissues treated with the extract was also assessed. The specimen slides observed for the treatment group, positive control group and negative control group were analysed.

Measurement of wound area

The wound area was measured and calculated on a daily

basis (Figure 6). The percentage of wound contraction was monitored everyday from the 0th day till the 12th day (Figure 7). On the 12th day all the six mice under positive control were healed, whereas, in the mice under negative control, the healing is delayed. The healing is intermediate in the case of mice under treatment group (Figure 8). The Histopathological examination of the healed tissues is given in Figure 9.

DISCUSSION

Wound healing is a complex and dynamic process of restoring cellular structures and tissue layers in damaged tissue as closely as possible to its normal and original state (Clark, 1985) . Wound contraction is a process that occurs throughout the healing process, commencing in the fibroblastic stage where the area of the wound undergoes shrinkage (Chitra et al., 2009). Wound healing can be discussed in three phases (Figure 10). They are:

1. Inflammatory phase
2. Proliferative phase
3. Maturation or remodelling phase

It is dependent upon the type and extent of damage occurred, the general health of the host and the ability of the tissue to undergo repair.

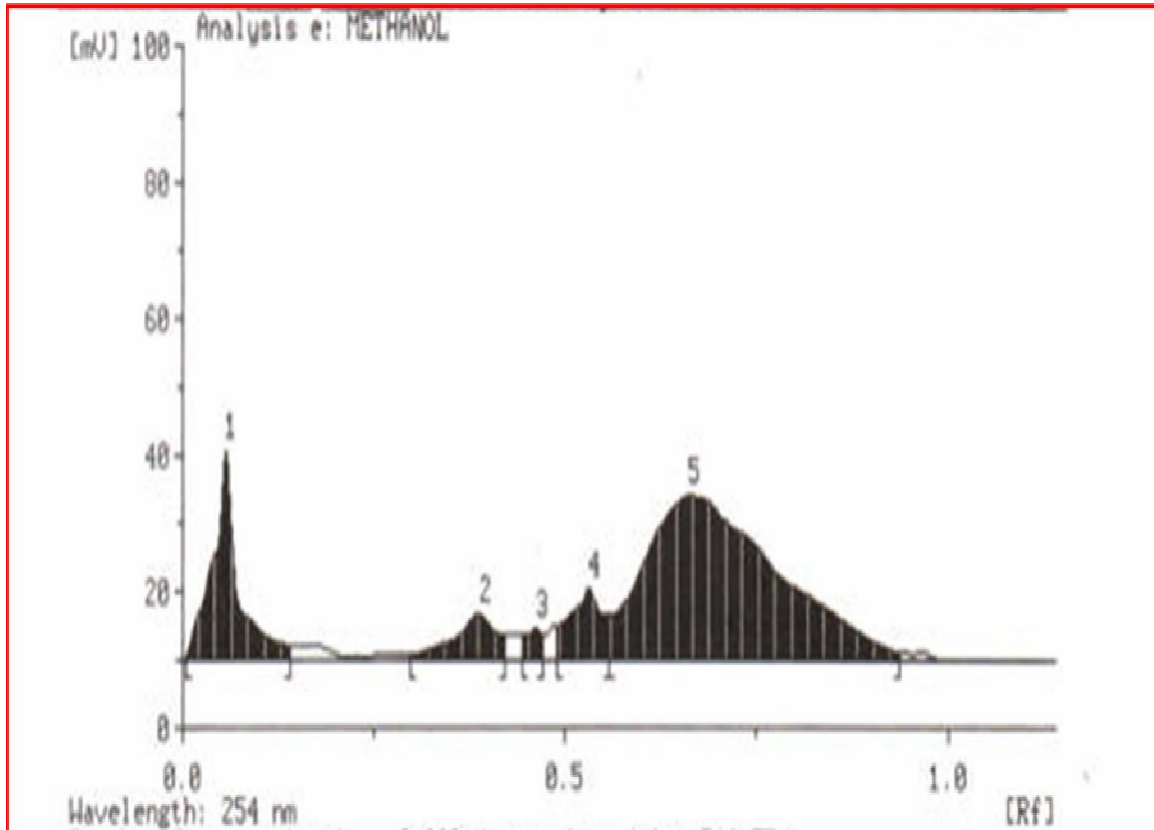


Figure 1. HPTLC chromatogram of the methanol extract of *A. vasica*.

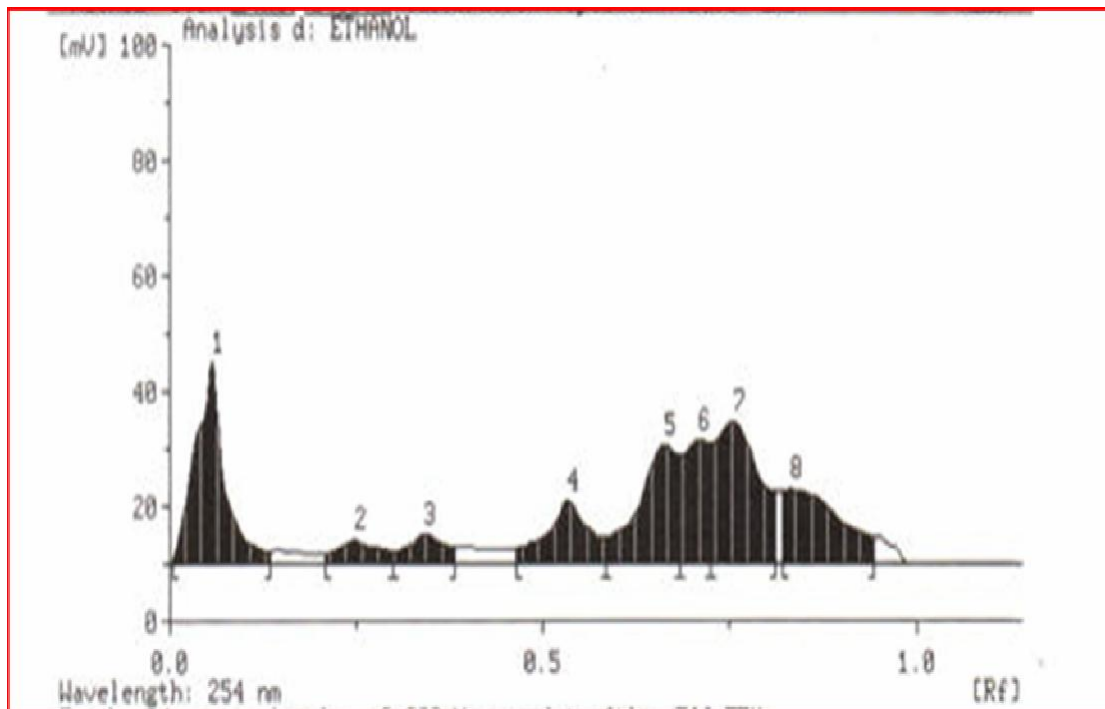


Figure 2. HPTLC chromatogram of the ethanol extract of *A. vasica*.

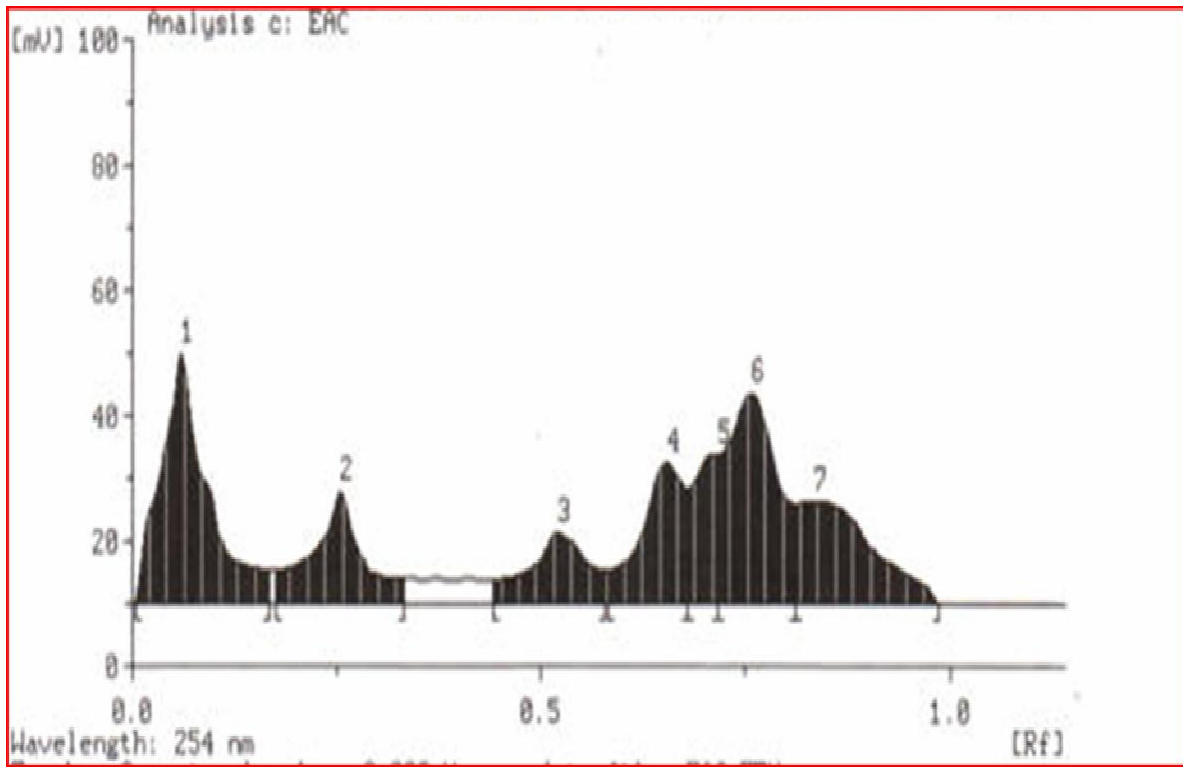


Figure 3. HPTLC chromatogram of the ethyl acetate extract of *A. vasica*.

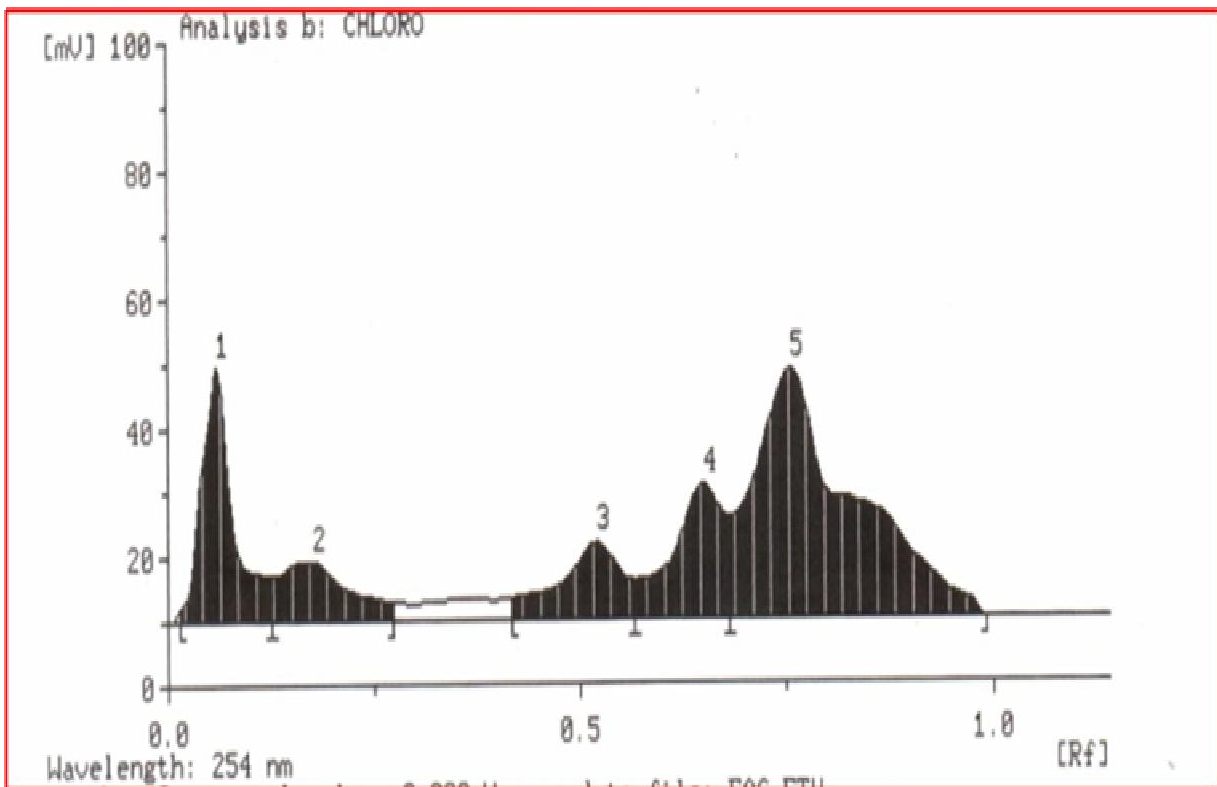


Figure 4. HPTLC chromatogram of the chloroform extract of *A. vasica*.

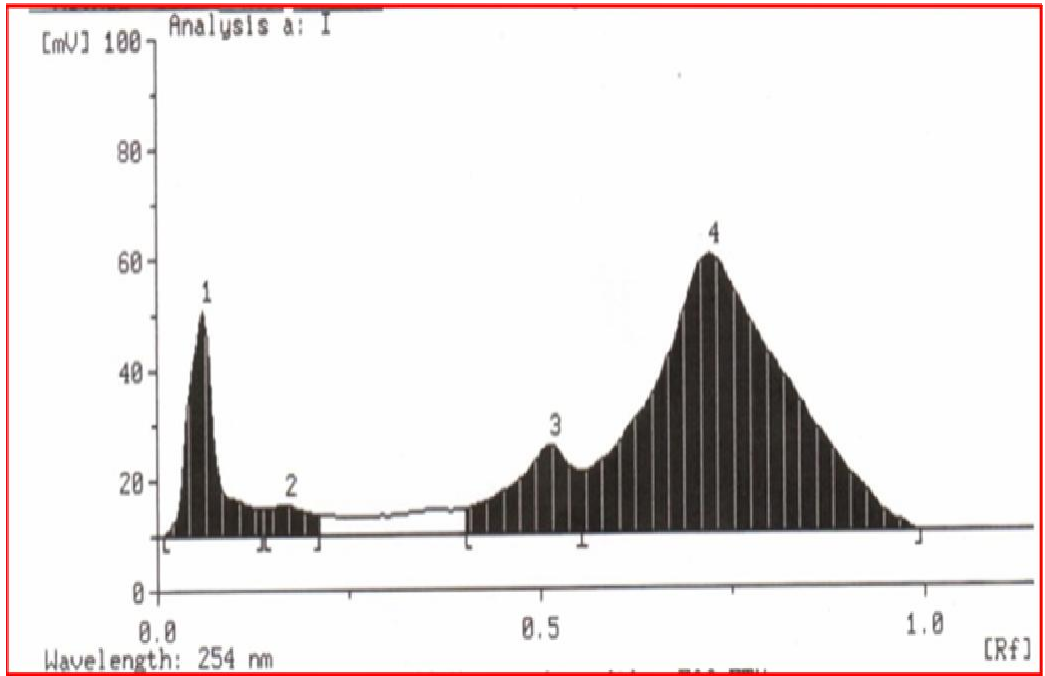


Figure 5. HPTLC chromatogram of the hexane extract of *A. vasica*.

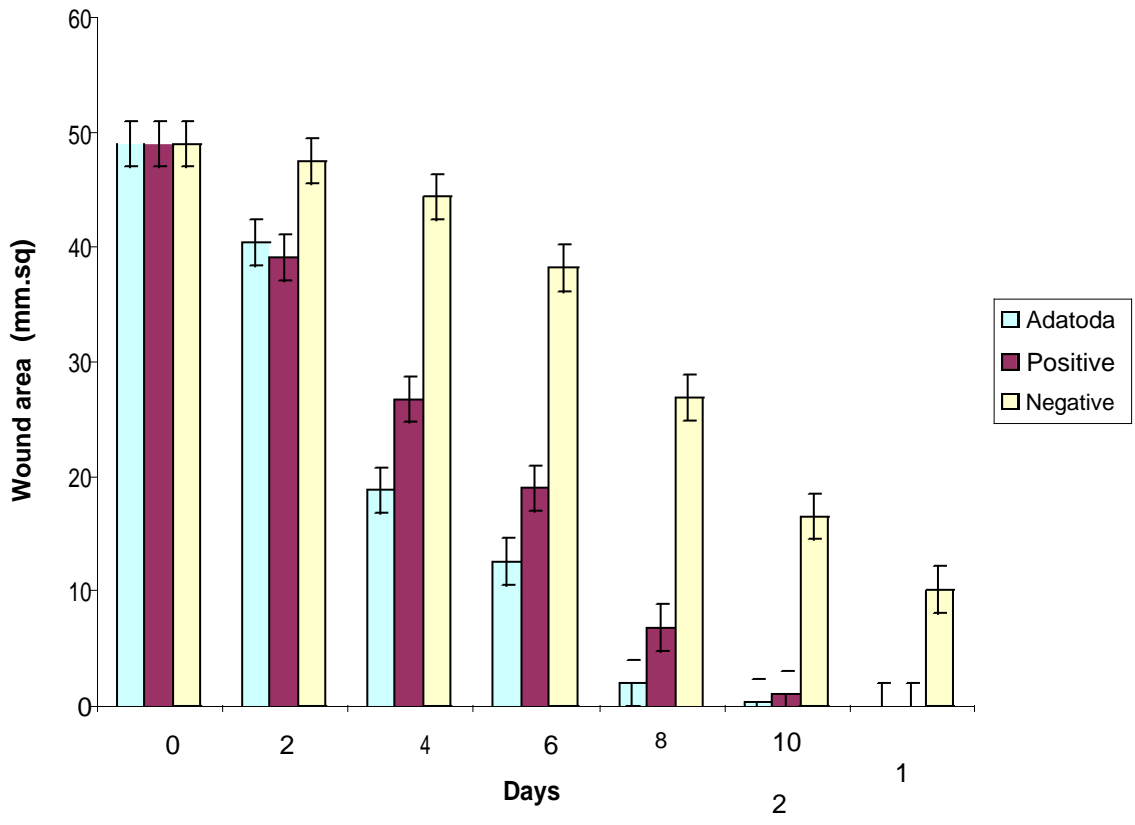


Figure 6. Reduction in wound area. Reduction in wound area: The figure shows reduction in wound area for mice in treatment group compared to mice in positive control group and mice in negative control group. This graph has been calculated for a period of 12 days. The x - axis denotes the number of days and the y - axis denotes the wound area in sq.mm.

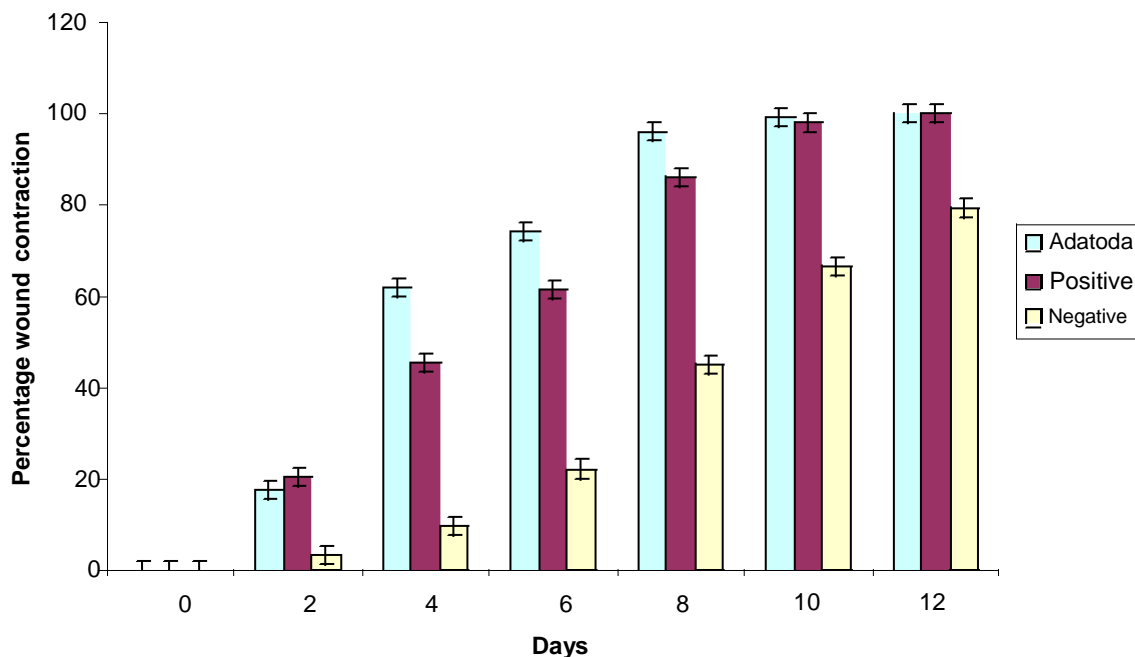


Figure 7. Percentage of wound contraction. Percentage of wound contraction: The figure shows percentage of wound contraction for mice in treatment group compared to mice in positive control group and mice in negative control group. This graph has been calculated for a period of 12 days. The x - axis denotes the number of days and the y - axis denotes the percentage of wound contraction.

Inflammatory phase

The inflammatory phase is characterized by haemostasis and inflammation.

Proliferative phase

Inflammatory phase is followed by epithelialization, angiogenesis and collagen deposition.

Remodelling phase

In the maturation phase which is the final phase of wound healing, the wound undergoes contraction resulting in a smaller amount of apparent scar tissue (Phillips et al., 1991).

Granulation tissue which is formed in the final part of the proliferative phase is primarily made up of fibroblasts, collagen, oedema and new small blood vessels. The increase in dry granulation tissue weight in the test treated animals suggests higher protein content (Devipriya and Shyamladevi, 1999). The methanol extract of *A. vasica* demonstrated a significant increase in the hydroxyproline content of the granulation tissue indicating increased collagen turnover. Collagen, which is the major

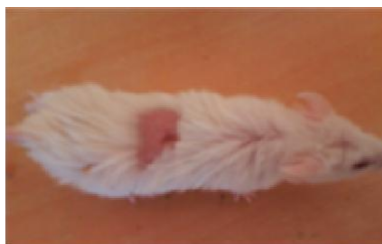component that strengthens and supports extra cellular tissue, is composed of the amino acid, hydroxyproline, which has been used as a biochemical marker for tissue collagen (Kumar et al., 2006).

The preliminary phytochemical investigation of the leaf extract showed the presence of tannins, triterpenes and alkaloids. Any one of the observed phytochemical constituents present in *A. vasica* may be responsible for the wound healing activity. Studies have shown that phytochemical constituents like flavonoids (Tsuchiya et al., 1996) and triterpenoids (Scortichini and Pia, 1991) are known to promote the wound healing process mainly due to their astringent and antimicrobial properties which appear to be responsible for the wound healing and increased rate of epithelialisation (Tsuchiya et al., 1996).

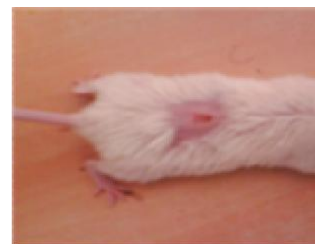The wound healing property of *A. vasica* may be attributed to the phytochemical constituents present in the plant (Leite et al., 2002). Flavonoids have many therapeutic uses due to their anti-inflammatory, anti-fungal, antioxidant and wound healing properties (Nayak et al., 2009; Zuanazzi et al., 2004; Santos et al., 2004; Okuda, 2005). The quicker process of wound healing could be a function of either the individual or the additive effects of the phytochemical constituents. The early tissue approximation and increased tensile strength of the wound observed in the present study may have been contributed by the tannin content of *A. vasica*. Tannins are the main components of many plant extracts and they



Mice on 0th day: Treatment group



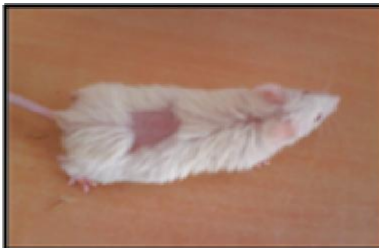Positive control group



Negative control group



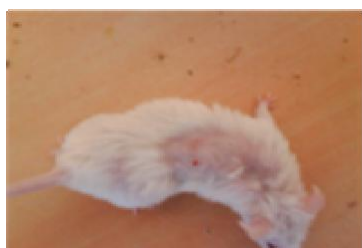Mice on 4th day: Treatment group



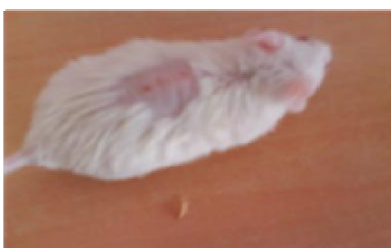Positive control group



Negative control group



Mice on 8th day: Treatment group



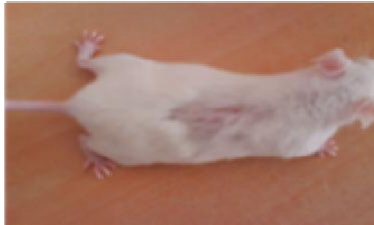Positive control group



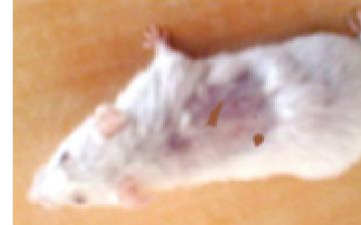Negative control group



Mice on 12th day: Treatment group



Positive control group



Negative control group

Figure 8. Photographs of mice taken on Day 0, 4, 8 and 12. The figure shows contraction of wound area on mice in treatment group compared to mice in positive control group and mice in negative control group.

act as free radical scavengers (Bekerecioglu et al., 1998; Marja et al., 1999; Raquel et al., 2000; Andrea et al., 1998; Tran et al., 1996; Dutta and Shastry, 1959). Wound healing activity of the plant may also be subsequent to

an associated antimicrobial effect.

Ample numbers of secondary metabolites or active compounds isolated from plants have been demonstrated in animal models as active principles responsible for

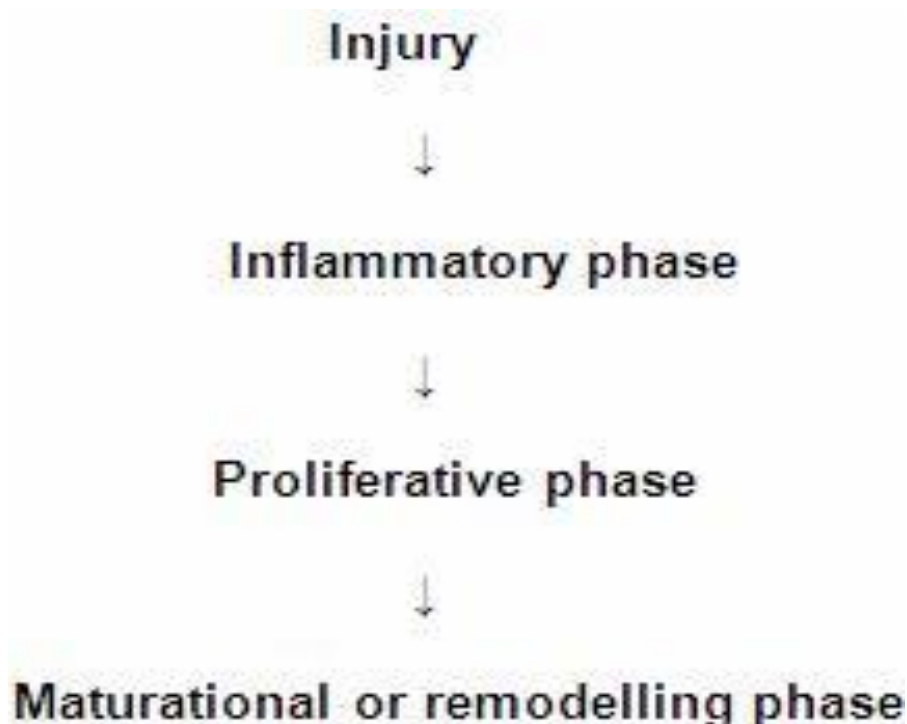


Figure 10. Hypothetical flowchart of the wound healing mechanism.

the wound healing process of the wounded tissue in *A. vasica* leaf extract treated mice was comparably close to the reference drug treated mice. No healing was observed in negative control group. Granulation tissue primarily contains fibroblasts, collagen fibers, very less oedema and newly generated blood vessels which were also observed in leaf extract treated mice. The histopathological examination provided additional evidence for the experimental wound healing studies which was based on the contraction value of wound area and the measurement of tensile strength. In the present study, the methanolic extract of the aerial parts of *A. vasica* was found to be remarkably active on excision wound models. Corresponding types of wound- healing effect were reported on many such medicinal plants (Manjunatha et al., 2005; Nayak et al., 2005).

When a wound occurs and is exposed to external environment, it is more prone to attack by microbes which gain entry through the skin and delay the natural wound healing process (Patil and Sunil, 2008). VEGF action is associated with many physiological and pathological neovascular events, such as embryonic development, tumor growth, and wound repair in particular (Ferrara, 1999). During the inflammation phase of healing, neutrophils and macrophages are attracted into the injured tissue by various chemo tactic factors (Hernandez et al., 2001). They locate, identify, phagocytize, kill and digest the microbes and thus eliminate wound debris through their characteristic 'respiratory burst' activity and phagocytosis. At higher concentrations, ROS can induce

severe tissue damage and even lead to neoplastic transformations which further impede the healing process by causing damage to cellular membranes, DNA, proteins and lipids as well (Loft and Poulsen, 1996; Pryor, 1997). Therefore, if a compound or a plant extract possess antioxidant potentials and antimicrobial activity additionally, it can be a good therapeutic agent for accelerating the wound healing process.

The activity most probably comes from the synergistic effect of compounds present in the extract and also additive effect of hiperisin. According to ethno pharmacological studies, botanical remedies provide two advantages over single compound drugs. Primary active compounds in plants are synergized by secondary compounds and secondary compounds ease the side effects caused by primary active compounds. The course of searching an ethno pharmacologically active plant extract down to a single active principal ingredient may result in loss of biological activity for a number of reasons. For instance, a special compound may be unstable during the extraction or fractionation or in the purified form. The fundamental basis of ethno pharmacology does not always exist in a single active compound but rather is a result of the interaction of more than one active compound found in the extract. Sometimes, the single compound potentiates the activity and it may become toxic compared to the whole plant extract. Thus, the likelihood that more than one compound present in the plant extract could contribute to a net pharmacological response of the plant extract.

Conclusion

In conclusion, the present study demonstrated that the aerial parts of *Adhatoda vasica* promote wound healing activity in mice as a preclinical study. The methanolic extract of the leaf showed remarkable wound healing activity and it may be suggested for treating various types of wounds and injuries in animals. The enhanced wound healing activity of *Adhatoda vasica* could possibly be made use of clinically in healing of open wounds. However, confirmation of this study has to be done through well designed clinical evaluation.

ACKNOWLEDGEMENTS

This work was supported by SRM University. The authors are thankful to Department of Biotechnology, School of Bioengineering, SRM University for providing the necessary infra structure to carry out the work successfully. The animal experiments conducted during the study were approved by the Institutional Animal Ethical Committee (IAEC), SRM University (Ethics Clearance Number: 07/IAEC/09).

REFERENCES

- Akinmoladun AC, Ibukun EO, Afor E, Obuotor EM, Farombi EO (2007). Phytochemical constituent and antioxidant activity of extract from the leaves of *Ocimum gratissimum*. Sci. Res. Essay, 2: 163-166.
- Andrea G, Mirella N, Alessandro B, Cristina S (1998). Antioxidant Activity of Different Phenolic Fractions Separated from an Italian Red Wine. J. Agric. Food Chem., 46: 2.
- Barry VC, Conalty ML, Rylance HJR (1955). Antitubercular effect of an extract of *Adhatoda vasica*. Nature, 176: 19-120.
- Bekerecioglu M, Tercan M, Ozyazan I (1998). The effect of *Ginkgo biloba* (Egb 761) as a free radical scavenger on the survival of skin flaps in rats. Sci. J. Plast Reconstr. Hand Surg., 32: 135-139.
- Chaudhari M, Mengi S (2006). Evaluation of phytoconstituents of *Terminalia arjuna* for wound healing activity in Rats. Phytother. Res., 20: 799-805.
- Chitra S, Patil MB, Ravi K (2009). Wound healing activity of *Hyptis suaveolens* (L) Poit (Lamiaceae). Int. J. Pharm. Technol. Res., 1: 737-744.
- Clark RAF (1985). Cutaneous tissue repair. I. Basic biologic consideration. J. Am. Acad. Dermatol., 13: 701-725.
- Devipriya S, Shyamaladevi CS (1999). Protective effect of quercetin in cisplatin induced cell injury in the kidney. Indian J. Pharmacol., 13: 422.
- Dutta NK, Shastry MS (1959). Pharmacological action of *A. bracteolata* Retz. on the uterus. Indian J. Pharmacol., 20: 302.
- Edeoga HO, Okwu DE, Mbaebie BO (2005). Phytochemical Constituents of some Nigerian medicinal plants. Afr. J. Biotechnol., 4(7): 685-688.
- Ferrara N (1999). Role of vascular endothelial growth factor in the regulation of angiogenesis. Kidney Int. 56: 794-814.
- Fu SC, Hui CW, Li LC, Cheuk YC, Qin L, Gao J, Chan KM (2005). Total flavones of *Hippophae rhamnoides* promote early restoration of ultimate stress of healing patellar tendon in a rat model. Med. Eng. Phys., 27: 313-321.
- Gupta KC, Chopra IC (1954). Anti-tubercular action of *Adhatoda vasica* (N.O. Acanthaceae). Indian J. Exp. Biol., 42: 355-358.
- Heinrich M, Gibbons S (2001). Ethnopharmacology in drug discovery: an analysis of its role and potential contribution. J. Pharm. Pharmacol., 53: 425-432.
- Hernandez V, Recio MDC, Manez S, Prieto JM, Giner RM, Rios JL (2001). A mechanistic approach to the *in vivo* anti-inflammatory activity of sesquiterpenoid compounds isolated from *Inula viscosa*. Planta Med., 67: 726-731.
- Hong SS, Kim JH, Li H, Shim CK (2005). Advanced formulation and pharmacological activity of hydro gel of the titrated extract of *Centella asiatica*. Arch. Pharmacol. Res., 28: 502-508.
- Jagetia GC, Rajanikant GK (2004). Role of curcumin, a naturally occurring phenolic compound of turmeric in accelerating the repair of excision wound, in mice whole body exposed to various doses of gamma radiation. J. Surg. Res., 120: 127-138.
- Jagetia GC, Rajanikant GK (2005). Curcumin treatment enhances the repair and regeneration of wounds in mice exposed to Hemibody g-irradiation. Plast. Reconstr. Surg., 115: 515-528.
- Kalyon R, Shivakumar H, Sibaji S (2009). Wound healing potential of leaf extracts of *Ficus religiosa* on Wistar albino strain rats. Int. J. Pharm. Technol. Res., 1: 506-508.
- Khandelwal KR (2005). A text book of practical Pharmacognosy, 27th ed. Pune. Nirali Prakashan, pp. 151-163.
- Kumar A, Ram J, Samarth RM, Kumar M (2005). Modulatory influence of *Adhatoda vasica* Nees leaf extract against gamma irradiation in Swiss albino mice. Phytomedicine, 12: 285-293.
- Kumar R, Katoch SS, Sharma S (2006). – Adrenoceptor agonist treatment reverses denervation atrophy with augmentation of collagen proliferation in denervated mice gastrocnemius muscle. Indian J. Exp. Biol. 44: 371-376.
- Leite SN, Palhano G, Almeida S, Biavattii MW (2002). Wound healing activity and systemic effects of *Vernonia scorpioides* gel in guinea pig. Fitoterapia, 73: 496-500.
- Letts MG, Villegas LF, Marcalo A, Vaisberg AJ, Hammond GB (2006). In vivo wound healing activity of olanolic acid derived from the acid hydrolysis of *Androdera diffusa*. J. Nat. Prod., 69: 978-979.
- Loft S, Poulson HE (1996). Cancer risk and oxidative DNA damage in man. J. Mol. Med., 74: 297-312.
- Manjunatha BK, Vidya SM, Rashmi KV, Mankani KL, Shilpa HJ, Singh S (2005). Evaluation of wound-healing potency of *Vernonia arborea* Hk. Indian J. Pharmacol., 37: 223-226.
- Maquart FX, Chastang F, Simeon A, Birembaut P, Gillery P (1999). Triterpenes from *Centella asiatica* stimulate extracellular matrix accumulation in rat experimental wounds. Eur. J. Dermatol., 9: 289-296.
- Marja PK, Anu IH, Heikki JV, Jussi-Pekka R, Kalevi PTKS, Marina H (1999). Antioxidant Activity of Plant Extracts Containing Phenolic Compounds. J. Agric. Food Chem., 47: 3954-3962.
- Nayak BS, Vinutha B, Geetha B, Sudha B (2005). Experimental evaluation of *Pentas lanceolata* for Wound healing activity in rats. Fitoterapia, 76: 671-675.
- Nayak SB, Sandiford S, Maxwell A (2009). Evaluation of the wound healing activity of ethanolic extract of *Morinda citrifolia* L. leaf. eCAM, 6: 351-356.
- Okuda T (2005). Systematics and health effects of chemically distinct tannins in medicinal plants. Phytochem., 66: 2012-2031.
- Ozgen U, Ikbal M, Hacimuftuoglu A, Houghton PJ, Gocer F (2006). Fibroblast growth stimulation by extracts and compounds of *Onosma argentatum* roots. J. Ethnopharmacol., 104: 100-103.
- Ozturk N, Korkmaz S, Ozturk Y, Baser KH (2006). Effects of gentiopicroside, sweroside and swertiamarine, secoiridoids from gentian (*Gentiana lutea* ssp. symphyandra), on cultured chicken embryonic fibroblasts. Planta Med., 72: 289-294.
- Patil MB, Sunil J (2008). Antimicrobial and wound healing activities of leaves of *Alternanthera Sessilis*. Linn. Int. J. Green Pharm., 2: 141-144.
- Phillips GD, Whitehe RA, Kinghton DR (1991). Initiation and pattern of angiogenesis in wound healing in the rats. Am. J. Anat., 192: 257-262.
- Pryor WA (1997). Cigarette smoke radicals and the role of free radicals in chemical carcinogenicity. Environ. Health Perspect., 105 (suppl): 875-882.
- Raquel P, Laura B, Fulgencio S-C (2000). Antioxidant Activity of Dietary Polyphenols As Determined by a Modified Ferric Reducing / Antioxidant Power Assay. J. Agric. Food Chem., 48: 3396-3402.
- Rastogi RP, Mehrotra BN (1994). Compendium of Indian Medicinal

- Plants, Vol. I–V. Central Drug Research Institute, Lucknow and National Institute of Science Communication, New Delhi, India.
- Sadaf F, Saleem R, Ahmed M, Ahmad SI, Navaid-ul Z (2006). Healing potential of cream containing extract of *Sphaeranthus indicus* on dermal wounds in Guinea pigs. *J. Ethnopharmacol.*, 107: 161-163.
- Scortichini M, Pia RM (1991). Preliminary *in vitro* evaluation of the antimicrobial activity of terpenes and terpenoids towards *Erwinia amylovora* (Burrill). *J. Appl. Bacteriol.*, 71: 109-112.
- Shukla A, Rasik AM, Jain GK, Shankar R, Kulshrestha DK, Dhawan BN (1999). *In vitro* and *in vivo* wound healing activity of asiaticoside isolated from *Centella asiatica*. *J. Ethnopharmacol.*, 65: 1-11.
- Suguna L, Sivakumar P, Chandrakasan G (1996). Effect of *Centella asiatica* extract on dermal wound healing in rats. *Indian J. Exp. Biol.*, 34: 1208-1211.
- Tramontina VA, Machado MA, Nogueira FGR, Kim SH, Vizzioli MR, Toledo S (2002). Effect of bismuth subgallate (local hemostatic agent) on wound healing in rats. *Histological and histometric findings. Braz. Dent. J.*, 13: 11-16.
- Trombetta D, Puglia, Perri D, Licata A, Perogolizzi S, Lairiano ER (2006). Effect of polysaccharides from *Opuntia ficus-indica* cladodes on the healing of dermal wounds in the rat. *Phytomedicine*, 13: 289-294.
- Tsuchiya H, Sato M, Miyazaki T, Fujiwara S, Tanigaki S, Ohyama M (1996). Comparative study on the antibacterial activity of phytochemical flavanones against methicillin-resistant *Staphylococcus aureus*. *J. Ethnopharmacol.*, 50: 27-34.
- Werner S, Breeden M, Hubner G, Greenhalgh DG, Longaker MT (1994). Introduction of keratinocyte growth factor expression is reduced and delayed during wound healing in the genetically diabetic mouse. *J. Investig. Dermatol.*, 103: 469.