

Full Length Research Paper

A study of biological basis for radiographic appraisal of periradicular pathology

Kayode Ibikunle

Department of Anatomy and Molecular Pathology, School of Basic Medical Sciences, University of Lagos, Lagos, Nigeria. E-mail: kayodeibikunle@gmail.com

Accepted 2 July, 2015

The periodontium surrounds and supports the teeth and consists of four major components; gingiva, periodontal ligaments, cementum/dentin, and alveolar bone/lamina dura, with collective function of keeping the tooth in position despite varying changes and responses during mastication. A near-normal radiograph of periradicular tissues was used as the basis for evaluation of some common periradicular radiographic pathologies. Apical periodontitis was 70 (58.33%), alveolar abscess 32 (26.66%), and apical granulomas 15 (12.50%). A background anatomy of the periodontium is advocated as a precondition for accurate evaluation of periradicular pathologies.

Key words: Periodontium, periradicular, pathology.

INTRODUCTION

The periodontium surrounds and supports the teeth. It consists dominantly of four major components; gingiva, periodontal ligaments, cementum and the alveolar bone. They collectively function as a unit to keep the tooth in position, despite varying responses during mastication. In occlusal wear, the cementum is deposited apically to compensate the loss. Periodontal ligament has high turnover of cells that allows the teeth to be suspended in the socket. In response to applied force, bones resorb on the pressure side and are deposited on the tension side (Piezoelectric effect) (Skoog et al., 2007; Manbachi and Cobbold, 2011). Gingiva as an integral part of the periodontium, is not reflected radiographically, because it is a soft tissue, but has its peculiar pathology. However, the morphological characteristics of the gingiva depends on several factors like the dimension of the alveolar process,

the form of teeth, events that occur during tooth eruption, the eventual inclination and position of the fully erupted teeth (Skoog et al., 2007; Seba et al., 2014). Gingiva and the periodontal ligaments though not appearing radio-graphically have collagen, ground substance, cells, nerves and blood vessels in common (Berkovitz, 2004). The alveolar process, lamina dura, periodontal ligament space and the bulk of the root dentine are visible in dental periapical radiographs. Alveolar process is the bone of the jaw containing the sockets, and it is made up of buccal and lingual cortical plates, with a central spongy bone. The radiographically visible tooth supporting structures are alveolar processes, cementum/dentine, and alveolar bone/lamina dura. The radiographic health of this tissue determines the periodontal status of the teeth. Changes in the lamina dura are associated with dental disease and aging (Yamaoka et al., 2009),

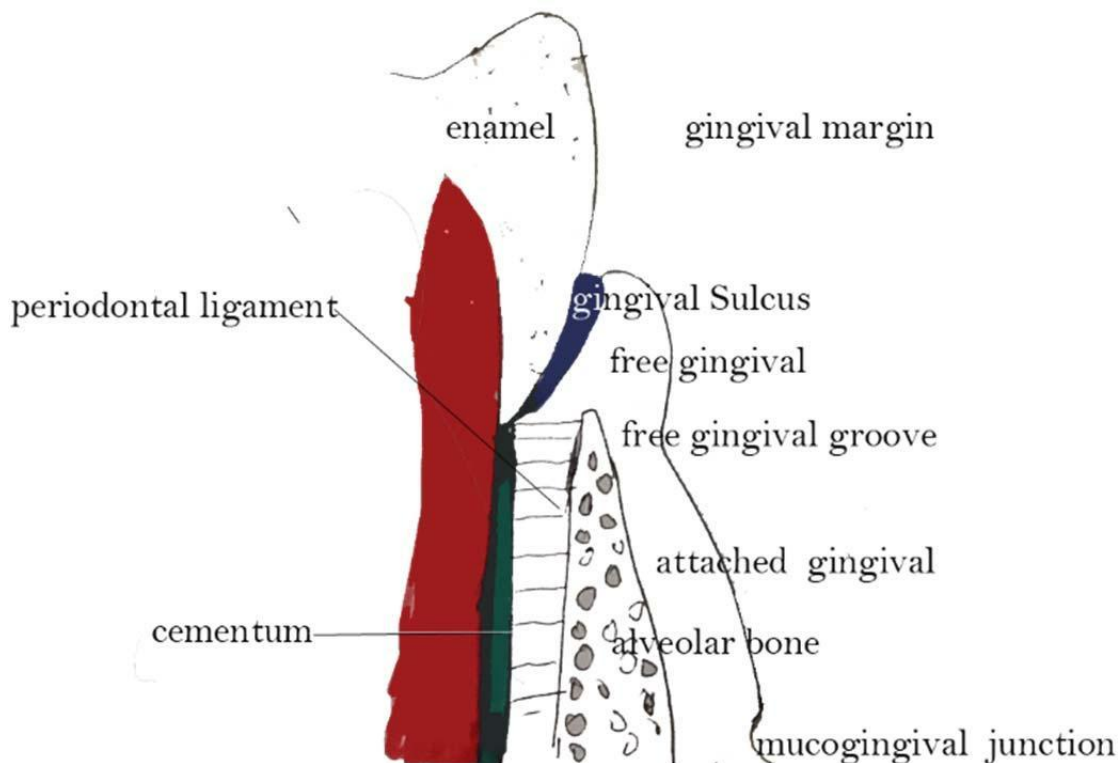


Figure 1. A graphic presentation of the anatomy of the periodontium (self).

and it is a determinant of dental status of periodontal tissue (Minoru et al., 2010). In health, the periodontal ligament space is constant. In periapical radiographs, it is a radiolucent area between radiopaque lamina dura of the alveolar bone and radio-paque dentine/cementum complex. This space contains progenitor cells in the periodontal ligament that can differentiate into osteoblasts for the physiological maintenance of alveolar bone; alveolar processes and their repairs (Nanci and Bosshardt, 2006). In health, the cementum which is a specialized calcified substance covers the root dentine up to the cemento-enamel junction and forms one of the side of the interproximal boundaries of the periodontal ligament space. In addition, it provides attachment through the Sharpey's fibers, and has protective role against root resorption (Emslie, 1978). Like any other mineralized tissue in the periodontium, it has similar extra cellular matrix (Grzesik and Narayanan 2002). In health, the periodontium functions as a unit to support all the functions of dentition and are diagrammatically represented as shown in Figure 1 and radiographically as shown in Figure 2.

This study therefore highlights the biological features of the periodontium as represented in Figure 1, that forms the basis for radiographic evaluation of periradicular tissues both in health and disease, as diagnosis of periodontal disease made on clinical basis needs to be supported by radiographic evidence of bone loss (Atchison et al., 1995; Corbet et al., 2009).

METHODOLOGY

The Department of Oral Diagnosis and Radiology has a diagnostic clinic which is usually the first point of clinical contact with patients. After clinical examination of patients, radiographic investigations are carried out routinely for records and medico legal reasons before definitive dental diagnosis is made. Sixty-five (65) final year dental students volunteered for class interactive peri-apical radiographic x-ray practice study. This study was designed to expose them on personal experience of the discomfort inherent in the intra-oral radiographic x-ray film insertion. They took turns to do it themselves. Out of these students, radiographic films were selected a near-normal radiographic film of the periradicular tissues as no tissue is absolutely normal, indicating the alveolar bone with its lamina dura, periodontal ligament space with its radiolucent periodontal membranes and the cementum/dentine area. The nature of the tooth apex area (Figure 3), was of great importance.

RESULTS

Out of the 65 dental student volunteers (Table 1), incidental symptomless findings revealed that periodontal pocketing and impaction were the major symptomless findings. Five volunteers had no noticeable pathology (7.69%). Symptomless impacted lower permanent third molars was 47 (72.30%) and asymptomatic periodontitis was 13 (20%) (Table 2). Periapical radiographs of the volunteers served as control of a near normal tissue state and the biological basis for evaluating periradicular radiographic pathology of the symptomatic patients (Figure 3). 120 symptomatic patients that visited the clinic were

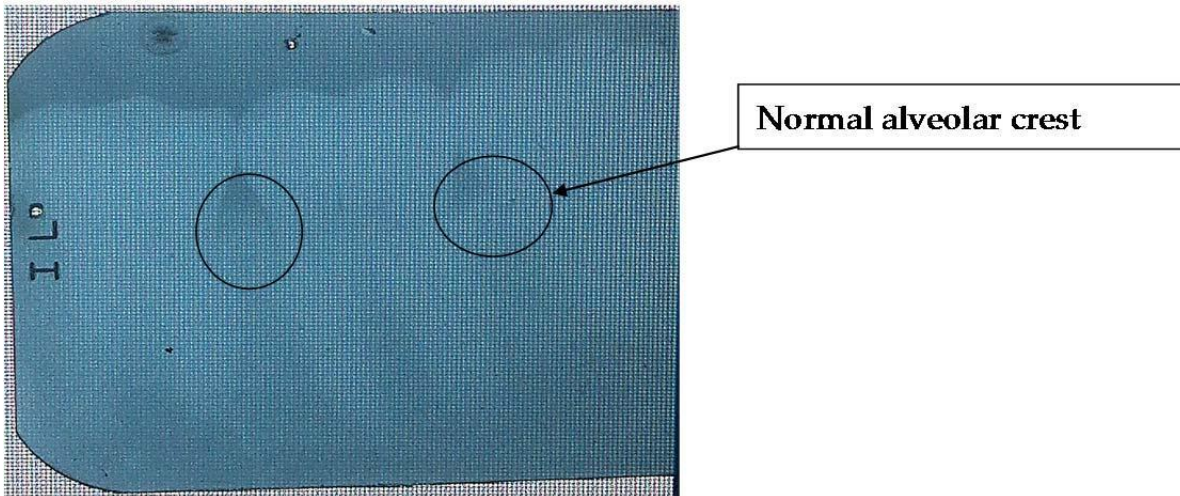


Figure 2. Periapical x-ray showing normal alveolar crest (self).

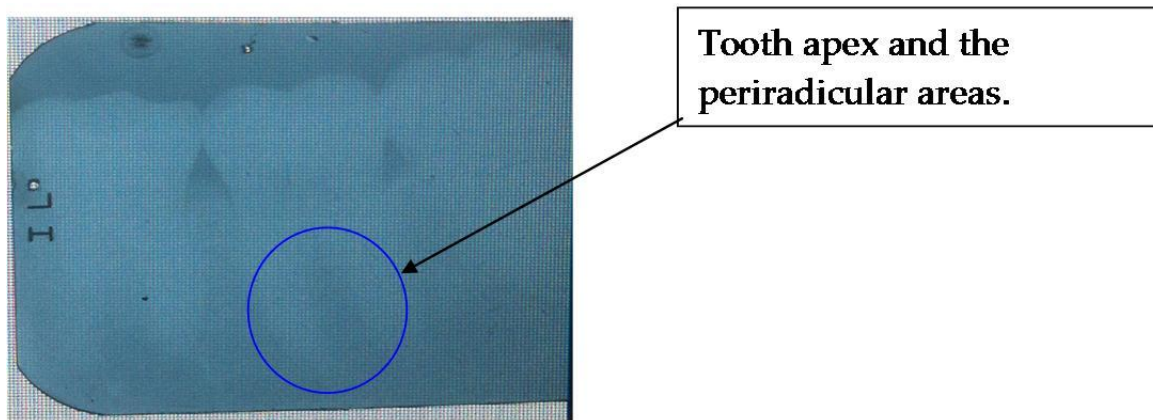


Figure 3. This near-normal periapical radiograph from students volunteers was the template on which comparison of symptomatic patients radiographs was made.

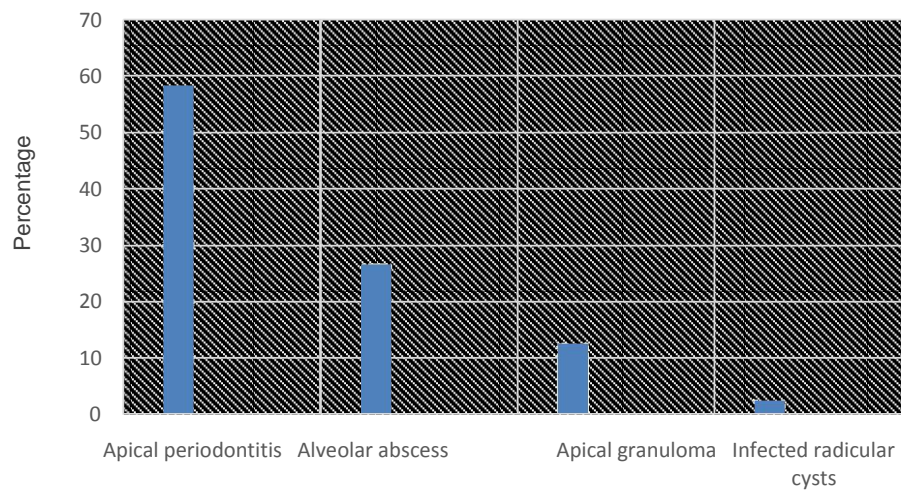


Figure 4. Symptomatic patients' radiographs.

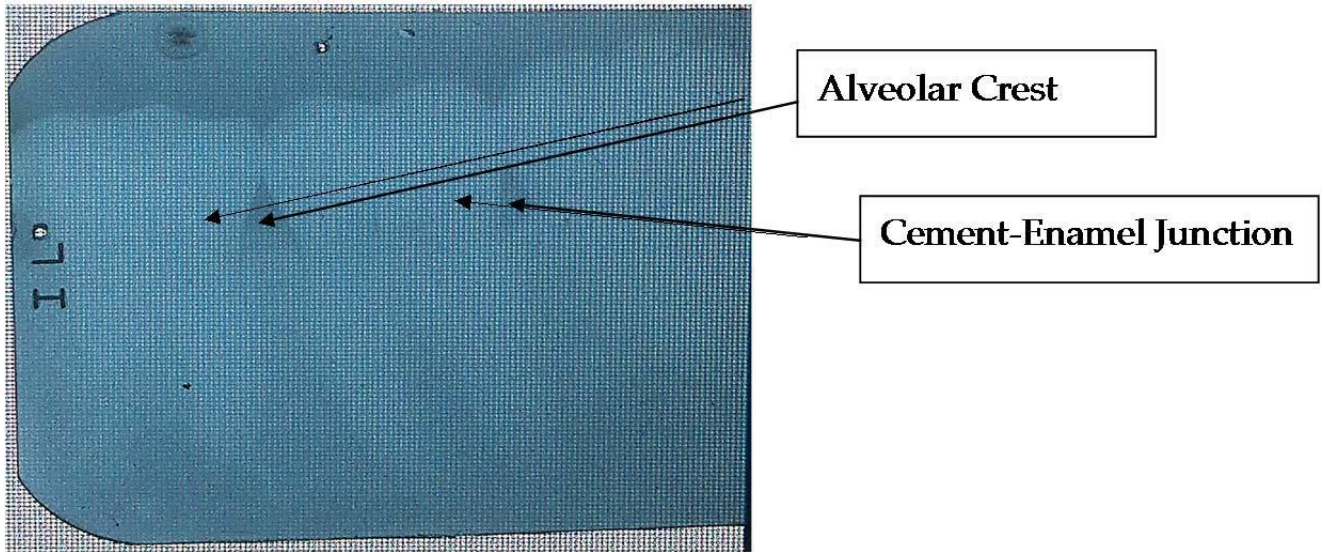


Figure 5. Near normal periapical x-ray showing alveolar crest and cement enamel junction.

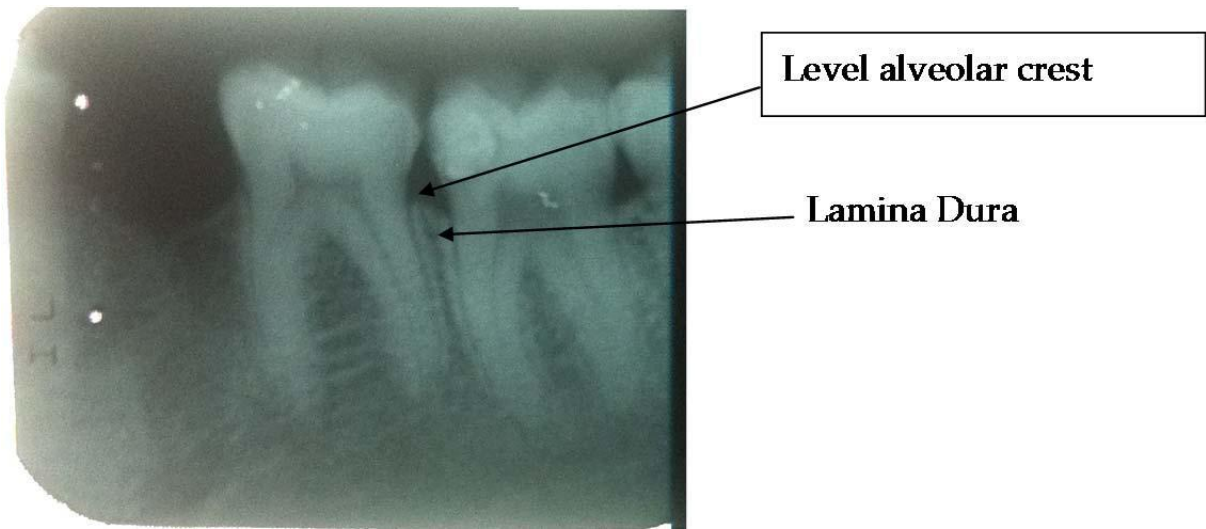


Figure 6. Periapical x-ray of diseased peri radicular tissues. Level alveolar crest and liminaduar.

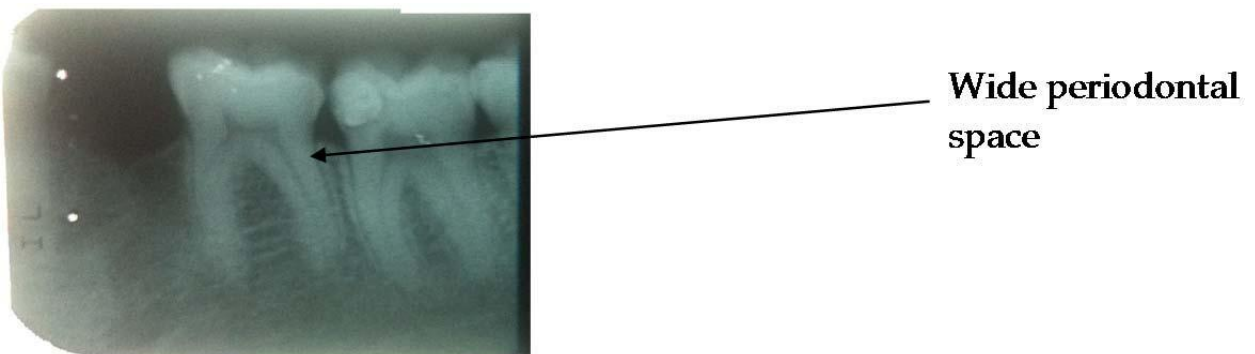


Figure 7. Periapical x-ray showing widening of periodontal space.




Figure 8. Periapical x-ray showing Apical periodontitis.

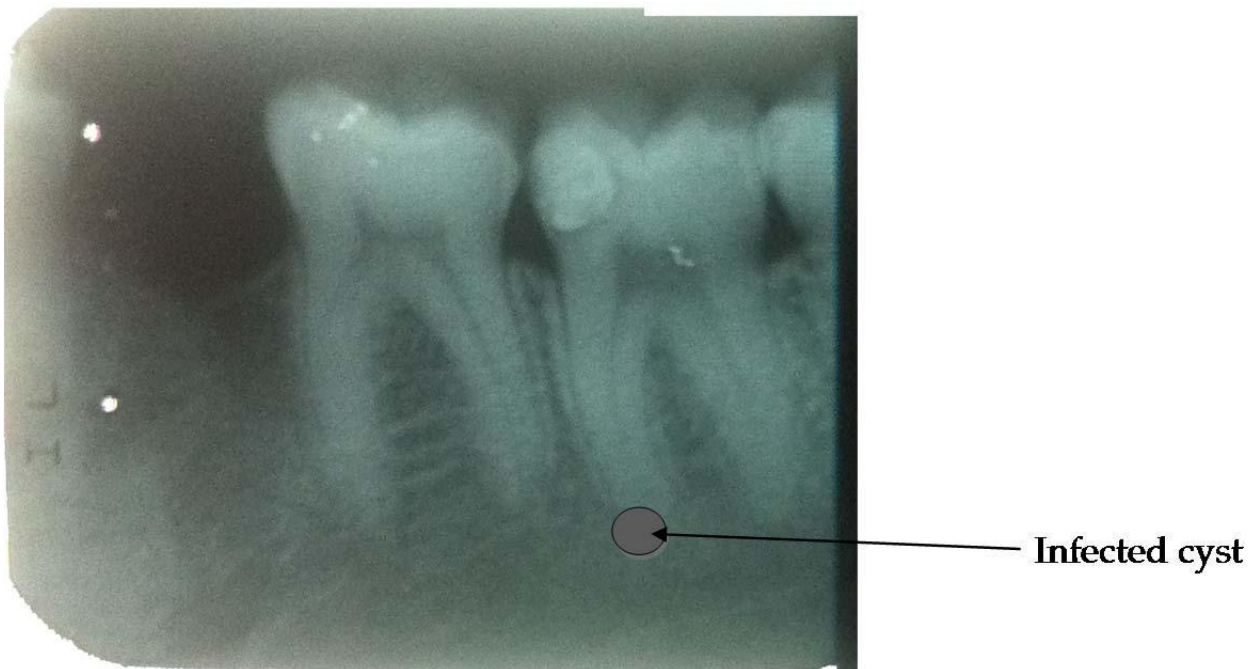


Figure 9. Periapical x-ray showing infected cyst.

radiographically investigated and revealed periradicular tissue changes (Figures 6, 7, 8, and 9) of apical periodontitis (Figure 8) alveolar abscess, apical granuloma, and radicular cyst (Figure 9). Out of the 120 symptomatic patients' radiographs, apical periodontitis was 70 (58.33%), alveolar abscess was 32 (26.66%), apical granulomas was 15 (12.50%) and infected radicular cysts was 3 (2.5%) as shown in Figure 4 and Table 2.

DISCUSSION

This study examined the overall functions of the periodontium in the support of the dentition. It equally reviewed the representative component of the periodontium and highlights their contribution to the collective supports of the teeth during function. In addition, it diagrammatically highlighted those components that can be seen on routine

Table 1. Asymptomatic dental students volunteers radiographs.

S/N	Radiographic findings	Number	%
1	Nil	5	7.69
2	Impacted third molars	47	72.3
3	Periodontitis	13	20

Table 2. Symptomatic patients' radiographs.

S/N	Pathology	Number	%
1	Apical periodontitis	70	58.33
2	Alveolar abscess	32	26.66
3	Apical granuloma	15	12.50
4	Infected radicular cysts	3	2.5

radiographic investigation, depending on the dental radio-graphy in use, computerized tomography (CT), magnetic resonance imaging (MRI), Doppler ultrasound or periapical radiographs. In this study, periapical radiograph was used, limiting the possible visible tissues to hard tissue as radiopaque and soft tissue within hard tissues as radiolucent. Apical periodontitis irrespective of the causa-tive agent (infection, trauma, chemical irritation) is a chronic disorder of periradicular tissues caused by aetiological agents of endodontic origin (Nair, 2006). It is a common knowledge that in pathological changes involving the periodontium, the radiographs are evaluated for alveolar bone changes, interdental bone height, and presence of lamina dura, trabecular patterns, periodontal ligament space and severity of bone loss.

In normal radiographic anatomy (Figure 5), the alveolar crest is apical to cement-enamel junction of the teeth, with rounded to flat shape tip. In the incisal area, they are pointed and in general continuous with the lamina dura.

In diseased radiographic anatomy (Figure 6), the alveolar crest level is decreased (bone loss) from the cemento-enamel junction and it may be localized bone loss. The lamina dura may be indistinct, irregular fuzzy or radiolucent (Figure 7). Periodontal ligament space, usually appears as a fine, black, radiolucent line next to the root surface in health. In disease, it appears with varying widening (Figure 7). In addition is the apical

periodontitis showing as apical radiolucency (Figure 8) and infected radicular cyst (Figure 9). In both (Figures 8 and 9), there is compromise in the quality of the alveolar bone leading to radiolucency (Huomonen and Orstavik, 2002; Nair, 2004; Grimard et al., 2009).

It is therefore concluded that the sound background of anatomy of the periodontium is a precondition for accurate interpretation of periradicular pathologies.

Conflict of Interests

The author(s) have not declared any conflict of interests.

REFERENCES

Atchison KA, White SC, Flack VF, Hewlett ER, Kinder SA (1995). Efficacy of the FDA selection criteria for radiographic assessment of the periodontium. *J. Dent. Res.* 74(7):1424-1432.

Berkovitz BK (2004). Periodontal ligaments: structural and clinical correlates. *Dent. Update* 31(1):46-54.

Corbet EF, Ho DKL, Lai SM (2009). Radiographs in periodontal disease diagnosis and management. *Aust. Dent. J.* 54(Suppl 1):27-43.

Emslie RD (1978). Some considerations on the role of cementum in periodontal disease. *J. Clin. Periodontol.* 5(1):1-12.

Grimard BA, Hoidal MJ, Mills MP, Melloming JT, Nummikoski PV, Mealev BL (2009). Comparison of clinical, periapical radiograph, and cone-beam volume tomography measurement techniques for assessing bone level changes following regenerative periodontal therapy. *J. Periodontol.* 80(1):48-55.

Grzesik WJ, Narayanan AS (2002). Cementum and

- periodontal wound healing and regeneration. *Crit. Rev. Oral Biol. Med.* 13(6):474-484.
- Huumonen S, Orstavik D (2002). Radiological aspects of apical periodontitis. *Endod. Topics* 1(1):3-25.
- Manbachi A, Cobbold RSC (2011). Development and application of piezoelectric materials for ultrasound generation and detection. *Ultrasound* 19(4):187-196.
- Minoru Y, Masahide I, Masahiro T, Takashi U, Kiyofumi F (2010). Bone formation with disruption of the lamina dura in the mandibular third molar. *Clin. Cosmet. Investig. Dent.* 2:1-3.
- Nair PN (2006). On the causes of resistant apical periodontitis: a review. *Int. Endod. J.* 39(4):249-281.
- Nair PNR (2004). Pathogenesis of apical periodontitis and the causes of endodontic failures. *Crit. Rev. Oral Biol. Med.* 15(6):348-381.
- Nanci A, Bosshardt DD (2006). Structure of periodontal tissues in health.