

Full Length Research Paper

Relative assessment of abnormalities patterns in hysterosalpingography, diagnostic laparoscopy and hysteroscopy with infertility cases in women in Nigeria

***Omelu Clever, Adajarha Esther, Owungalo Ebuka and Majimeta Anthony**

Department of Radiology, Obstetrics and Gynecology, Delta State University, Abraka, Nigeria.
E-mail: cleveromelu1@yahoo.com

Accepted 5 May, 2015

Laparoscopy and hysteroscopy procedures commenced recently in our center and no study has been done on them yet. Also, there is paucity of information in our environment on comparison of laparoscopy/hysteroscopy findings with hysterosalpingography (HSG) amongst infertile women. The purpose of this study was to evaluate pattern of the abnormalities detected on HSG in infertile women and to compare them with laparoscopy and hysteroscopy findings. A prospective study of 220 consecutive patients who had HSG between December, 2011 and May, 2013, at Department of Radiology, Ahmadu Bello University Teaching Hospital (ABUTH), Zaria, Nigeria was conducted. Clinical notes and radiological findings were analyzed for demographic data, uterine status, tubal and pelvic abnormalities. Findings were correlated with those of laparoscopy and hysteroscopy. Data was analyzed using EPI Info version 3.3.2 for windows. Of the 72 women with tubal occlusion on HSG, 46 (63.89%) women had laparoscopy with dye test. HSG demonstrated unilateral tubal occlusion in 35 (76.09%) women and bilateral tubal occlusion in 11 (23.91%) women. The laparoscopy with dye test also demonstrated unilateral tubal occlusion in 34 (73.91%) women and bilateral tubal occlusion in 10 (21.74) women. The difference in the findings of both tests on tubal patency was not statistically significant ($p>0.05$). All the 26 women with uterine adhesion on HSG had diagnostic hysteroscopy which confirmed all the cases. There was no difference in the findings of both tests ($p>0.05$). Both HSG and diagnostic laparoscopy are effective in evaluating tubal patency with no significant difference in accuracy. Also both HSG and hysteroscopy are effective in evaluating intrauterine adhesions with no difference in accuracy.

Key words: Abnormalities, hysterosalpingography, laparoscopy/hysteroscopy, infertility.

INTRODUCTION

Infertility is the failure to conceive (regardless of cause)

after one year of unprotected regular sexual intersexual

(Biotherapeutic Index, 2012). Infertility affects approximately 10 to 15% of reproductive-aged couples (Boudhraa et al., 2009). Its overall prevalence has been stable during the past 50 years; however, a shift in etiology and patient age has occurred (Boudhraa et al., 2009). As a woman's age increases, the incidence of infertility also increases (Biotherapeutic Index, 2012).

Infertility is caused by male and/or female factors. Male and female factors each account for approximately 35% of cases (Ugwu et al., 2012). Often, there is more than one factor, with male and female factors combined causing 20% of infertility (Adegbola et al., 2013). In the remaining 10% of cases, the etiology is unknown (Biotherapeutic Index, 2012). A study conducted in Nnewi, Nigeria revealed a high prevalence of male infertility of which oligozoospermia and asthenozoospermia which were the most common aetiological factors (Ikechebelu et al., 2003). Female factor infertility can be divided into several categories: cervical or uterine, ovarian, tubal and other (Ugwu et al., 2012). Abnormalities or damage to the fallopian tube interferes with fertility and is responsible for abnormal implantation such as ectopic pregnancy (Adegbola et al., 2013). Obstruction of the distal end of the fallopian tubes may result in hydrosalpinx and pyosalpinx (Boudhraa et al., 2009). Other tubal factors associated with infertility are either congenital or acquired.

Congenital absence of the fallopian tubes can be due to spontaneous torsion in utero followed by necrosis and reabsorption. Elective tubal ligation and salpingectomy are acquired causes. Tubal factors are responsible for 25 to 30% of infertility cases, with salpingitis being the most common cause, representing more than half of the cases (Chandra et al., 2005). Salpingitis partly contributes to the increased number of infertility cases as the occurrence has increased over the past 2 decades (Honore et al., 1999). Estimates show that after one episode of pelvic inflammatory disease (PID), an 11% risk of tubal infertility is present. This risk increases to 23% after 2 episodes of PID and as high as 54% after 3 episodes (Honore et al., 1999). The uterus contributes about 10% of causes of female infertility. Intra uterine adhesion (Asherman's syndrome) may complicate curettage following pregnancy related disorders. The more common types of fibroid (leiomyoma) that adversely affect reproduction are submucous and intra cavitory types. Endometrial polyps, if large enough can affect reproduction (Arati, 2004).

Congenital uterine anomalies are seen in about 2 to 3% of all women and approximately 25% of these will have associated infertility. The most common congenital defect associated with infertility is the septate uterus (Kamini, 2004). Other uterine factors causing infertility include adenomyosis and endometritis due to tuberculosis (Preutthipan and Linasmita, 2003). With the recent advances in reproductive medicine, hysterosalpingography has become a relatively quick and non-invasive examination aim to evaluate fallopian tubes and uterine

cavity (Ubede et al., 2001). Congenital uterine malformations, technical artefacts and pathological findings are depicted. Pathological findings that can be detected on hysterosalpingography include salpingitis isthmica nodosa, tubal blockage, peritubal adhesion, submucosal leiomyoma, endometrial polyp, endometrial carcinoma, synechiae and adenomyosis (Eng et al., 2007).

During the last 35 years, gynecologic laparoscopy has evolved from a limited surgical procedure used only for diagnosis and tubal ligations to a major surgical tool used to treat a multitude of gynaecologic indications (Ikechebelu et al., 2010). Today, laparoscopy is one of the most common surgical procedures performed by gynaecologists. For many procedures, such as removal of an ectopic pregnancy, treatment of endometriosis, or ovarian cystectomy, laparoscopy has become the treatment of choice (Hurd et al., 2007). In laparoscopy and dye test, the dye test will demonstrate if the fallopian tubes are blocked. The laparoscopy will help identify endometriosis, pelvic infection, adhesions, ovarian cysts or fibroids. Some minor treatments can be performed at the same time (Hawe, 2008). A study done in Osaka Japan demonstrated that diagnostic laparoscopy was beneficial for patients with unexplained infertility and normal HSG findings, as diagnostic laparoscopy was able to help detect the cause(s) of infertility in the pelvic cavity and helped to design a suitable management plan, which could lead to postoperative pregnancy. It was therefore suggested that patients with unexplained infertility and normal HSG findings should undergo diagnostic laparoscopy prior to the assisted reproductive therapy (Tsuji et al., 2009).

Many studies have been performed on comparing HSG and hysteroscopy which is generally indicated for a thorough study of the endometrial cavity (Ganglione et al., 1996; Pellicer, 1988). Whereas, HSG is a good screening procedure for uterine abnormalities, hysteroscopy is used for confirmation and treatment of either abnormalities found on HSG or those cases with normal HSG findings that had no improvement in fertility for at least 6 months (Ganglione et al., 1996). In a comparative study between HSG and hysteroscopy performed on 336 patients the most commonly misdiagnosed conditions are cervical stenosis as severe intrauterine adhesions, endometrial polyps as submucous myomas, and submucous myomas as endometrial polyps (Preutthipan and Linasmita, 2003). The purpose of this study was to evaluate pattern of the abnormalities detected on HSG in infertile women and to compare these findings with laparoscopy and hysteroscopy findings.

MATERIALS AND METHODS

This prospective study was carried out at the Ahmadu Bello University Teaching Hospital (ABUTH), which is a tertiary health institution located in Zaria, Kaduna State, Nigeria. The city has a

Table 1. Age group and type of infertility.

Age group (Years)	Type of infertility		Total (%)
	Primary (%)	Secondary (%)	
18-28	76 (46.4)	92 (54.8)	168 (76.4)
29-40	11 (21.2)	41 (78.8)	52 (23.6)
Total	87 (39.5)	133 (60.5)	220 (100)

Table 2. Uterine and cervical canal findings at HSG.

Characteristic	Uterine findings		Cervical canal findings	
	Frequency	%	Frequency	%
Normal	167	75.9	210	95.5
Adhesion	26	11.8	8	3.6
Fibroid	21	9.5	-	-
Bicornuate UT	4	1.8	-	-
Unicornuate UT	1	0.5	-	-
Septate UT	1	0.5	-	-
Dilatation	-	-	2	0.9
Total	220	100	220	100

UT = Uterus.

population of 975, 153 (National Population Commission, 2006). This prospective study was carried out between 1 December, 2011 and 31 May, 2013 on 220 consecutive patients referred from infertility clinics of the Ahmadu Bello University Teaching Hospital for hysterosalpingography. The subjects were married women with various years of infertility. The exclusion criteria were: ongoing or recent pelvic infection, late menses without confirmation of absence of pregnancy, recent history of intra uterine instrumentation and technical impairment in any of the examinations. The study was approved by the Ethics Committee of our Hospital and all patients gave informed consent. Demographic data such as age, parity, and duration of infertility were extracted from specially designed data collection form. All HSGs were performed by the same consultant Radiologist using the techniques by David and Jamil, (1999). After HSG, those with abnormalities were counseled for laparoscopy and hysteroscopy evaluations. Those that gave their informed consent had diagnostic laparoscopy and hysteroscopy. A specialist Gynecologist performed the laparoscopy and hysteroscopy using the laparoscopy and dye test (Hutchon, 2006) and technique by Preutthipan and Linasmita (2003), respectively. The cost of laparoscopy with dye test was three times that of HSG. The information was extracted and subsequently analyzed using EPI INFO Version 3.3.2 for windows. The results were displayed in frequency tables and percentage. Test of significance was done using 95% confidence intervals.

RESULTS

Two hundred and twenty (220) patients with infertility were interviewed and investigated. The age ranged from 18 to 40 years, and shows a normal age distribution curve, with mean age of 27.37 ± 4.50 (Figure 1). The duration of infertility ranges from 1 to 8 years with a mean duration of 4.48 ± 1.24 years as shown in Table 1. Table 1 also shows that women with secondary infertility were

133 (60.5%) while primary infertility was 87 (39.5%). The first aged group of 18 to 28 years had a high proportion of primary infertile participants (46.4%) while high proportion of secondary infertile patients, 78.8% were in age group 29 to 40 years. However, there was more secondary infertility in both age groups.

There were 72 (32.7%) patients who had normal HSG, while 148 (67.3%) patients had abnormal HSG. In Table 4, patients aged 29 to 40 years had more abnormal HSG findings (69.7%) than those aged 18 to 30 years (66.7%). The difference was not statistically significant (p -value=0.861). However, patients with secondary infertility had slightly more abnormal HSG findings (72.2%) than those with primary infertility (59.8%). This difference was not statistically significant (p -value=0.077). Patients with duration of infertility of 4 to 8 years had more abnormal HSG findings (74.1%) compared to those with short duration (53.4%). This difference was statistically significant (p -value=0.003).

The study revealed that fallopian tube abnormalities were the most common affecting 99 women; 37 (37%) women with primary and 62 (63%) women with secondary infertility, followed by uterine cavity abnormalities, affecting 53 women; 16 (30%) women with primary infertility and 37 (70%) women with secondary infertility. Peritoneal cavity abnormality (Pelvic adhesion) affects 17 women; 8 (47%) women with primary and 9 (53%) women with secondary infertility. The least finding was cervical canal abnormalities, affecting 10 women; 5 (50%) women with primary and 5 (50%) women with secondary infertility respectively, as shown in Figure 2. Table 2 shows that cervical synechia was the most common cervical canal abnormality, accounting for 3.6%

Table 3. Summary of HSG fallopian tubes findings.

Characteristic	Frequency	%	p-value (χ^2)
Normal	121	55.0	
Right occlusion	33	15.0	0.004
Left occlusion	28	12.7	
Bilateral occlusion	11	5.0	
Right hydrosalpinx	9	4.1	0.297
Left hydrosalpinx	14	6.4	
Bilateral hydrosalpinx	0	0	
Right SIN	0	0	-
Left SIN	2	0.9	
Bilateral SIN	2	0.9	
Total	220	100	

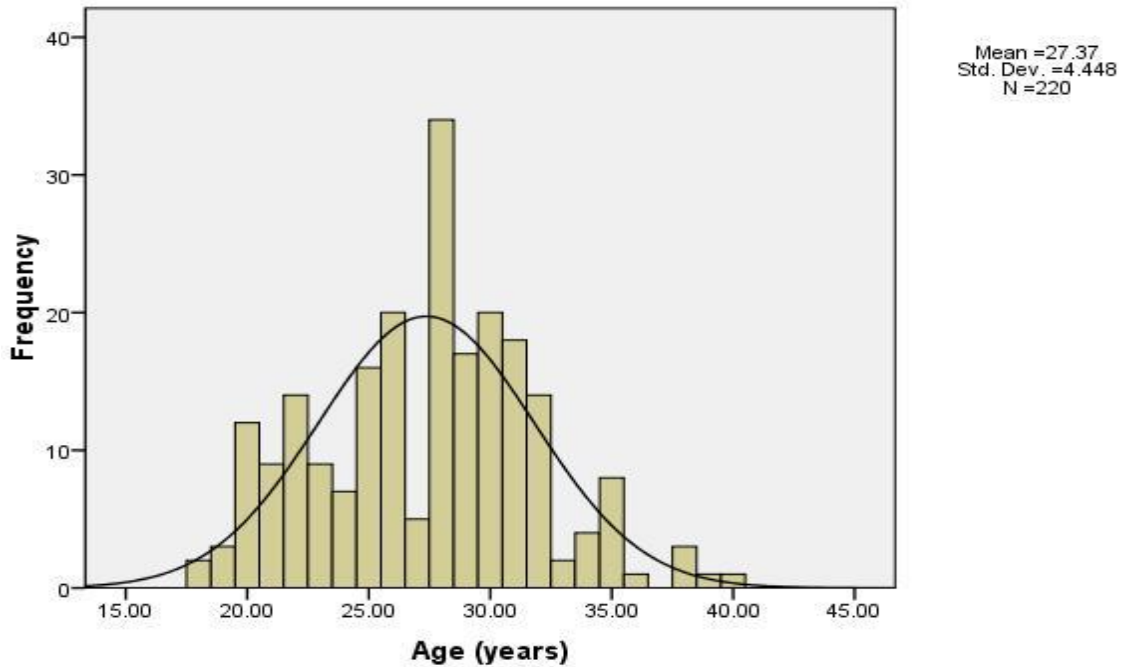


Figure 1. Histogram showing age distribution of patients.

of all the patients, with cervical dilatation as the least finding (0.9%). Table 2 also shows that uterine adhesion (Arsherman syndrome) was the most common uterine cavity abnormality seen, accounting for 11.8% of all patients. Uterine fibroid, seen as filling defects, uterine dilatation and deformity, was seen in 9.5% of the patients (Figure 3). Women who had congenital abnormality account for 2.8%, with bicornuate uterus (Figure 4) as the commonest and both unicornuate and septate uterus the least.

Table 3 shows that a total of 72 patients (32.7%) had

tubal occlusion. 11 patients (5%) had bilateral tubal occlusion. Right tubal occlusion was noted in 33 patients (15%), this was slightly higher than the left tubal occlusion, which was observed in 28 patients (12.7%), but difference noted was statistically significant (p-value= 0.004). A total of 23 patients (10.5%) had hydrosalpinx. Left hydrosalpinx (Figure 5) was noted in 14 patients (6.4%), while right hydrosalpinx was noted in 9 patients (4.1%), the difference noted was not statistically significant (p- value = 0.297). A total of 4 patients (1.8%) had salpingitisisthmlcalnodosa (SIN), which is usually

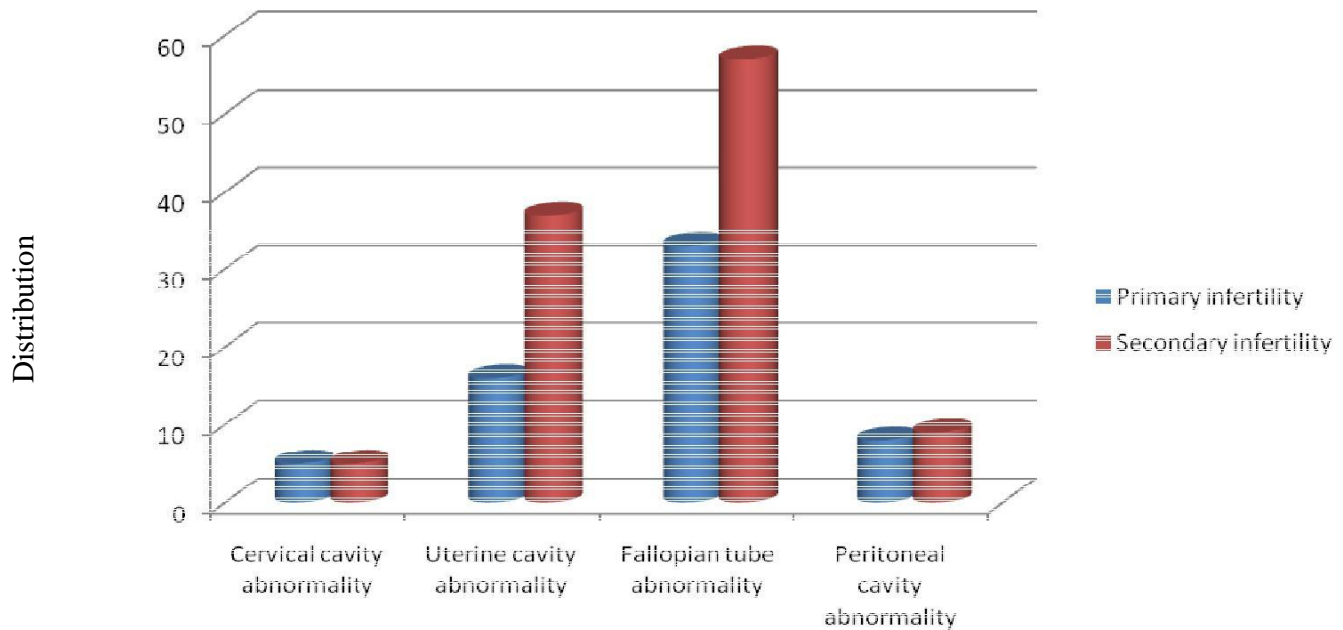


Figure 2. Distribution of uterotubal abnormalities in primary and secondary infertility.

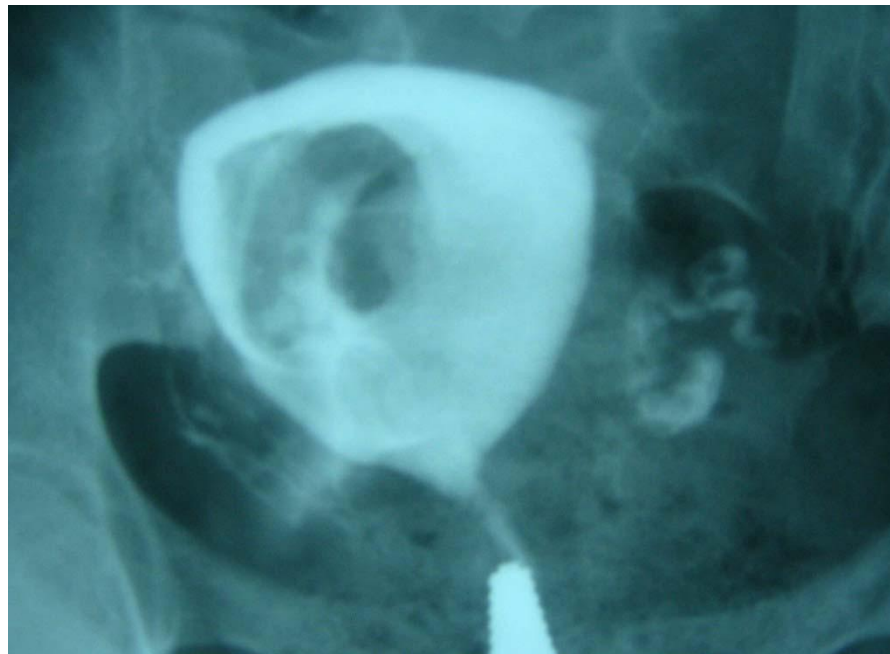

Figure 3. HSG image showing a grossly dilated uterine cavity with a filling defect due to submucous fibroid. The left tube is visualized and patent. The right tube is not visualized.

seen on HSG as small diverticula extending from the lumen of the tubes, 2 (0.9%) were bilateral while the remaining 2 (0.9%) had left SIN. There were 17 patients (7.7%) with pelvic adhesion, seen as loculated spill, convoluted or crowded tubes and vertical oriented tubes. Bilateral pelvic adhesion was seen in 5 patients (2.3%).

Right pelvic adhesion was seen in 8 patients (3.2%) while left pelvic adhesion was seen in 4 patients (1.8%). The difference noted was statistically significant (p -value = < 0.0001).

Following further diagnostic work up, diagnostic laparoscopy was performed for 46 patients for confirmation of

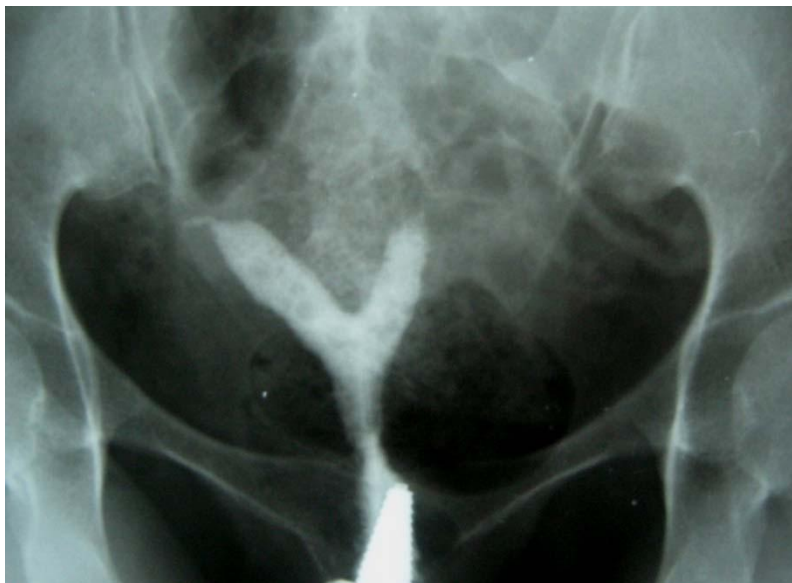

Figure 4: HSG image showing symmetrically separated uterine cavity with a single cervical canal (bicornuate unicollis uterus). Both fallopian tubes are proximally occluded.

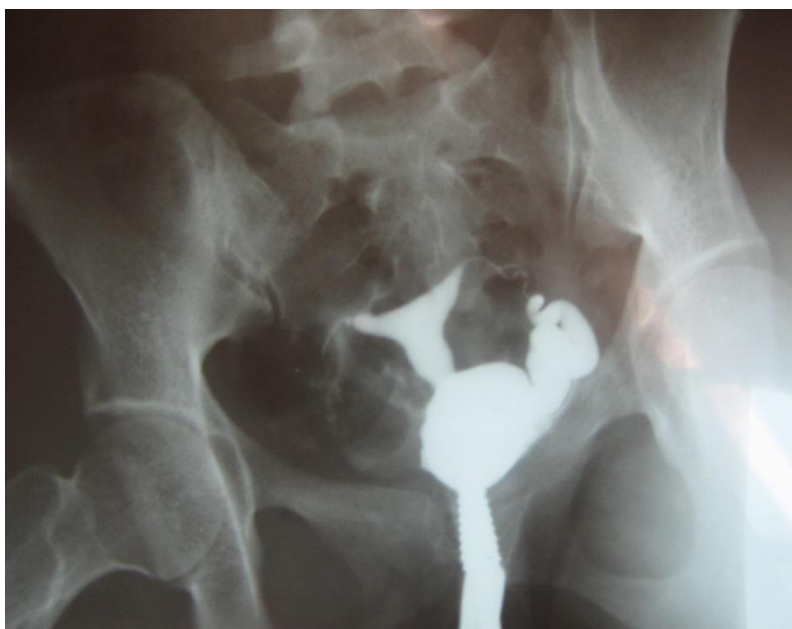

Figure 5. HSG showing dilated left fallopian tube (hydrosalpinx) without spillage of contrast medium into the peritoneal cavity. The right tube is proximally occluded.

tubal occlusions and 9 patients for confirmation of pelvic adhesions. Also, 21 patients diagnosed at HSG with intra uterine adhesions, had diagnostic and therapeutic hysteroscopy performed. Using laparoscopy with dye test and hysteroscopy as gold standards, findings were compared with HSG diagnosis. Table 4 shows that, out of

the 72 women with tubal occlusion on HSG, 46 (63.89%) women had laparoscopy with dye test. HSG demonstrated unilateral tubal occlusion in 35 (76.09%) women and bilateral tubal occlusion in 11 (23.91%) women. Hydrosalpinges, suspected peritubular adhesions and fibroids were found in 5 (10.87%), 9 (19.57%), 5 (10.87%)

Table 4. Findings on hysterosalpingogram, diagnostic laparoscopy with dye test and hysteroscopy.

Variable	HSG		Laparoscopy with dye test		Hysteroscopy		Statistical tests		
	No.	%	No.	%	No.	%	X ²	df	P value
Tubal patency									
Bilateral tubal occlusion	11	23.91	10	21.74	-	-	0.051	1	p>0.05
Unilateral tubal occlusion	35	76.09	34	73.91	-	-	0.164	1	p>0.05
Patent tube	-	-	2	4.35	-	-	-	-	-
Total	46	100.00	46	100.00	-	-	-	-	-
Endometrial cavity									
Intra-uterine adhesion	26	100	-	-	26	100	0.174	1	p>0.05
Others									
Hydrosalpinx/megasalpinx	5	10.87	19	41.30	-	-	7.030	1	P<0.05
Peritubular adhesions	9	19.57	17	36.96	-	-	5.212	1	P<0.05
Uterine filling defect / Fibroids	5	10.87	20	43.48	-	-	28.412	1	P<0.05

respectively. The laparoscopy with dye test also demonstrated unilateral tubal occlusion in 34 (73.91%) women and bilateral tubal occlusion in 10 (21.74) women. Some other laparoscopy findings included small uterine fibroids 20 (43.48%), Hydrosalpinges/megasalpinges 19 (41.30%), peritubal adhesions 17 (36.96%), ovarian adhesions 15 (32.61%), adhesions in pouch of Douglas 14 (30.43%), Congestion/hyperemia 7 (15.21%), ovarian cysts/masses 6 (13.04%) and omental adhesion 5 (10.87%). The difference in the findings of both tests on tubal patency was not statistically significant ($p>0.05$). Patients with adhesions at laparoscopy had adhesiolysis as therapeutic intervention.

All the 26 women with uterine adhesion on HSG had diagnostic hysteroscopy which confirmed all the cases. There was no difference in the findings of both tests ($p>0.05$). All the 26 patients with intrauterine adhesions at hysteroscopy had adhesiolysis as therapeutic intervention.

DISCUSSION

The mean age of participants in this study was 27.37 years; this was similar to the mean age of infertile women in another study by Bello (2004) in Ilorin, Nigeria. But this value is lower than that of Okafor et al. (2010) in Nnewi, southeastern Nigeria where the mean age of their study was 32.41. The difference may be due to cultural differences influencing the age at marriage. The mean duration of infertility was 4.48 years which is similar to previous study done in Nigeria (Bello, 2004). The mean duration of infertility is reported low in other study conducted by Fadare (2011). Most of the patients in this study had 4 to 8 years of infertility with majority of these patients, showing significant number of abnormalities

(74%). The presence of enormous local traditional healing practices and religious believes could be an important contributory factor for the delay in presentation to health facilities.

In this study more patients had secondary infertility than those with primary infertility, which is similar to other previous studies (Akinola et al., 2009; Watson et al., 1994). However this differs from other studies where it was found that primary infertility was commoner (Okaforet al., 2010; Obejide et al., 1986; Mesbazriet al., 2009). This higher rate of patients with secondary infertility compared to the primary infertility can be used as a crude indicator of the possible effects of pelvic inflammatory disease, post abortal sepsis and puerperal sepsis in our setting (Bello, 2004; Kiguli-Malwadde and Byanyima, 2004). In the present study, 220 patients, 72 cases (32.7%) had normal HSG findings, 148 patients had abnormal findings accounted for 67.3% of total cases. The demonstration of high abnormal findings in this study is comparable to that reported from Uganda (Baramki, 2005). The reason adduced for this could be due to the fact that ABUTH, being a tertiary hospital receives referrals from peripheral health facilities where initial evaluation of infertility causes has been done. Also most of these patients have already been seen and evaluated at ABUTH fertility clinic, hence more likely to have structural abnormalities.

From this study, cervical canal abnormalities were the least, accounting for 4.5% of all the patients, with cervical synechiae being the commonest (3.9%). This is similar to the findings of Saimaet et al. (2008). Cervical adhesion may be due to previous instrumentation, obstetric accidents or infection (Saimaet et al., 2008). Congenital uterine abnormalities which are due to Mullerian ducts abnormalities during the early weeks of gestation, accounted for 2.5% of the abnormalities detected on HSG in this

study. This is lower than 3.7% reported by Bukaret et al. (2011) in Maiduguri, but higher than 1.4% reported by Josephet et al. (1978). The most common congenital uterine abnormality was bicornuate uterus 1.8%. This is in agreement with the findings of Bukar et al. (2011), where bicornuate uterus was also the commonest (1.8%). Uterine synechia, (11.8%) was the most commonly acquired uterine pathology detected on HSG followed by uterine fibroid (9.5%). This is similar to the finding of Bukar et al. (2011), but contrast with that of Mgbor (2006), who found uterine fibroid as the leading uterine pathology. The high incidence of uterine synechia may be due to postpartum endometritis or overzealous curettage following abortion. The wide-spread use of manual vacuum aspiration for evacuation of the uterus is expected to lower the incidence of uterine synechia and consequently the contribution of uterine synechia to infertility in our environment (Bukar et al., 2011).

The prevalence of tubal abnormalities demonstrated in the present study was 45%, which was similar to what was reported by Bello (2004) in Ilorin, Nigeria (40%). This is much lower than that found by Akinola et al. (2009) in Lagos (61.8%). The commonest tubal abnormality found was tubal blockage (32.7%), which was similar to the report of Baramki (2005). Bilateral tubal blockage was noted in 5% of the total patients while right tubal blockage occurred in 15 % and left in 12.5% of the total patients. It may however be difficult to differentiate bilateral tubal blockage from bilateral cornual spasm or under filling from technical inadequacies. Radio-graphically, cornual spasm is characterized by tapering and smooth cornual margin, which is pointed or blunt and irregular in cases of occlusion (Baramki, 2005). However, the use of antispasmodics and a gentle technique was employed to minimize the effect of spasm in this study.

Hydrosalpinx is seen as a dilated convoluted tubular structure on HSG which gradually increase in size due to distal tubal occlusion (Neerja, 2001). It is a result of fallopian tubes inflammation following infections like gonococcal, chlamydial or tuberculosis of the genital tract. The fimbrial ends are eventually occluded due to adhesions leading to collection of the secretions in the lumen with gradual distension of the fallopian tube (Neerja, 2001). The incidence of hydrosalpinx (10.5%) is less in this study than similar studies done in Ilorin by Adetiloye (1988) (44.5%) and Bello (2004) (23.3%). This might be due to the conservative culture in Zaria predisposing the patients less to sexually transmitted diseases and post abortion complications responsible for hydrosalpinx. The lower value may also be due to the improvement in the health care delivery system over the years. A lot of researchers suggested that the presence of the appendix on the right side may predispose to increased pelvic inflammatory disease on the right side with resultant hydrosalpinx (Mesbazri et al., 2009). However in this study, the left hydrosalpinx (6.4%) was more than the right (4.1%), and therefore, the above

theory does not apply.

SIN is a rare condition involving the fallopian tube due to chronic salpingitis. It is usually seen on HSG as small diverticula extending from the lumen of the tubes, involving the isthmus and associated with infertility and ectopic pregnancy (Neerja, 2001). In this study, 1.8% of the total patients had SIN. This is similar to the finding of Troell (1970) (1.1%) but less than the finding of Creasy et al. (1985) who reviewed 1,184 HSG and identified only 45 patients with SIN (3.8%). Pelvic adhesions are usually formed as a result of inflammation from PID. Adhesion disturbs the delicate anatomical relationship between the tubes and ovaries, interfering with the normal ovulation or preventing the normal capture and transport of the ovum (Neerja, 2001). Laparoscopy is the gold standard for diagnosing pelvic adhesion (Akinola et al., 2009). HSG sensitivity in diagnosing pelvic adhesion ranges from 34 to 46% (Stephen and Goldfarb, 1989). However, with Stephen and Goldfarb (1989) criteria, which includes; convoluted tubule, peritubal halo effect, vertical fallopian tube and loculated spill, as used in this study, the sensitivity of HSG can be increased to about 75% in diagnosing pelvic adhesion (Stephen and Goldfarb, 1989). In this study, patients with features of pelvic adhesions accounted for 7.7% of all infertile patients. A study conducted previously by Elsie and Byanyima (2004) in Uganda, showed that the peritubular adhesion was higher (28%) while that done by Baramki (2005) in Pakistan was lower (7%) for all patients. This high incidence of tubo-peritoneal related pathologies may be due to PID which is reported to be the most common gynaecological disease affecting many African women (Neerja, 2001; Bello, 2004). Also, non-compliance to PID treatment, which may lead to sub-acute or chronic PID with deleterious effects on the fallopian tubes, may also be a contributory factor. This indicates that pelvic inflammatory disease (PID) is still common in our environment and makes it a common cause of infertility.

In this study, it was observed that patients with secondary infertility had more pathology (49.1%) than those with primary infertility (28.2%). This is similar to previous studies which showed secondary infertile patients to have higher proportion of pathology than primary infertility patients (Bello, 2004; Kiguli-Malwadde and Byanyima, 2004). And also most pathologies were also higher among secondary than primary infertility when considering individual utero-tubal abnormalities. This may be because most patients with secondary infertility are advanced in age and may have been exposed to post-abortal and obstetric complications. In ABUTH fertility center, HSG is still the most common first-line diagnostic test to evaluate the uterine cavity, tubal patency and pelvic pathologies. Laparoscopy/ hysteroscopy is performed when tubal, uterine or pelvic pathologies are suspected or detected by HSG.

In this study, Both HSG and laparoscopy with dye test are effective in evaluating tubal patency with no significant

difference in accuracy. This is at par with findings from several studies including the works done by Snowden et al. (1984), Tsuji et al. (2009), Sakar et al. (2008). This differs from the findings of a study done in Amsterdam, Netherlands on women requiring in-vitro fertilization (Tanahatue et al., 2008) in whom there was poor correlation between results of HSG and laparoscopy, even when HSG demonstrated bilateral tubal occlusion.

In this study, aside demonstration of tubal patency, laparoscopy with dye test was able to demonstrate far more tubal and non-tubal pathologies when compared with HSG. This is not surprising because in the former, the surgeon has direct view of the tubes, uterus, ovaries and other intra-abdominal organs. This finding is also similar with other reports from other similar studies such as the work done by Sakar et al. (2008) as well as La Sala et al. (1987). These tubal and non-tubal findings besides demonstration of tubal blockage, may reveal the actual causes of infertility in a patient, hence, laparoscopy is very essential in management of infertility especially in patients with suspected tubal pathology or those with unexplained infertility.

In the current study, both HSG and hysteroscopy are also effective in evaluating endometrial adhesion with no difference in accuracy. This is in agreement with previous study by Preuthipan and Linasmita (2003). The high accuracy of HSG in assessing tubal patency in this study could be ascribed to the use of IV Hyoscine-N-Butyrbromide (20mg) which prevents tubal spasm during HSG (Baramki, 2005).

Conclusion

Both HSG and diagnostic laparoscopy are effective in evaluating tubal patency with no significant difference in accuracy. Also both HSG and hysteroscopy are effective in evaluating intrauterine adhesions with no difference in accuracy.

Conflict of interest

The authors have not declared any conflict of interest.

REFERENCES

Adetiloye VH (1988). Radiological patterns of diseases on Hysterosalpingography. Dissertation, National Postgraduate Medical College of Nigeria, Lagos. pp. 64-100.

Akinola RA, Akinola OI, Fabamwo AO (2009). Infertility in Women: Hysterosalpingographic Assessment of the Fallopian Tubes in Lagos,

Nigeria. *Educ. Res. Rev.* 4(3):86–89.

Arati RRO (2004). Uterine and cervical factors in Infertility. In: *The Infertility Manual*, 2nd Edition. Jaypee, India. pp. 213-217.

Baramki TA (2005). Hysterosalpingography. *Fertile Sterile* 83(6):1595–1606.

Bello TO (2004). Pattern of Tubal Pathology in Infertile Women on Hysterosalpingography. *Ann. Afr. Med.* 3(2):72–79.

Biotherapeutic Index (2012). Infertility. A Medical Compendium for Health Care Professionals, BRIZA PUBLICATIONS. Available at: http://www.arnibia.ru/cgi-bin/index.cgi?id=321&sid=a20c1d85e4ae894012678f86f53b74e2&id_per=1186

Boudhraa K, Jellouli MA, Kassaoui O, Ben AN, Ouerhani R, Triki A, Gara MF (2009). Role of the hysteroscopy and laparoscopy in management of the female infertility: about 200 cases. *Tunis. Med.* 87(1):55-60.

Bukar M, Mustapha Z, Takai UI, Tahir A (2011). Hysterosalpingographic findings in infertile women: A seven year review. *Niger. J. Clin. Pract.* 14:168-170.

Chandra A, Martinez GM, Mosher WD, Abma JC, Jones J (2005). Fertility, family planning, and reproductive health of US women: data from the 2002 National Survey of Family Growth. *Vital Health Stat.* 23(25):1-160.

Creasy JL, Clark RLC, Cuttins JT, Groff TR (1985). Salpingitisisthmicanodosa: Radiological and clinical correlates. *Radiology* 154:597-600.

David JOH, Jamil AF (1999). Hysterosalpingogram. In: *Normal radiographic anatomy*. 4th Edition, Blackwell Scientific Publication pp. 29–39.

Kiguli-Malwadde E, Byanyima RK (2004). Structural Findings at hysterosalpingography in Patient with Infertility. *Afr. Health Sci.* 4(3):178–181.

Eng CW, Tang PH, Ong CL (2007). Hysterosalpingography: current applications. *Singap. Med. J.* 48(4):368-373.

Fadare OO (2011). Reproductive outcome following hysteroscopicadhesiolysis in patient with asherman's syndrome. *World J. Laparosc. Surg.* . 4(1):31-39.

Ganglione R, Valentini AL, Pistilli E, Nuzzi NP (1996). A comparison of hysteroscopy and hysterosalpingography. *Int. J. Gynecol. Obstet.* 52:151-153

Honore GM, Holden AE, Schenken RS (1999). Pathophysiology and management of proximal tubal blockage. *Fertil. Steril.* 71(5):785-789.

Hutchon D (2006). Laparoscopy and dye test. Available at: <http://www.privatehealth.co.uk/private-operations/Gynaecology/laparoscopy-and-dye-test-hydrotubation/>

Hurd WW, Falcone T, Sharp HT (2007). *Gynecologic Laparoscopy*. WebMD LLC.

Ikechebelu JI, Adinma JIB, Orié EF, Ikegwonu SO (2003). High prevalence of male infertility in South-Eastern Nigeria. *J. Obstet. Gynecol.* 23(6):657-659.

Ikechebelu JI, Eke NO, Eleje GU, Umeobika JC (2010). Comparison of the Diagnostic accuracy of Laparoscopy with Dye Test and Hysterosalpingography in the evaluation of infertile women in Nnewi, Nigeria. *Trop. J. Laparoendosc.* 1(1):39-44.

Joseph SS, Marvin AY, Orsun S (1978). Hysterosalpingography in the Evaluation of Infertility. *Fertile Sterile* 30(6):636–643.

Kamini ARO (2004). Uterine congenital abnormalities and infertility. In: *The Infertility Manual*. 2nd Edition, Jaypee, India. pp. 181–196.

La Sala GB, Sacchetti F, Degl'Incerti-Tocci F, Dessanti L, Torrelli MG (1987). Complimentary use of hysterosalpingography, hysteroscopy and laparoscopy in 100 infertile patients: results and comparison of their diagnostic accuracy. *Acta Eur. Fertil.* 18(6):369-374.

Mesbazi S, Pourissa M, Refahi S, Tabarraei Y, Dehgha MH (2009). Hysterosalpingographic abnormalities in infertile women. *Res. J. Biol. Sci.* 4(4):430-432.

Mgbor SO (2006). Pattern of Hysterosalpingographic findings in gynaecological patients in Enugu. *Niger. Med. J.* 47:14-16.

National Population Commission (2006). *National Demographic Survey*. Naula U (2005). Hysterosalpingography. *Prof. Med. J.* 12(4):386-391.

- Neerja B (2001). Infection as they infect individual organs. In: Pratap K, Narendra M (eds.), *Jeffcoates principles of Gynaecology*. 6th Edition, Lancet. pp. 355–374.
- Obejide AO, Ladigo OA, Otolorin FO, Makamagbola JDA (1986). Infertility in Nigerian women. A study of related physiological factors. *J. Obstet. Gynaecol. East Cent. Afr.* 5:61–63.
- Okafor CO, Okafor CI, Okpala OC, Umeh E (2010). The pattern of hysterosalpingographic findings in women being investigated for infertility in Nnewi, Nigeria. *Niger J. Clin. Pract.* 13(3):264-267.
- Pellicer A (1988). Hysteroscopy in the infertile woman. *Obstet. Gynecol. Clin. North Am.* 15:99-105.
- Preutthipan S, Linasmita V (2003). A prospective comparative study between hysterosalpingography and hysteroscopy in the detection of intrauterine pathology in patients with infertility. *J. Obstet. Gynecol. Res.* 29:33-37
- Saima N, Syed Shafat-Ul- Islam, SbtainRaza, Haji Haroon (2008). Pattern of Pathologies on Hysterosalpingography in Primary Infertility. *PJR* 18(3):82–86.
- Sakar MN, Gul T, Atay AE, Celik Y (2008). Comparison of hysterosalpingography and laparoscopy in evaluations of infertile women. *Saudi Med. J.* 29(9):1315-1318.
- Snowden EU, Jarrett JC, Dawood MY (1984). Comparison of diagnostic accuracy of laparoscopy, hysteroscopy and hysterosalpingography in evaluation of female infertility. *Fertil. Steril.* 41(5):709-713.
- Stephen K, Alvin FG (1989). Peritubal adhesion in infertile women: Diagnosis with Hysterosalpingography. *Afr. J. Reprod.* 152:777-779.
- Tanahatue S, Lambalk C, McDonnell J, Dekker J, Mijatovic V, Hompes P (2008). Diagnostic laparoscopy is needed after abnormal hysterosalpingography to prevent over-treatment with IVF. *Reprod. Biomed Online* 16(3):410-415.
- Troell S (1970). Diverticula of the wall of fallopian tubes. *Acta Obstet. Gynecol. Scand.* 49:17-20.
- Tsuji I, Ami K, Miyazaki A, Hujinami N, Hoshiai H (2009). Benefit of diagnostic laparoscopy for patients with unexplained infertility and normal hysterosalpingography findings. *Tohoku J. Exp. Med.* 219(1):39-42.
- Ubede B, Marta P, Enric A, Ramonm A (2001). A Pictorial Essay: hysterosalpingography: spectrum of normal variant and pathological findings: *Afr. J. Reprod.* 177:133-135.
- Watson A, Vandekerckhove P, Lilford R, Vail A, Brosens I, Hughes E (1994) . A meta-analysis of the therapeutic role of oil soluble contrast media at hysterosalpingography: a surprising result? *Fertil. Steril.* 61(3):470-477.