

Full Length Research Paper

Medial and lateral canthal distances in unrepaired cleft lip and palate Nigerians

Umweni, A. A.

Department of Preventive Dentistry, School of Dentistry, University of Benin, Benin City, Edo State, Nigeria.
E-mail: aliceumweni@yahoo.co.uk.

Accepted 14 April, 2019

Medial canthal distance (MCD) (inner canthal distance) refers to the distance between the two medial canthal of the eyes, while lateral canthal distance (LCD) (outer canthal distance) is the distance between the two laterals canthal of the eye. Accurate measurements of these distances are necessary for the diagnosis of true ocular hypertelorism and a guide in both reconstructive surgery and orthodontic treatment. The study was carried out on unrepaired cleft lip and palate (CLAP) patients, who presented for surgical repair at NOMA children hospital Sokoto, Nigeria before surgery. Results of the measurements were compared with previously documented normal values in the Nigerian population of the same age group. The result of the study shows that medial and LCDs in CLAP patients was higher than normal population ($P < 0.01$). When comparing type of clefts, MCD was highest in unilateral cleft lip. Medial and lateral distances in isolated cleft palate were comparable to normal values which are in agreement with previous studies. Although medial and lateral canthal measurements are less accurate than inter – orbital measurements which are from radiograph and carpal tunnel syndrome (CTS), however they are simple to use for standard clinical workups. This study suggests a tendency to true ocular hypertelorism in CLAP patients and not isolated cleft palate which is relevant in the surgical and orthodontic management of these patients.

Key words: Canthal distances, cleft lip, palate.

INTRODUCTION

Medial canthal distance (MCD) (inner canthal distance) refers to the distance between the two medial canthal of the eyes, while the lateral canthal distance (LCD) (outer canthal distance) is the distance between the two lateral acanthi of the eyes. Accurate measurement of these distances is necessary for diagnosis of true ocular hypertelorism, and a guide in both reconstructive surgery and orthodontic treatment. True ocular hypertelorism is when both inner and outer canthal distances are far apart. Ocular hypertelorism has increased width between the eyes due to an arrest in the development of the

greater wings of the sphenoid bone, making them smaller than the lesser wings, thus fixing the orbits in the unduly separated fetal position (Bojlen and Bremus, 1938).

Hypertelorism is a feature of many syndromes. It occurs for example, in facioidigitogenital dysplasia, Greig syndrome and optitz G syndrome. Pseudohypertelorism occurs in Waardenburg syndrome in which lateral displacement gives mistaken impression of excessive distance between the eyes.

Primary telecanthus is when inner canthal distances are far apart but outer canthal distances are normal. Secondary telecanthus is the disproportionate increase in MCDs with ocular hypertelorism. Illusory hypertelorism may occur in people with flat nasal bridge, epicanthal folds, exortopia narrow palpebral fissure, widely spaced eyebrows and dystopia canthorum. For example, Trisomy 21 syndrome, epicanthic folds and flat nasal bridge both




Figure 1. Sex distribution of cleft lip and palate patients.

contribute to the illusion of hypertelorism, although measurements actually show ocular hypotelorism (Gerald and Silverman, 1965; Greig, 1924).

Several studies have shown that mean values of facial measurement including canthal distance are race, age and gender sensitive (Laestadius et al., 1969; Juberg et al., 1975; Ozturk et al., 2006; Osuobeni and al- Musa, 1993). It has also been known that canthal values for an individual vary with age and tend to become constant in the mid to late twenties (Fledalius and Stubgaard, 1986), that is the reason for comparing normal values to match for age, sex, race and gender.

Normal canthal values that can serve as a guide for diagnosis of pathology and surgical interventions for craniofacial abnormalities are available in Caucasians (Laestadius et al., 1969), North American blacks (Juberg et al., 1975; Murphy and Laskin, 1990), Indian population (Singh and Banerjee, 1983), Turkish population (Ozturk et al., 2006), and the Nigerian population (Saheeb et al., 2004).

Normal values for these distances have previously been reported by Nigerians which was significantly different from Caucasians values, (Saheeb et al., 2004). Studies carried out on cleft lip and palate (CLAP) patients in Caucasian population showed an increase in inter-orbital distance in patients with non syndrome Orofacial clefts, (Aduss et al., 1971; Moss, 1965; Figalov et al., 1974).

Different methods of measurements have been used by different investigators. Bony inter-orbital measurements from radiograph or computed tomography are the most accurate and are important for surgical consideration (McFee et al., 1986). Although, inner and outer canthal measurements are less accurate than bony inter -orbital measurement, they are simple to use for standard clinical workshops.

This study intends to measure these distances in unrepaired CLAP patients between the ages of 3 to 18 years and compare the results with previously documented normal values in the Nigerian population of the same age group.

No study on the canthal values CLAP patients is available in the literature to the best of my knowledge.

MATERIALS AND METHODS

All CLAP patients who presented at NOMA Children's Hospital Sokoto, Nigeria for surgical repair were examined before surgery. NOMA children's hospital is a reference centre for clefts and NOMA patients covering Northern states of Nigeria. Permission for participation in the study was obtained from the chief medical director of the hospital, parent of indigene's children and consent from other participants. Information on sex, age, and height was obtained. The ages were approximated to the nearest birthday.

Three to eighteen years of age of CLAP patients were assessed for MCD and LCD. The medial and LCDs were measured using a graduated caliper in millimeters. The standard points of measurements for the medial angles of the palpebral fissure while LCD was measured from the outermost edge of the bony orbit.

Both comparative and descriptive statistics were used to analyze the results. CLAP patients with associated syndromes, or mixed races were excluded from the study. The comparative test was conducted using the paired student's t-test to demonstrate any statistical significance between the medial and LCDs, between male and female of un-repaired CLAP Nigerians and with normal Nigeria population.

RESULTS

Forty-three CLAP patients comprising of 27 (63%) males and 16 (37%) females were studied (Figure 1). Mean age for females 9.1 years, range from 4-16, while mean age for males is 9.2 years, and range from 3-17 years. MCD for males CLAP patients 39.3 mm as against 31.9 mm for normal population while mean female MCD was 39.3 mm compared with 31.6 mm for normal population (Tables 1 and 2).

The mean, LCD for CLAP males was 110.8 mm while a normal population male was 105.2 mm (Table 3). Mean LCD for females CLAP was 110.5 mm compared with 104.8 mm for normal sample (Table 2). Mean MCD and LCD for both males and females were significantly higher in CLAP patients than normal population ($p < 0.01$).

Table 1. Mean canthal distances according to cleft types.

Type	Sample size	MCD (mm)	LCD (mm)
Unilateral cleft lip	31	40.54	111.6
Isolated palate	3	33.5	107.5
Unilateral cleft and palate	5	36.4	108.8
Bilateral cleft and palate	4	34.68	103.8

Table 2. Comparing medial canthal distance of normal Nigerian population and un-repaired cleft lip and palate.

Group	Pooled mean	Calculated	Tabulated		Remarks
			0.05	0.01	
Nigerian males normal versus unpaired CLAP male	31.9 v 39.3	7.60	2.060	2.787	**
Nigerians normal females versus Unpaired CLAP female	31.6 v 39.3	4.75	2.131	2.947	**
Unrepaired CLAP males versus Unrepaired CLAP females	39.3 v 39.3	0.028	2.021	-	#

** , Significant; * , p<0.05; ** , p<0; # , not significant.

Table 3. Comparing lateral canthal distance of normal Nigerian population and unrepaired cleft lip and palate.

Group	Pooled mean	Calculated	Tabulated		Remark
			0.05	0.01	
Nigerian normal male versus Un-repaired CLAP males	105.2 v110.8	4.08	2.060	2.787	**
Nigerian normal females versus CLAP females	104.8 v110.5	3.23	2.131	2.947	**
Un-repaired CLAP males versus Un-repaired females	110.8 v 110.5		0.136	2.021	#

#, Not significant; **, p<0.05; **, p<0.01.

There was no significant difference between the male and female MCD and LCD values in unrepaired CLAP patients. Comparing type of clefts, MCD 40.54 mm and LCD 111.6 mm were highest in unilateral cleft lip, while MCD 33.5 mm and LCD 107.5 mm in isolated cleft palate were comparable to normal. There was essentially no difference between male and female MCD, both in the clefts and normal population (Figure 2). The mean LCD according to sex was higher in male CLAP patients as in the normal population (Figure 3).

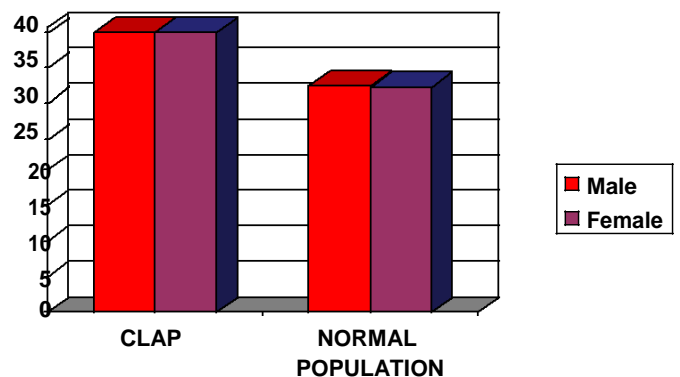


Figure 2. Mean medial canthal distance according to sex.

DISCUSSION

Canthal distances in Nigerians, a predominantly black population, are not readily available in the literature. The results of this study shows that medial and LCDs in CLAP patients was significantly higher than normal population, (P<001), which is in agreement with previous studies, (Aduss et al, 1971; Moss, 1965; Figalov et al., 1974). Medial and LCDs are higher in the unilateral cleft lip with MCD 40.54 mm and LCD 111.6 Mmm than all other types. The higher value may be due to the

preponderance of males in unilateral cleft lip which is 21 out of a total of 27 males. Aduss et al. (1971) showed that the increase in inter-orbital distance was small in his large sample size of orofacial cleft lip with or without cleft palate, but not with cleft palate or robin sequence only, which is in agreement with this study. The isolated cleft

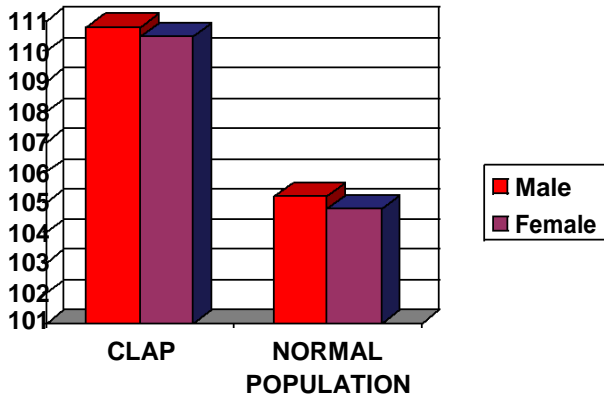


Figure 3. Mean lateral canthal distance according to sex.

palate intercanthal distances approximated to normal population's value.

The mechanism resulting in the association between orofacial clefts and an increased inter-orbital distance is not known, but Moss (1965) suggested that an unspecified defect in the Nasal capsule is related to both Orofacial clefting and increased inter-orbital distance.

The MCD and LCD in CLAP patients were higher than normal population which shows that most patients with un-repaired CLAP deformity has tendency to true ocular hypertelorism. Bony inter-orbital measurements from radiographs or carpal tunnel syndrome (CTs) are the most accurate and are important for surgical consideration (McFee et al., 1986). Although inner and outer Canthal measurements are less accurate than bony inter-orbital measurements, they are simple to use for standard clinical workshop (Feingold et al., 1974; Sivan et al., 1982).

Conclusion

There is significant difference in the medial and LCDs between CLAP patients and normal Nigerian population. The study suggests a tendency to true ocular hypertelorism in CLAP patients and not in isolated cleft palate which is relevant in orthodontics and reconstructive surgery.

REFERENCES

- Aduss H, Pruzansky S, Miller M (1971). Inter-orbital distance in cleft lip and palate. *Teratology*, 4: 171-82.
- Bojlen K, Bremus T (1938). Hypertelorism (Greig) *Acta. Path. Microbiol. Scand.*, 15: 217-258.
- Feingold M, Bossert WH (1974). Normal values for selected physical parameters: An aid to syndrome delineation. *Birth Defects*, 10(13): 1-15.
- Figalov P, Hajnis K, Smahel Z (1974). The inter-ocular distance in children with Clefts before the operation. *Acta. Chir. Plast*, 16: 65-77.
- Fledalius HC, Stubgaard M (1986). Changes in eye position during growth and adult life as based on exophthalmometry inter pupillary distance and orbital distance measurement. *Acta. Ophthalmol.*, (64): 481 – 486.
- Juberg RC, Sholte FG, Touchstone J (1975). Normal values for intercanthal distances of 5 - 11 year old American Blacks. *Pediatrics*, 55: 43– 6.
- Laestadius ND, JM Aese, DW Smith (1969). Normal inner canthal and outer orbital dimensions. *The Pediatrics*, 74; 465-468.
- Gerald BE, Silverman FN (1965). Normal and abnormal inter-orbital distances with special references Mongolism. *Am. J. Roentgen.*, 95: 154- 161.
- Greig DM (1924). Hypertelorism; A hitherto undifferentiated congenital cranio-facial deformity. *Edinburgh Med. J.*, 31: 560-593.
- McFee MF, Pruzansky S, Corrales MM, Valvassori GDD, Caper V (1986). Computed tomography in the evaluation of the orbit and the bony inter-orbital distance (B.I.O.D.). *Am J Neuroradiol.*, 7: 265-9.
- Moss ML (1965). Hypertelorism and cleft palate deformity. *Acta. Anat.*, 61: 547-57
- Murphy WK, Laskin DM (1990). Intercanthal and interpupillary distance in the Black population. *Oral Surg. Oral Med. Oral. Pathol.*, 69(6): 676 – 680.
- Osuobeni EP, al-Musa KA (1993). Gender differences in interpupillary distance among Arabs. *Optom. Vis. Sci.*, 70: 1027-1030.
- Ozturk F, Yavas G, Inan UU (2006). Normal periocular and anthropometric measurements in the Turkish population. *Ophthalmic Epidemiol.*, 13(2): 14-19.
- Saheeb BDO, Umweni AA, Obuekwe ON, Folaranmi N (2004). Normal values of medial and LCDs in 3 to 18 years old Nigerians. *West Afri. J. Med.*, 23(2):156–161.
- Singh JR, Banerjee S (1983). Normal values for interpupillary, inner canthal and outer canthal distances in an Indian population. *Hum. Hered.*, 33: 326– 328.
- Sivan Y, Merlob P, Russer SH (1982). Eye measurements in preterm and term newborn infants. *J. Craniofacial Genet. Dev. Biol.*, 2: 239-42.