

## Full Length Research Paper

# Hepatoprotective effect of *Phyllanthus niruri* aqueous extract in acetaminophen sub-acute exposure rabbits

Micah S. Makoshi<sup>1\*</sup>, Isaac M. Adanyeguh<sup>2</sup> and Loveth I. Nwatu I.<sup>3</sup>

<sup>1</sup>Drug Development Section, Biochemistry Division, National Veterinary Research Institute, Vom, Plateau State, Nigeria.

<sup>2</sup>Department of Theoretical and Applied Biology, College of Science, Kwame Nkrumah University of Science and Technology, Ghana.

<sup>3</sup>Department of Pharmacy, Faculty of Pharmaceutical Sciences, University of Nigeria, Nsukka, Enugu State, Nigeria.

Accepted 16 August, 2016

The hepatoprotective effect of the aqueous extract of *Phyllanthus niruri* was evaluated in an acetaminophen-induced hepatotoxicity study using 24 male rabbits of the New Zealand White breed. The rabbits were randomly divided into six groups of 4 rabbits each. Group I served as a negative control group and was given only distilled water. Group II received only acetaminophen at 300 mg/kg. Groups III, IV and V were all given 300 mg/kg of acetaminophen followed by varying concentrations of the extract of *P. niruri* at 100, 50 and 25 mg/kg body weight, respectively. Group VI was the positive control for *P. niruri* and was given 100 mg/kg of the extract. The treatment was given every other day for 28 days. The most significant healing or hepatoprotective effect of the extract of *P. niruri* was seen in the group administered the extract at 25 mg/kg which showed no significant change in the liver, both grossly and histologically. In most groups, the liver enzyme assay and serum albumins and globulins levels increased slightly, except the group administered 25 mg/kg extract of *P. niruri*. This study showed that *P. niruri* has hepatoprotective properties.

**Key words:** Acetaminophen, hepatotoxicity, *Phyllanthus niruri*, hepatoprotective, rabbits.

## INTRODUCTION

Acetaminophen, also known as paracetamol, is a widely used over the counter analgesic and antipyretic agent (Nelson et al., 2002). It is commonly used for the relief of fever, headache and other minor aches and pains. It is a major ingredient in numerous cold and flu remedies (Roberts et al., 1991). Although, it is generally safe for human use at recommended doses, acute overdoses are often seen when acetaminophen is consumed above 1000 mg per single dose and above 4000 mg per day for adults (Ohki et al., 1979), or when taken above 2000 mg per day if drinking alcohol (Ottani et al., 2006). Acetaminophen consumed at these conditions can cause

potentially fatal liver damage, and in rare cases, a normal dose can do the same damage in normal individuals. The risk is however heightened by alcohol consumption (Sies et al., 1997). Paracetamol toxicity is the foremost cause of acute liver failure in the Western world, and accounts for most drug overdoses in the United States, the United Kingdom, Australia and New Zealand (Högestätt et al., 2005).

Paracetamol is derived from coal tar, and is part of the class of drugs known as "aniline analgesics"; it is the only one of such drugs still in use today (Thummel et al., 1993). It is the active metabolite of phenacetin. It is not considered to be carcinogenic at therapeutic doses (Whiteman et al., 1996). The words acetaminophen and paracetamol both come from the chemical names for the compound: para-acetylamino-phenol and N-acetyl-para-aminophenol. In some contexts, it is simply abbreviated

\*Corresponding author. E-mail: [makoshi23@yahoo.com](mailto:makoshi23@yahoo.com). Tel: +2348061381275 or +2348056140655.

as APAP, for *N*-acetyl-para-aminophenol (James et al., 2001).

*Phyllanthus niruri* (family Euphorbiaceae) is a plant possessing several pharmacological properties (Thippeswamy et al., 2011). It is known to contain phytochemicals with antioxidant properties such as the flavonoids like niruriflavones and phenolic compounds like the triterpenoids. Faremi et al. (2008) demonstrated the antioxidant and hepatoprotective effect of the family against ethanol-induced stress in rats. *P. niruri* also contains compounds like phyllanthin, hypophyllanthin and ellagic acids whose antioxidant functional properties may include scavenging of reactive oxygen species, inhibition of generation of free radicals and chain-breaking activity (Thippeswamy et al., 2011).

The hot water leave extract of *P. niruri* is administered orally as a popular fever remedy in the Dominican Republic (Simpson et al., 2000) and is taken orally to increase appetite in the Virgin Islands and Puerto Rico (Sakaida et al., 1995; Schnellmann et al., 1999). In Tanzania, it is administered orally for treating gonorrhoea (Thomas et al., 2002). The hot water extract of the dried aerial parts is used as a diuretic, antipyretic and anti-malarial in Thailand (Weis et al., 1992). The cold water extract of the leaves and roots is taken orally for diabetes, and as a diuretic in the West Indies (Stockton and Paller, 1990). The entire plant is dried and grounded in buttermilk and administered orally to treat jaundice in Fiji. The milky juice of the plant is considered good for topical application on offensive sores, cuts and bruises; it is also mixed with castor oil and applied to the eye to treat eye diseases (Salas and Corcoran, 1997). In India, juice made from the fresh plant is taken orally for urogenital disorders (Tee et al., 1986). The fruit is used externally for tubercular ulcers, scabies and ringworm, while the hot water extract of the dried plant is administered orally for curing diabetes, malaria and asthma in Ayurvedic medicine (Halmes et al., 1996; Boess et al., 1998). According to the Ayurvedic system of medicine, preparations from the plant are used for the treatment of bronchitis, leprosy, anemia, urinary discharge, anuria, biliousness, asthma, hiccups and as a diuretic. According to the Unani system of medicine, the herb is a stomachic and good for sores and useful in chronic dysentery (Agharkar, 1991; Krishnamurty, 1993). The fresh root is believed to be an excellent remedy for jaundice. A poultice of the leaves with salt is used to treat scruddy, and when without salt, it is applied on bruises and wounds. The infusion of the root and leaves is a good tonic and diuretic when taken cold in repeated doses (Oudhia and Tiwari, 2001). In many parts of India especially in the deserts, it is commonly used for the treatment of snake bite, and a major component of many popular liver tonics. The roots mixed with *Commiphora mukul* are given to camels to cure indigestion (Singh et al., 1996). Because of the increased incidences of acetaminophen abuse leading to increasing incidences of

hepatotoxicity, this study was designed to evaluate the efficacy of *P. niruri* in ameliorating the hepatotoxic effects that may arise following repeated administration of acetaminophen in rabbits.

## MATERIALS AND METHODS

### Plant collection and identification

Fresh *P. niruri* plants were collected from Zaria, Kaduna State, Nigeria. The plant was identified according to the description of Dalziel (1937) and was further authenticated by a voucher specimen at the herbarium of Ahmadu Bello University, Zaria, Nigeria. The collected plant samples were washed under running tap water to remove sand particles. Other foreign particles that were collected alongside were sorted out. The samples were then dried in an oven at 40°C for 6 days. The dried plant samples were ground to fine powder using a mortar and pestle. An aqueous extract of the plant was prepared according to the method described by Sofowora (1993). The standard methods of Trease and Evans (1978) were used in the analysis of the phytochemical components of the plant.

### Phytochemical analysis of the plant

After the collection, identification and extraction of the plant, 0.5 g of the aqueous extract was used for the screening to determine the presence of phytochemicals like alkaloids, anthraquinones, cardiac glycosides, flavonoids, saponins, steroid/terpenes and tannins. The phytochemical screening was conducted according to the standard procedures described by Trease and Evans (1978) and Sofowora (1993). The procedures for the phytochemical screening are shown below, and results summarized and shown in Table 2

### Acquisition and preparation of acetaminophen

The acetaminophen used in this study was the Paracetamol D. C. Grade 90% which was donated by a reputable pharmaceutical company based in Jos, Nigeria. 5 g of acetaminophen was reconstituted in 100 ml distilled water to make a 5% solution. The preparation was made fresh whenever treatment was to be instituted. Other drugs, chemicals and reagents used in this study were of good standard and were obtained from reliable pharmaceutical shops.

### Experimental animals

Twenty-four (24) male grower rabbits belonging to the New Zealand White species were obtained from the small animal experimental unit of the National Veterinary Research Institute, Vom, Jos. The animals were stabilized for a week in the small animal experimental unit of the institute for seven days prior to the commencement of the experiment. The twenty-four rabbits were randomly selected and divided into six groups of four animals each. The animals were fed on pelletized feed produced by the animal feed production unit of the research institute (NVRRI feed-mill).

### Acute toxicity studies

Six rabbits weighing 1.0 to 1.75 kg were randomly selected for the acute toxicity studies to determine the mean lethal dose (LD<sub>50</sub>) of *P. niruri*. The six rabbits were randomly divided into three groups of

**Table 1.** The dosages of acetaminophen and aqueous extract of *P. niruri* administered to the groups of animals.

Group	Acetaminophen (e very other day) (mg/kg)	<i>P. niruri</i> (daily) (mg/kg)
I (Distilled water only)	-	-
II	300	-
III	300	100
IV	300	50
V	300	25
VI	-	100

**Table 2.** Phytochemical analysis of *P. niruri*.

Phytochemical	Occurrence
Alkaloid	-
Anthraquinone	-
Cardiac glycoside	++
Flavonoid	+
Saponin	++
Steroid / Terpene	+
Tannin	+

+ = Present; - = absent.

two rabbits each. The LD<sub>50</sub> was determined using the OECD guidelines. Each group was kept in a separate cage. The first group was given a single dose of 500 mg/kg of the aqueous extract of *P. niruri* and observed for 48 h. When no mortality was observed in the first group, the second group was administered 1000 mg/kg of the same extract and observed for another 48 h. Similarly, the third group was given a single dose of 2000 mg/kg of the extract when no mortality was observed in the second group, and also monitored for 48 h. The groups of animals were continuously observed for two weeks. During the acute toxicity studies, feed and water were provided *ad libitum*.

### Experimental design

The study was designed to evaluate the hepatoprotective effect of the crude aqueous extract of *P. niruri* at varying concentrations in rabbits, following a sub-acute exposure of the animals to acetaminophen (APAP). During the study, twenty-four male grower rabbits were divided into six groups of three rabbits each. Group I served as a negative control and was administered only distilled water orally. Group II was a positive control for acetaminophen and was administered only acetaminophen at a dose rate of 300 mg/kg. Groups III, IV and V were the experimental groups used to test the hepatoprotective effect of *P. niruri*. All were given 300 mg/kg acetaminophen, but were treated with 100, 50 and 25 mg/kg of the aqueous extract of *P. niruri*, respectively, after 30 min of the administration of acetaminophen. Group VI was the positive control group for the aqueous extract of *P. niruri*. This group received only the aqueous extract at 100 mg/kg (Table 1). Both the acetaminophen and the plant extract were administered by oral gavage. The treatments were done for 28 days during which the experimental animals were observed for obvious clinical signs of toxicity or side

effects of administered drug or extract. At the end of the experiment, each rabbit was bled via the ear vein, and blood samples collected to analyze serum liver function enzymes. The rabbits were then euthanized and the livers were collected for gross and histopathological examinations.

### Statistical analysis

The values obtained were expressed as mean  $\pm$  SEM. One-way analysis of variance (ANOVA) with Tukey's multiple range comparison post-hoc tests were performed on the data using the GraphPad Prism software to compare the level of significance between the test groups and controls. Values of  $P < 0.05$  were considered significant.

## RESULTS

### Phytochemical analysis

The phytochemical analysis carried out revealed the presence of saponins, tannins, cardiac glycosides, steroids and flavonoids in the leaves of *P. niruri* as shown in Table 2.

### Acute toxicity testing

During the acute toxicity study, only the clinical signs of mild toxicity were seen. None of the animals died during the two weeks of the study. Thus, the mean lethal dose (LD<sub>50</sub>) of the aqueous extract of *P. niruri* was found to be >2000 mg/kg as shown on Table 3.

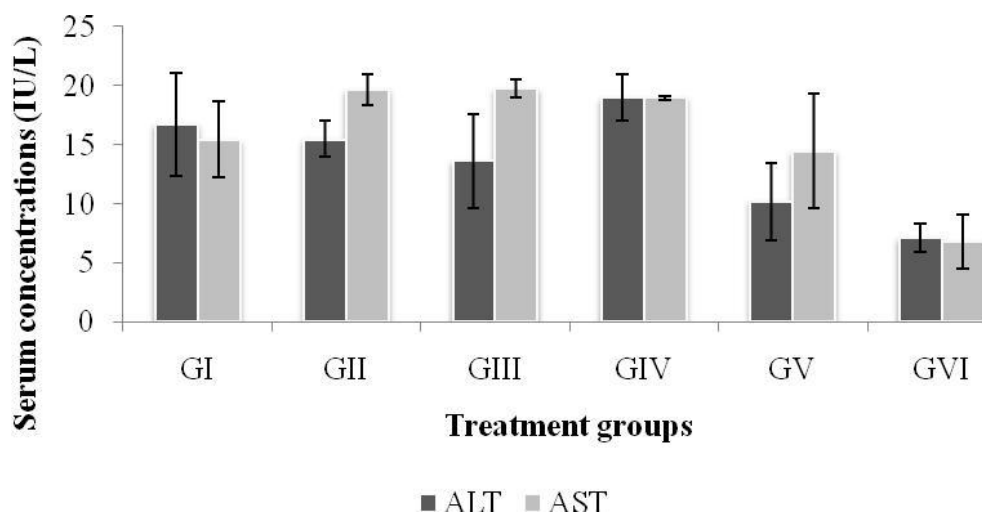
### Sub-chronic toxicity studies

#### Clinical signs

No major clinical signs were observed in the experimental animals during the course of the study. However, inactivity following the administration of acetaminophen or *P. niruri* was observed in all groups with the exception of the negative control group which took only distilled

**Table 3.** Result of the acute toxicity studies conducted on the aqueous extract of *P. niruri*.

<i>P. niruri</i> single oral dose (mg/kg)	Clinical signs	Mortality
500	Animals became inactive following <i>P. niruri</i> extract oral administration and remained dull even when touched. They resumed normal activity after about 30 min of inactivity.	0/2
1000	Animals alternated between staying stationary and slight movements for the first 30 min after dosing. They resumed normal activity, feeding and moving around about 1 h post treatment.	0/2
2000	Animals remained inactive for the first 30 min following <i>P. niruri</i> administration. They resumed normal activity after about an hour after the extracts administration.	0/2

**Figure 1.** Mean values of serum alanine amino transferase and aspartate amino transferase.

water. Activity in animals returned to normal after about 30 min of receiving test substance.

#### **Alanine amino transferase (ALT) and aspartate amino transferase (AST)**

The mean values of the serum biomarkers of hepatotoxicity were assayed and the result showed an increase in the values of both ALT and AST within the treatment groups. These values were observed to be higher in Group II and lowest in Group VI which took only the extract of *P. niruri*. When compared within the treatment groups, the values were lower in Group V which received 25 mg/kg extract of *P. niruri*. The difference was however not significantly different when compared with the positive control group that took only *P. niruri* ( $P < 0.05$ ) (Figure 1).

#### **Total protein and albumin**

Serum total protein concentration was highest in the acetaminophen positive control group (Group II); and lowest in Group VI. The values of serum albumin concentration were also high in Groups II and V and lowest in Group VI (Figure 2). The differences in the values of albumin were however not statistically significant when compared between all the groups ( $p > 0.05$ ) (Figure 2).

#### **Serum total bilirubin concentration**

There was a general increase in the total bilirubin in all the treatment groups except Group I. The values of the *P. niruri* positive control group (Group VI) were also lower than those of the treatment groups. There was no

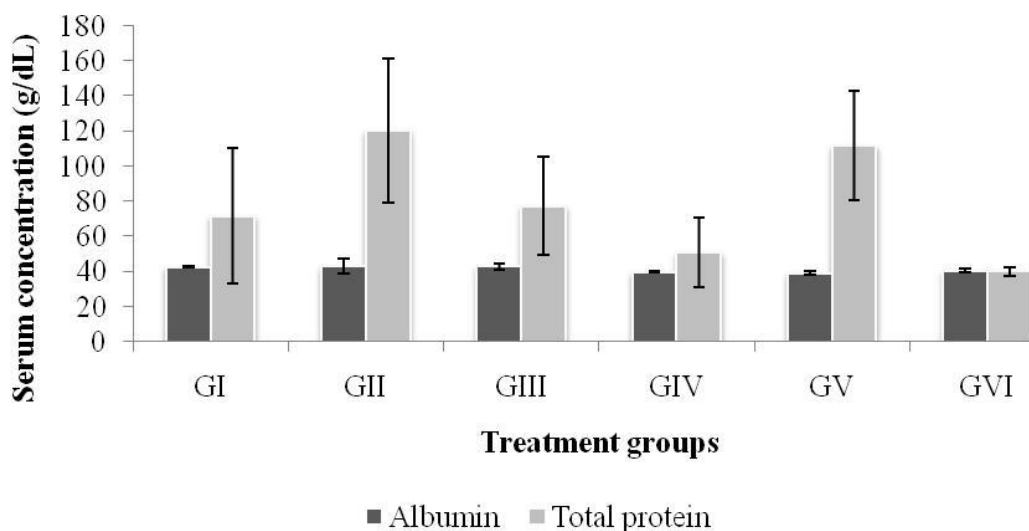


Figure 2. Mean values of serum albumin and total protein concentration.

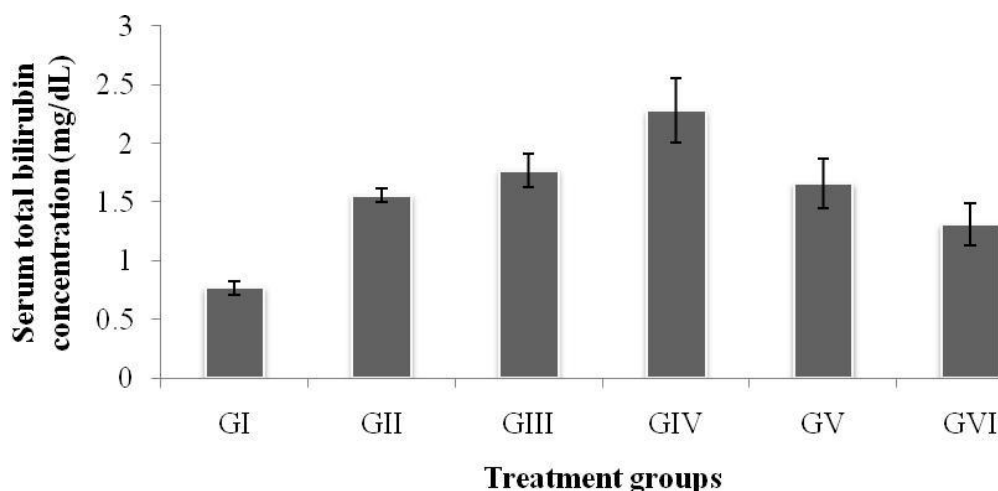


Figure 3. Mean values of serum total bilirubin concentration.

significant statistical difference between the values of all the treatment groups ( $p > 0.05$ ) (Figure 3).

### Gross pathology

When the liver samples of the treated rabbit were harvested and examined grossly, they were found to be slightly enlarged but with severe congestion. When they were incised, blood oozed out of the cut surfaces.

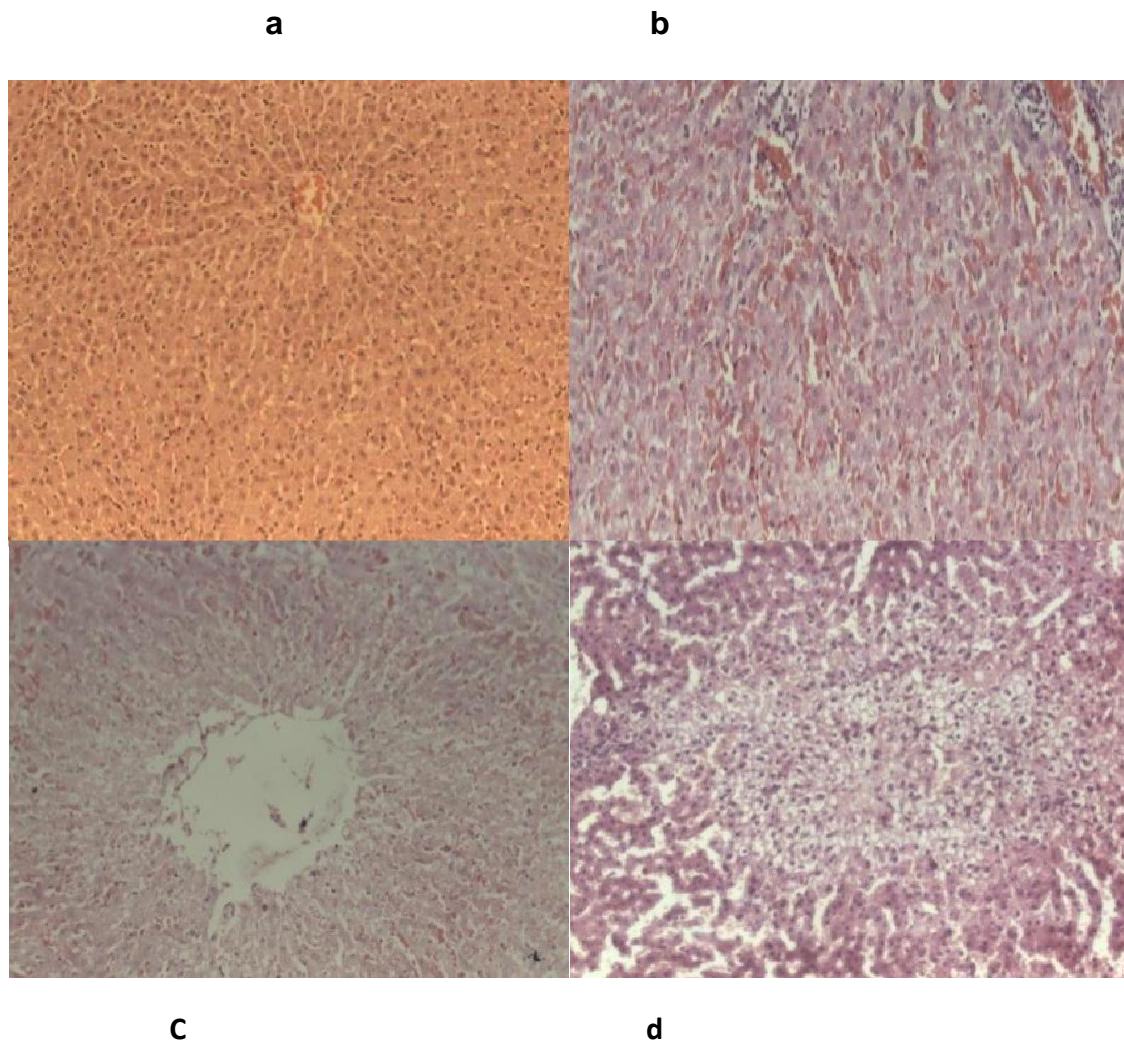
### Histopathology

The severe congestions of the livers seen grossly appeared histologically as generalized congestion with

hemorrhages. In addition, the histopathological examination also revealed the presence of centrilobular and coagulative necrosis in the livers of the animals administered acetaminophen (Figure 4c and d). The histological picture of the livers of the animals in Group V also showed congestion but with less hepatocyte damage (Figure 4b). The liver samples from the water control (Group I) and the *Phyllanthus* control (Group VI) showed normal liver architecture with no cellular damage (Figure 4a).

### DISCUSSION

In this study, the mean lethal dose ( $LD_{50}$ ) of the aqueous extract of *P. niruri* was found to be greater than 2000



**Figure 4.** Histopathology of liver after H&E staining (magnification 10x). (A) Normal liver architecture; (B) Congestion with less damage to hepatocytes (Group V I); (C, D) Centrilobular and coagulative necrosis of liver, respectively (Group II).

mg/kg. The clinical signs observed in the rabbits during the study (Table 3) were thought to be physiological reactions to the newly introduced plant extract. The study showed that the aqueous extract of *P. niruri* is relatively safe in rabbits even at the concentration of 2000 mg/kg since no animal died at the end of the two weeks of the study.

The severe congestion and hepatomegaly that were seen at the gross pathological examination of the livers are indications that all the groups that were administered acetaminophen must have had liver injuries caused by the administered drug. These injuries were thought to have affected the blood vessels supplying the liver and the parenchyma, resulting in hemorrhages and congestion. This was confirmed at the histopathological examination which is used to measure and evaluate

normal cellular biologic processes, pathogenic processes or biological responses to a therapeutic intervention. The histopathological examination showed the degeneration of the hepatocytes and liver parenchyma in the form of centrilobular and coagulative necrosis. These signs were found mostly in the livers of the animals in Groups II, III, and IV. These findings show that the administered acetaminophen, even at a concentration of 300 mg/kg, was capable of inducing hepatic injuries to the experimental animals. These findings were also in concordance with the findings of (Kuvandik et al., 2008, Chen et al., 2009 and Wilhelm et al., 2009). Although, the animals in Groups II, III, and IV received relatively higher doses of the extract of *P. niruri*, the hepatoprotective effect was seen more in Group V that took a lower concentration.

The increased levels of the serum liver enzymes ALT



and AST (with AST having a higher value) (Figure 1), serum albumin and total protein (Figure 2) and serum bilirubin (Figure 3) which were observed in this study also point to the fact that the administered 300 mg/kg acetaminophen produced a hepatotoxic effect in the livers of the rabbits. These enzymes are considered to be the most relevant biomarkers of liver injuries or toxicities, and thus higher levels of these enzymes within the systemic circulation points to a probable liver injury or toxicity. The findings in this study were also in agreement with previous reports made by several authors (Mazer and Perrone, 2008; Zira et al., 2009; Ghanem et al., 2009), who demonstrated that the elevations in liver markers in rats, mice and rabbits are due to liver injuries.

Generally, damage or injury to the liver impairs protein synthesis and increases serum protein concentration due to leakages from the hepatocytes (Rajesh et al., 2009). The administration of acetaminophen at (300 mg/kg) in this study produced a hepatotoxic effect that resulted in the slight leakages of these proteins from the hepatocytes into the systemic circulation. This is why these proteins were detected in the serum of the treated animals. It should also be noted that all the groups that were given acetaminophen (Groups II, III, IV and V) produced high values of AST. Although, the values of the serum albumins were low, the values of the total proteins were high in these groups (Figure 2). This shows that the liver and probably other organs were affected by the 300 mg/kg acetaminophen administered to the animals. The mean values of the serum total bilirubin concentration were found to be lowest in the negative control group, but there was no statistically significant difference when these values were compared between the treatment groups ( $P > 0.05$ ). It should also be noted that besides Group II which received only acetaminophen, Groups III, IV and V were treated with the extract of *P. niruri* at 100, 50 and 25 mg/Kg body weight, respectively. However, the values of AST and ALT were seen to be lower in Group V which took 25 mg/kg of the extract. This result shows that the hepatoprotective or healing effect of the administered *P. niruri* was best at 25 mg/kg. The result of the liver function enzyme assay can be seen to be in concordance with the result of the gross and histopathological examinations, showing that the best hepatoprotective effect of the aqueous extract of *P. niruri* was observed in the group of rabbits administered 25 mg/kg extract (Group V). This is also in concordance with the findings of several authors (Lee et al., 2006; Frameset al., 2008; Manjrekaret al., 2008; Adeneye and Benebo, 2008).

The hepatoprotective or healing effect of the crude extract of *P. niruri* was thought to be due to the normalization of impaired membrane function activity of the liver (Gupta and Misra, 2006). This healing or normalization process might also be associated with the high tendency of the liver tissue to rejuvenate after it has been injured or damaged. This is also in concordance with (Bhattacharjee, 2006), who stated that the protein fraction of *Phyllanthus niruri* plays a protective role against aceta-

minophen induced hepatic disorder via its antioxidant properties.

## Conclusion

The administered acetaminophen at 300 mg/kg induced a hepatotoxic effect in the rabbits which was demonstrated by the increases in some liver biomarkers. It also caused congestion, hemorrhage, coagulative, and centrilobular necrosis in the livers of the treated animals. Treatment with the aqueous extract of *P. niruri* ameliorated these effects by lowering the levels of these biomarkers especially in the group of animals treated with 25 mg/kg of the extract. This was also confirmed by the histopathological examination of livers of this groups which showed less congestion at gross examination and had less hepatocyte damage when observed histologically.

In this study, the aqueous extract of *P. niruri* proved to be capable of providing hepatoprotection against acetaminophen induced hepatotoxicity; it is therefore, possible that it can as well offer hepatoprotection against the hepatotoxicities caused by other agents.

## RECOMMENDATION

It is recommended that further work should be done to quantitatively determine the active principles responsible for the hepatoprotective effect of *P. niruri*. In addition, molecular studies should be carried out to further elucidate the mechanism of action of the active compounds of this plant.

## ACKNOWLEDGEMENTS

The authors wish to acknowledge the management of the National Veterinary Research Institute (NVRI) and the Africa Education Initiative, USA for facilitating this study.

## REFERENCES

- Adeneye AA, Benebo A (2008). Protective effect of the aqueous leaf and seed extract of *Phyllanthus amarus* on gentamicin and acetaminophen-induced nephrotoxic rats. *J. Ethnopharmacol.* 118(2):318-323.
- Agharkar SP (1991). Medicinal plants of Bombay presidency. Scientific A Publ, Jodhpur, India. p. 220-223
- Bhattacharjee, R, Sil, PC (2006). The protein fraction of *Phyllanthus niruri* plays a protective role against acetaminophen induced hepatic disorder via its antioxidant properties. *Phytother. Res.* 20:595-601.
- Boess F, Bopst M, Althaus R, Polsky S, Cohen SD, Eugster HP, Boelsterli UA (1998). Acetaminophen hepatotoxicity in tumor necrosis factor/lymphotoxin-alpha gene knockout mice. *Hepatology* 27:1021-1029.
- Chen YH, Lin FY, Liu PL, Huang YT, Chiu JH, Chang YC, Man KM, Hong CY, Ho YY, Lai MT (2009). Antioxidative and hepatoprotective effects of magnolol on acetaminophen-induced liver damage in rats. *Arch. Pharmacol. Res.* 32(2):221-228.
- Dalziel M (1937). The useful plants of West Tropical Africa. Crown Agents, London. p.612.

- Faremi, TY, Suru SM, Fafunso MA, Obioha UE (2008). Hepatoprotective potentials of *Phyllanthusamarus* against ethanol-induced oxidative stress in rats. *Food Chem. Toxicol.* 46(8):2658-2664.
- Ghanem CI, Ruiz ML, Villanueva SS, Luquita M, Llesuy S, Catania VA, Bengochea LA, Mottino AD (2009). Effect of repeated administration to rats on enterohepatic recirculation of a subsequent toxic dose. *Biochem. Pharmacol.* 77(10):1621-1628.
- Halmes NC, Hinson JA, Martin BM, Pumford NR (1996). Glutamate dehydrogenase covalently binds to a reactive metabolite of acetaminophen. *Chem. Res. Toxicol.* 9:541-546.
- Högstätt ED, Jönsson BA, Ermund A, Andersson PA, Björk H, Alexander JP, Cravatt BF, Basbaum AI, Zygmunt DM (2005). Conversion of acetaminophen to the bioactive N-acylphenolamine AM404 via fatty acid amide hydrolase-dependent arachidonic acid conjugation in the nervous system". *J. Biol. Chem.* 280(36):31405-31412.
- James LP, Farrar HC, Sullivan JE, Givens TG, Kearns GL, Wasserman GS, Walson PD, Hinson JA, Pumford NR (2001). Pediatric Pharmacology Research Unit Network. NICHD Measurement of acetaminophen-protein adducts in children and adolescents with acetaminophen overdoses. *J Clin. Pharmacol.* 41:846-851.
- Krishnamurty T (1993). *Minor forest products of India*. Oxford and IBH Publ. Co. Pvt. Ltd. New Delhi.
- Kuvandik G, Duru M, Nacar A, Yonden Z, Helvacı R, Koc A, Kozlu T, Kaya H, Sogut S (2008). Effects of erdosteine on acetaminophen-induced hepatotoxicity in rats. *Toxicol. Pathol.* 36(5):714-719.
- Lee CY, Peng WH, Cheng HY, Chen FN, Lai MT, Chiu TH (2006). Hepatoprotective effect of *Phyllanthus* in Taiwan on acute liver damage induced by carbon tetrachloride. *Am. J. Chinese Med.* 34(3):471-482.
- Manjrekar AP, Jisha V, Bag PP, Adhikary B, Pai MM, Hegde A, Nandini M (2008). Effect of *Phyllanthus niruri* Linn. Treatment on liver, kidney and testes in CCl<sub>4</sub>-induced hepatotoxic rats. *Indian J. Exp. Biol.* 46(7):514-520.
- Mazer M, Perrone J (2008). Acetaminophen-induced nephrotoxicity: pathophysiology, clinical manifestations, and management. *J. Med. Toxicol.* 4(1):1-6.
- Nelson SG, Wan Z, Stan MA (2002). S(N)2 ring opening of beta-lactones: an alternative to catalytic asymmetric conjugate additions. *J. Org. Chem.* 67:4680-4683.
- Ohki S, Ogino N, Yamamoto S, Hayaishi O (1979). Prostaglandin hydroperoxidase, an integral part of prostaglandin endoperoxidase synthetase from bovine vesicular gland microsomes. *J. Biol. Chem.* 254(3):829-836.
- Ottani A, Leone S, Sandrini M, Ferrari A, Bertolini A (2006). The analgesic activity of paracetamol is prevented by the blockade of cannabinoid CB1 receptors. *Eur. J. Pharmacol.* 531(1-3):280-281.
- Oudhia P, Tiwari UK (2001). *Aushadhi Paudho Ki Kheti: Kab aur Kaise*. Srishti Herbal Academy and Research Institute (SHARI), Raipur, India.
- Rajesh SV, Rajkapoor B, Kumar RS, Raju K (2009). Effect of *Clausenadentata* (Willd.) M. Roem. against paracetamol induced hepatotoxicity in rats. *Pak. J. Pharm. Sci.* 22(1):90-93.
- Roberts DW, Bucci TJ, Benson RW, Warbritton AR, McRae TA, Pumford NR, Hinson JA (1991). Immunohistochemical localization and quantification of the 3-(cystein-S-yl)-acetaminophen protein adduct in acetaminophen hepatotoxicity. *Am J Pathol.* 138:359-371.
- Sakaida I, Kayano K, Wasaki S, Nagatomi A, Matsumura Y, Okita K (1995). Protection against acetaminophen-induced liver injury in vivo by an iron chelator, deferoxamine. *Scand. J. Gastroenterol.* 30:61-67.
- Salas V M, Corcoran, G B (1997). Calcium-dependent DNA damage and adenosine 3',5'-cyclic monophosphate-independent glycogen phosphorylase activation in an in vitro model of acetaminophen-induced liver injury. *Hepatology* 25:1432-1438.
- Schnellmann JG, Pumford NR, Kusewitt DF, Bucci TJ, Hinson JA (1999). Deferoxamine delays the development of the hepatotoxicity of acetaminophen in mice. *Toxicol. Lett.* 106:79-88.
- Sies H, Sharov VS, Klotz LO, Briviba K (1997). Glutathione peroxidase protects against peroxynitrite-mediated oxidations. A new function for selenoproteins as peroxynitrite reductase. *J. Biol. Chem.* 272:27812-27817.
- Simpson KJ, Lukacs NW, McGregor AH, Harrison DJ, Strieter RM, Kunkel SL (2000). Inhibition of tumour necrosis factor alpha does not prevent experimental paracetamol-induced hepatic necrosis. *J. Pathol.* 190:489-494.
- Singh U, Wadhvani AM, Johri BM (1996). *Dictionary of economic plants in India*. Indian Council of Agricultural Research, New Delhi.
- Sofowora A (1993). *Medicinal Plants and Traditional Medicine in Africa*, University of Ife Press, Nigeria. pp.1-23.
- Stockton DL, Paller, A S (1990). Drug administration to the pregnant or lactating woman: a reference guide for dermatologists. *J. Am. Acad. Dermatol.* 23(1): 87-103.
- Tee LB, Boobis AR, Huggett AC, Davies DS (1986). Reversal of acetaminophen toxicity in isolated hamster hepatocytes by dithiothreitol. *Toxicol. Appl. Pharmacol.* 83:294-314.
- Thippeswamy AHM, Akshay Shirodkar, BC Koti, A. Jaffar Sadiq, Praveen DM, Viswanatha Swamy AHM, Mahesh Patil (2011). Protective role of *Phyllanthus niruri* extract in doxorubicin-induced myocardial toxicity in rats. *Indian J. Pharmacol.* 43(1):31-35.
- Thomas DD, Espey MG, Vitek MP, Miranda KM, Wink DA (2002). Protein nitration is mediated by heme and free metals through Fenton-type chemistry: an alternative to the NO/O<sub>2</sub><sup>-</sup> reaction. *Proc. Natl. Acad. Sci. USA.* 99:12691-12696.
- Thummel KE, Lee CA, Kunze KL, Nelson SD, Slattery JT (1993). Oxidation of acetaminophen to N-acetyl-p-aminobenzoquinone imine by human CYP3A4. *Biochem. Pharmacol.* 45:1563-1569.
- Trease GE, Evans WC (1978). *Pharmacology*. 11th Edition, Bailliere Tindall, Ltd, London pp.60-75.
- Weis M, Kass GE, Orrenius S, Moldeus P (1992). N-Acetyl-p-benzoquinone imine induces Ca<sup>2+</sup> release from mitochondria by stimulating pyridine nucleotide hydrolysis. *J. Biol. Chem.* 267:804-809.
- Whiteman M, Kaur H, Halliwell B (1996). Protection against peroxynitrite dependent tyrosine nitration and alpha 1-antitrypsinase inactivation by some anti-inflammatory drugs and by the antibiotic tetracycline. *Ann. Rheum. Dis.* 55:383-387.
- Wilhelm EA, Jesse CR, Leite MR, Nogueira CW (2009). Studies on preventive effects of diphenyldiselenide on acetaminophen-induced hepatotoxicity in rats. *Pathophysiology* 16(1):31-37.
- Zira A, Mikros E, Giannoiti K, Galanopoulou P, Papalois A, Liapi C, Theocharis S (2009). Acute liver acetaminophen toxicity in rabbits and the use of antidotes: a metabonomic approach in serum. *J. Appl. Toxicol.* 29(5):395-402.